

Challenges in the treatment of laryngeal cyst in a baby less than 2 months old: a clinical case report

ABSTRACT

Laryngeal cysts are rare benign lesions, mostly asymptomatic and with a predominant etiology in adults. In children, the failure to diagnose laryngeal cysts is associated with a mortality rate of up to 40% due to the potential for airway obstruction. This article reports the case of an infant who presented with upper airway obstruction and acute respiratory failure. Immediate direct laryngoscopy was performed by the otolaryngology team in the operating room, revealing the presence of a cystic tumor in the vallecula that pushed the epiglottis, leading to almost complete obstruction of the glottic lumen. Microsurgery of the larynx was performed with total excision of the tumor, resolving the laryngeal obstructive condition. Although laryngeal cysts are rare, early diagnosis allows for definitive treatment. This can improve respiratory insufficiency, avoiding prolonged orotracheal intubation, the progression of which can lead to cardiac and respiratory arrest and death.

Keywords: Laryngeal cyst, Emergency surgery, Otolaryngology, Pediatric surgery

1. INTRODUCTION

The larynx is part of the structures that form the floor of the anterior cervical region, along with the pharynx and the thyroid gland, and it constitutes the respiratory layer of the neck viscera, as well as the trachea [1,2]. Although primarily known for its role as a vocal mechanism for voice production, its most important function is airway protection, especially during swallowing when it serves as a "sphincter" or "valve" of the lower respiratory system, thus maintaining airway patency [3,4].

Laryngeal cysts are rare benign lesions, and when they cause upper airway obstruction, they can lead to Acute Respiratory Insufficiency and an even more dramatic clinical condition, such as Cardiopulmonary Arrest due to hypoxemia and death [5,6]. Laryngeal cysts are classified as saccular or ductal. The main difference between saccular and ductal laryngeal cysts lies in their origin (congenital for saccular and acquired for ductal), location (usually superficial for saccular and deeper for ductal), and morphological characteristics (small sacs for saccular and cysts along the ducts for ductal) [7,8,9]. Saccular cysts are larger and are reported to be caused by the cystic distension of the laryngeal sacculae, with a lower incidence, representing 25% of cases. In another group are ductal cysts that develop due to distension of obstructed glandular ducts, often being asymptomatic [6].

Laryngeal cysts in children are relatively rare and rank between the fourth and fifth position among congenital malformations [10]. This condition is considered a very rare cause of infantile airway

obstruction, with a recorded incidence of between 1.5 and 1.8 cases per 100,000 newborns [11,12,13]. The lack of diagnosis of laryngeal cysts in these cases is associated with a mortality rate of up to 40% due to the possibility of airway obstruction [14,15,16]. Lateral neck radiography assists in visualizing most cysts, but it is not used as the primary tool since computed tomography and magnetic resonance imaging are capable of providing better details regarding the size and precise boundaries of the lesions. Fiberoptic laryngoscopy can be used as a diagnostic tool, and direct laryngoscopy allows for visualization, confirmation, and treatment [4,6]. Although laryngeal cysts have a rare incidence, early diagnosis enables definitive treatment. This can improve respiratory insufficiency, avoiding prolonged orotracheal intubation, the progression of which can lead to cardiopulmonary arrest and death. Therefore, it is important to initiate an otolaryngologic evaluation as soon as laryngeal stridor is detected, with a detailed medical history, as well as physical and complementary examinations for diagnostic clarification and assistance in the surgical excision of the lesion.

Cysts are difficult to diagnose because they are found in patients with non-specific symptoms. Congenital laryngeal cysts are one of the causes of stridor in newborn or early infancy, which may be accompanied by difficulty breathing, hoarseness, weak crying, feeding difficulties, and cyanosis [12,15,17]. The most common sites where cysts occur are the vocal folds, epiglottis, and vallecula [14]. The reported infant had a cyst located in the vallecula region, obstructing almost entirely the glottic lumen. A better prognosis occurred because it was promptly addressed, and through orotracheal intubation, a definitive airway was established, resulting in the reversal of respiratory insufficiency.

In this case report, we present the clinical management of a 47-day-old patient whose laryngeal cyst severely compromised respiratory function, demanding an urgent intervention.

2. CASE REPORT

The infant, aged 47 days, was presented to the emergency department of their place of residence with a sudden onset of dyspnea, accompanied by signs indicative of hypoxemia. The attending and primary care physicians undertook orotracheal intubation using a 3.5 tube due to the onset of acute respiratory insufficiency. This procedure encountered difficulties, with notable bleeding attributable to upper airway obstruction. Subsequently, the patient was transferred to the paediatric intensive care unit (ICU) at the referral centre, Hospital São José do Avaí, where they underwent close monitoring and stabilization. An evaluation by the otolaryngology team was urgently requested.

For the otolaryngological evaluation, the patient was placed under sedation and continued to be intubated, while maintaining haemodynamic stability. The patient remained well-coupled to mechanical ventilation, exhibited stable oxygen saturation, and displayed no discernible signs of respiratory distress. Upon a thorough physical examination, the otolaryngology team reported patent nasal passages, unremarkable oroscopy findings, and normal otoscopy results.

After the initial evaluation, direct laryngoscopy was promptly conducted by the otolaryngology team within the operating theatre. This procedure revealed the presence of a cystic tumour located within the vallecula, exerting pressure on the epiglottis, thereby causing near-complete occlusion of the glottic lumen (see Figure 1A). Consequently, a microsurgical procedure targeting the larynx ensued, culminating in the complete excision of the tumour. This intervention successfully alleviated the laryngeal obstructive condition (refer to Figures 1B and 1C).

On the same day as the surgical procedure, the patient was extubated and received supplemental oxygen via catheter. Continuous monitoring was performed by the paediatric ICU team. In light of clinical improvement and the absence of complications, the patient was transferred to a standard ward three days post-surgery, where they continued treatment for bronchoaspirative pneumonia, resulting from significant bleeding during the intubation process. Subsequently, the patient was

discharged from the hospital on the fifteenth day following admission, having achieved complete clinical recovery. The patient was then referred for outpatient follow-up care.

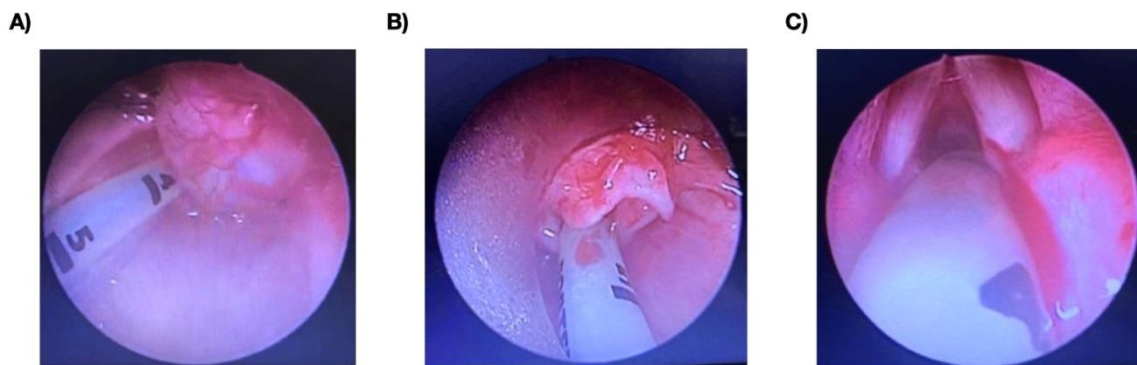


Fig. 1. A) Presence of a cyst in the vallecula region. B) Visualization of the epiglottis after cyst excision. C) Visualization of the glottic region after cyst removal, with no alterations.

3. DISCUSSION

Laryngeal cyst represents a unique clinical challenge, with a combination of a thorough medical history, radiological techniques, as well as clinical and endoscopic examinations providing essential comprehensive information for the confirmation of the diagnosis. Surgical interventions for the treatment of paediatric laryngeal sacular cysts present significant challenges due to the reduced dimensions of the airways in children and their proximity to crucial anatomical structures such as the recurrent laryngeal nerve [18,19]. Larger cysts place patients at greater risk, mainly due to the increased difficulty in completely removing the cystic tissue without compromising adjacent structures. The present case illustrates a large cyst causing nearly complete glottic lumen obstruction, resulting in hypoxia and necessitating urgent intervention.

Various treatment approaches for laryngeal cysts have been proposed, including traditional endoscopic excision, "deroofing" or "marsupialization" (a technique where the upper part of the cyst, known as the "roof," is removed by extended excision), needle aspiration, laser-assisted extended excision, supraglottoplasty, bleomycin injection, and external surgical approaches [9,12,13,20]. In all cases, the objective is complete cyst removal to prevent recurrence [9,12,13,20,21,22]. There are few available case reports in the current scientific literature, despite a variety of surgical techniques for laryngeal cyst treatment [23], and the choice of technique should take into account the patient's physiological circumstances and the clinical team's conditions and experience. Needle aspiration was promptly ruled out due to its high recurrence rate, as noted in the current scientific literature [9,23]. Surgical excision of the laryngeal cyst by direct laryngoscopy, considered the conventional treatment, was evaluated by the medical team as the most suitable in the presented case, mainly due to signs of hypoxemia that required a more urgent and effective intervention, considering the hospital

infrastructure, patient's condition, cyst location, and the best technique among viable treatment alternatives. This technique is considered by Chu et al. [9] and Chen et al. [24] to have the lowest chance of cyst recurrence. Removal by direct laryngoscopy is the most frequently used surgical treatment modality with successful outcomes in patients in the early years of life [13,20,23,24,25,26].

Singh et al. [23] report that there may be difficulty with intubation due to laryngeal lumen obliteration by the cyst. We observed this difficulty in the reported case, and the intubation procedure to restore oxygenation levels resulted in significant bleeding, leading to bronchoaspirative pneumonia. This complication is undesirable, but in the balance of more urgent needs, it is a necessary risk for the patient's physiological stabilization and control of respiratory distress before surgical intervention. The possibility of this type of complication should be expected, and immediate treatment of post-intubation injuries is of vital importance to prevent adverse health consequences for the patient [12,27,28]. Hurtado et al. [27] and Zhang et al. [28] propose that otolaryngologists and anaesthesiologists work together in intubation planning to reduce the possibility of patient injuries before such interventions, although such coordination is not always possible in emergency procedures, as in the presented clinical case. Prolonged endotracheal intubation can lead to new laryngeal cysts and should be avoided in the post-surgical period [20,29]. In the case presented here, the patient was extubated on the same day as the surgical procedure, and oxygen supplementation was provided via a catheter with monitoring in the paediatric intensive care unit to control oxygenation levels. The treatment of bronchoaspirative pneumonia followed conservative procedures, allowing for hospital discharge on the fifteenth day after admission. Clinical stabilization with significant improvement after this period enabled outpatient follow-up, with no further issues recorded.

4. CONCLUSION

While considered rare, congenital laryngeal cysts can compromise the respiratory tract in infants during the early months of life, and the absence of diagnosis and treatment is potentially fatal. Laryngoscopy should be included as part of the assessment when dealing with a child presenting with stridor. A prompt diagnosis, if achieved, can lead to early minimally invasive surgical procedures, thereby avoiding potentially life-threatening airway obstruction. Challenges in treating this condition include the limited dimensions of the airways in children and their proximity to important anatomical structures, demanding increased care from the otolaryngologist surgeon. Additionally, there is the difficulty of intubation due to laryngeal obstruction by the cyst, which can result in injuries during the intubation process.

CONSENT

The parents of the infant accepted to participate in this clinical study, and provided their informed consent knowingly and voluntarily. They were carefully informed about the study's details, including the medical procedures involved, potential risks and benefits, as well as the non-obligatory nature of their participation. Informed consent from the parents was obtained in accordance with the ethical principles outlined in the Helsinki Declaration, ensuring that their decisions and anonymity are respected, and that the well-being of the child was always prioritized. Written consent has been collected and preserved by the authors.

ETHICAL APPROVAL

As per international standard or university standard guideline ethical approval has been collected and preserved by the authors.

COMPETING INTERESTS

Authors have declared that no competing interests exist.

UNDER PEER REVIEW

REFERENCES

1. Thompson LDR, Bishop JA, editors. Head and neck pathology. Third edition. Philadelphia, PA: Elsevier; 2019.
2. McCullagh KL, Shah RN, Huang BY. Anatomy of the Larynx and Cervical Trachea. *Neuroimaging Clin N Am*. 2022 Nov;32(4):809–29.
3. Holzki J, Brown KA, Carroll RG, Coté CJ. The anatomy of the pediatric airway: Has our knowledge changed in 120 years? A review of historic and recent investigations of the anatomy of the pediatric larynx. Thomas M, editor. *Pediatric Anesthesia*. 2018 Jan;28(1):13–22.
4. Gray ST, Limb PK, Rosen CA, Park CJ, Richter SS. *Bailey's head and neck surgery: otolaryngology*. Sixth edition. Philadelphia: Wolters Kluwer Health /Lippincott Williams & Wilkins; 2023. 2.
5. Desanto LW, Devine KD, Weiland LH. Cysts of the larynx — classification. *The Laryngoscope*. 1970 Jan;80(1):145–76.
6. Tapasak B, Nguyen DK, Cervantes SS. Infected Thyroglossal Duct Cyst in a Neonate: A Report of a Rare Case. *Am J Case Rep [Internet]*. 2022 May 3 [cited 2023 Nov 16];23. Available from: <https://www.amjcaserep.com/abstract/index/idArt/936659>
7. Umehara T, Hakamada K, Suzuki K, Arai H, Yamaguchi Y, Kita J, et al. A case of congenital tongue base cyst in an infant with laryngomalacia. *Otolaryngology Case Reports*. 2017 Mar;2:1–3.
8. Ünsaler S, Gökler O, Altuntaş O, Meriç Hafiz A, Ünal ÖF. Subglottic cysts in preterm infants: superficially located cysts versus deeply buried cysts in the mucosa. *Eur Arch Otorhinolaryngol*. 2022 Mar;279(3):1391–6.
9. Chu S, A F, R F, Abu Bakar S. Congenital Laryngeal Cyst as a Rare Cause of Stridor in Infants: Two Case Reports. *Cureus [Internet]*. 2023 Jan 17 [cited 2023 Sep 18]; Available from: <https://www.cureus.com/articles/133608-congenital-laryngeal-cyst-as-a-rare-cause-of-stridor-in-infants-two-case-reports>
10. Kuranova LB, SoldatskiyYuL, Pavlov PV, Zakharova ML, Kovalets ES. Laryngeal cysts in children. *Vestn otorinolaringol*. 2021;86(6):57.
11. Rodríguez H, Zanetta A, Cuestas G. Quiste sacular congénito de laringe: una causa rara de estridor en neonatos y lactantes. *Acta Otorrinolaringológica Española*. 2013 Jan;64(1):50–4.
12. Rosas A, McCrary HC, Meier JD, Muntz HR, Park AH. Proposal for the surgical management of children with laryngeal saccular Cysts: A case series. *International Journal of Pediatric Otorhinolaryngology*. 2019 Nov;126:109604.
13. Rao S, Zameer MM, C V, D'Cruz A. Laryngeal Cyst in Children : A Retrospective Analysis. *Indian J Otolaryngol Head Neck Surg*. 2023 Sep;75(3):1352–5.

14. Cahali RB, Zimbres SA, Tsuji DH, Cahali MB, Sennes LU. Cistos supraglóticos de laringe: aspectos etiológicos, clínicos e terapêuticos. *Rev Bras Otorrinolaringol*. 2002 Oct;68(5):663–6.
15. Aksoy HT, Süslü N, Demirel G, Celik I, Canpolat FE, Erdeve O, et al. Congenital laryngeal cyst: a rare cause of polyhydramnios. *APSP J Case Rep*. 2013;4(2):12.
16. D'Heygere E, Vauterin T, Casselman JW, Kuhweide R, Dick C. Congenital laryngeal cyst: an unusual cause of stridor in the neonate. *B-ENT*. 2015;11(4):313–7.
17. Gallant JN, Ransom M, Kaspar A, Wilcox LJ, Whigham AS, Engelstad HJ. Neonatal Laryngotracheal Anomalies. *NeoReviews*. 2022 Sep 1;23(9):e613–24.
18. Long BD, Carroll W. Review of obstructive pediatric airway pathology. *Operative Techniques in Otolaryngology-Head and Neck Surgery*. 2022 Sep;33(3):166–74.
19. Shetty SM, Archana S. Anatomy and Physiology of the Airway Applied Aspects. In: Ubaradka RS, Gupta N, Bidkar PU, Tripathy DK, Gupta A. *The Airway Manual*. Singapore: Springer Nature Singapore; 2023. p. 21–43.
20. Baljošević I, Sovtić A, Slaviša Antić. Treatment of congenital laryngeal cysts in newborns. 2021 [cited 2023 Nov 16]; Available from: <http://rgdoi.net/10.13140/RG.2.2.31268.40327>
21. Miller KA, Nagler J. Advances in Emergent Airway Management in Pediatrics. *Emerg Med Clin North Am*. 2019 Aug;37(3):473–91.
22. Park RS, Peyton JM, Kovatsis PG. Neonatal Airway Management. *Clinics in Perinatology*. 2019 Dec;46(4):745–63.
23. Singh J, Jain N, Jajoo M, Roy S, Narang E, Mahajan N. Varied Clinical Presentation and Management of Paediatric Vallecular Cyst. *Sultan Qaboos Univ Med J*. 2021 Nov;21(4):639–43.
24. Chen EY, Lim J, Boss EF, Inglis AF, Ou H, Sie KCY, et al. Transoral approach for direct and complete excision of vallecular cysts in children. *International Journal of Pediatric Otorhinolaryngology*. 2011 Sep;75(9):1147–51.
25. Amooee A, Safi Dahaj F, Taghipour Zahir S, Alamdar Yazdi A. Congenital laryngeal cyst causing repeated airway obstruction in a six-year-old girl. *J Pediatr Adolesc Surg [Internet]*. 2021 Jan 18 [cited 2023 Nov 16];1(2). Available from: <http://jpedas.org/ojs/index.php/jpedas/article/view/51>
26. Al-Kurdi MAM, Razzouk Q, Hussein OS, Sawas R, Morjan M. Successful excision of a large congenital vallecular cyst in a female newborn: A case report. *International Journal of Surgery Case Reports*. 2023 Sep;110:108626.
27. Hurtado EM, Errazquin AT, Saldaña PM, Ruiz ES, Escoda NA, Merchante MS. Lessons Learned From a Failed Intubation of a Patient With a Giant Laryngeal Cyst. *Benefits*. 2023;28. Zhang R, Jiang X, Feng J. Difficult endotracheal intubation due to a large epiglottic cyst: A case report. *Medicine*. 2023 Jun 16;102(24):e34026.

29. Lamercy K, Pincet L, Sandu K. Intubation Related Laryngeal Injuries in Pediatric Population. *Front Pediatr.* 2021;9:594832.

UNDER PEER REVIEW