

Case study**Annular Pancreas with intestinal malrotation
in 12 years' girl: A Rare Case Report****Abstract**

Annular pancreas is a congenital anomaly characterized by the presence of a ring of pancreatic tissue that partially or completely encircles the second part of the duodenum. This condition results from the failure of the vertical pancreatic bud to rotate properly, leading to its elongation and encircling of the upper section of the duodenum.

The first description of annular pancreas was made by Tiedemann in 1818, and the term "Annular pancreas" was coined by Ecker in 1982. In the normal development of the pancreas, the dorsal and ventral pancreatic buds fuse during the first 4-8 weeks of embryonic life. In cases of annular pancreas, the ventral bud fails to rotate as it should, causing it to elongate and encircle the upper part of the duodenum. This condition can affect individuals from neonates to the elderly, making it challenging to diagnose.

Diagnosing annular pancreas can be accomplished through various methods, including preoperative procedures such as upper GI endoscopy, Barium meal follow-through, CT and MRI scans, ERCP (endoscopic retrograde cholangiopancreatography), and endoscopic ultrasonography (EUS). In approximately 40% of cases, surgical intervention is necessary to confirm the diagnosis.

We present a rare case of annular pancreas in a 12-year-old girl who also had intestinal malrotation. She was experiencing frequent episodes of vomiting. Her diagnosis was confirmed through a Barium meal follow-through, which revealed a typical "Double bubble" sign. She underwent a gastrojejunostomy and a modified Ladd's operative procedure to address the condition.

Key words

Annular pancreas, Intestinal malrotation, Gastro-jejunostomy

Introduction

"Annular pancreas is a rare congenital anomaly characterized by the presence of pancreatic tissue that either partially or completely obstructs the second part of the duodenum. This condition arises from the failure of the ventral pancreatic bud to migrate properly, resulting in the encirclement of the duodenum by pancreatic tissue. It is estimated to occur in approximately 1 in 12,000 to 15,000 live births. The incidence of annular pancreas in autopsy cases of adults has been reported to range from 0.0005% to 0.015%. To date, only 737 cases have been reported in the English literature, with a slight preponderance of cases in females. The majority of reported cases occur in new born, with occurrences in adults being rare". [1,2,4]

"Infants with annular pancreas may also exhibit associated congenital anomalies, such as malrotation, oesophageal atresia, duodenal atresia, pancreatic divisum, biliary atresia, renal

anomalies, anorectal malformation, and congenital heart disease. In adults, the most common associated anomalies are pancreatic divisum, malformation, and duodenal webs". [4,5, 10]

Annular pancreas can be classified as either complete or incomplete:

1. Complete annular pancreas: Pancreatic tissue or an annular duct completely surrounds the second part of the duodenum.
2. Incomplete annular pancreas: Pancreatic tissue does not entirely encircle the duodenum, resulting in a "Crocodile Jaw" appearance.

Clinical manifestations of annular pancreas can occur at any age, from infancy to adulthood. In infants, symptoms often include non-bilious vomiting, bloating, and feeding intolerance. The diagnosis of annular pancreas can be established through plain abdominal radiographs, which typically show the classical "Double bubble sign". Barium meal follow-through studies and upper GI endoscopy can also aid in the diagnosis of annular pancreas. In adults, diagnosis is often made through imaging techniques such as CT and MRI. Endoscopic retrograde cholangiopancreatography (ERCP), endoscopic ultrasonography (EUS), and the gold standard for diagnosing annular pancreas remains surgical laparotomy. [1,3,4,5]

The treatment for symptomatic, obstructing annular pancreas typically involves a bypass operation, such as gastrojejunostomy or duodenoduodenostomy, in both adults and children. It is generally not recommended to divide the pancreatic annulus due to the increased risk of pancreatic fistula and duodenal stenosis. [3,4,9]

Case Report

On December 13, 2007, a 12-year-old girl was admitted to our centre with a history of recurrent non-bilious vomiting and weight loss. Upon physical examination, it was evident that she was malnourished, underweight, and had a slender build. An initial plain X-ray of her abdomen showed the presence of air in the stomach and the first part of the duodenum. A subsequent barium meal follow-through confirmed the presence of the characteristic "Double bubble" sign, indicating stomach and pylorus involvement as well as a diffuse narrowing of the second part of the duodenum. A CT scan of the abdomen was not performed at that time.

The patient's condition was stabilized through the administration of intravenous fluids, antiemetic, and antibiotics. Her vital signs remained within the normal range, and all her blood tests returned normal results. Subsequently, an exploratory laparotomy was carried out through a transverse incision, revealing a case of annular pancreas with duodenal obstruction. The stomach and the proximal part of the duodenum were significantly distended due to the complete duodenal obstruction. To our surprise, we also observed the presence of the cecum and appendix with Ladd's band in the epigastric region. The small bowel was normally positioned on the right side of the abdomen. This presented a very rare combination of complete annular pancreas with intestinal malrotation.

In light of these findings, a simple gastro-jejunostomy and a modified Ladd's procedure were performed. All Ladd's bands attaching the cecum to the abdominal wall were released, and no volvulus was observed during the appendectomy. Two days after the surgery, the patient experienced no further vomiting, and her post-operative recovery proceeded without any complications. She was discharged on the 8th day following the surgery. During a two-year follow-up, the girl's health improved significantly. **(Fig 1-10)**

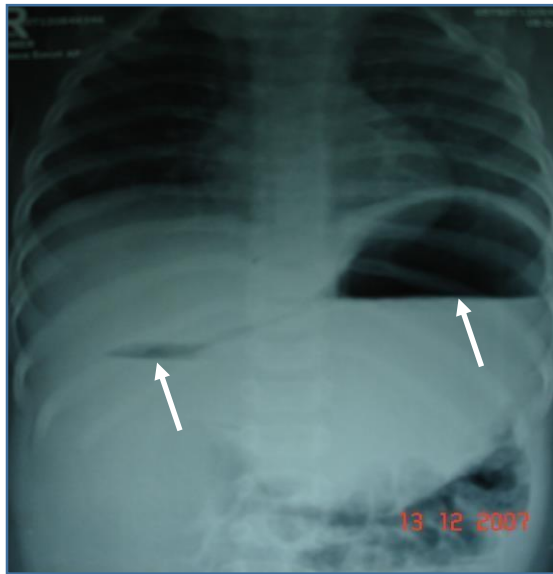


Fig-1 Plain abdominal x-ray shows air in the stomach and first part duodenum "double bubble sign"

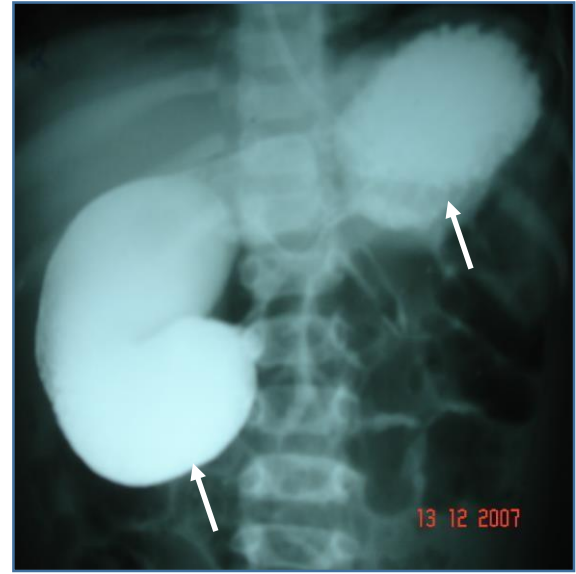


Fig-2 Barium meal follow- through shows dilated stomach and first part of duodenum

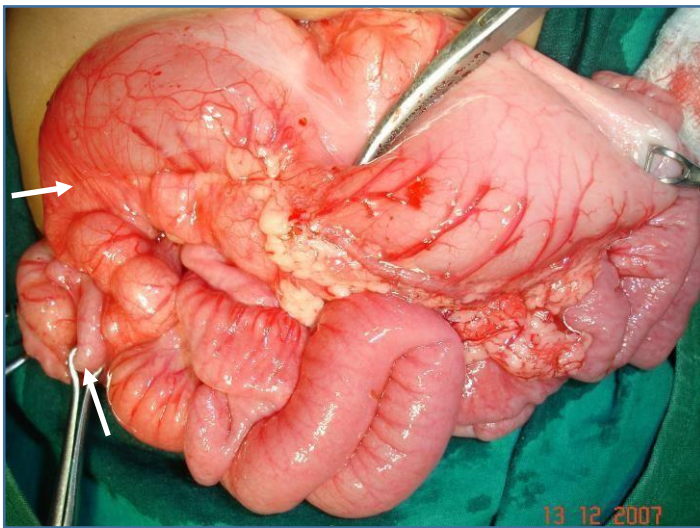


Fig-3 Intraoperative photographs showing markedly distended stomach and first part of duodenum with malrotation

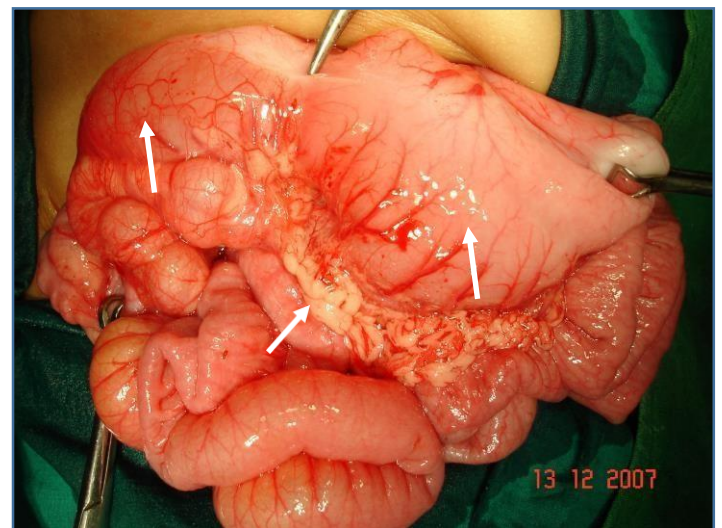


Fig-4 Intraoperative photographs showing markedly distended stomach and first part of duodenum

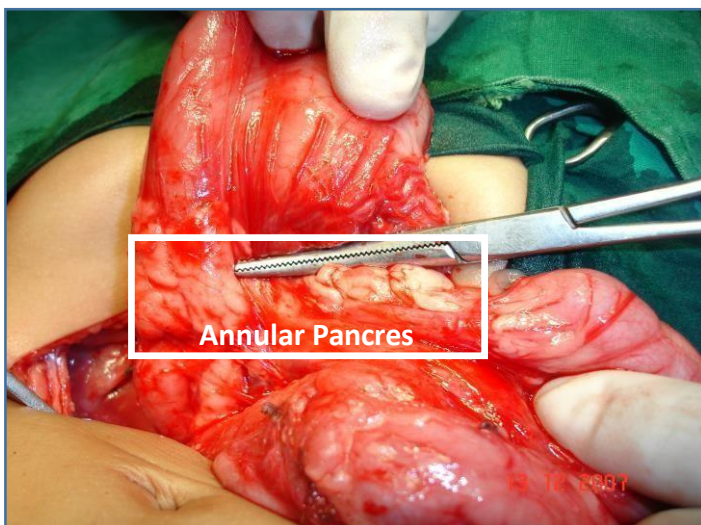


Fig-5 Intraoperative photographs showing annular pancreas encircling the duodenum

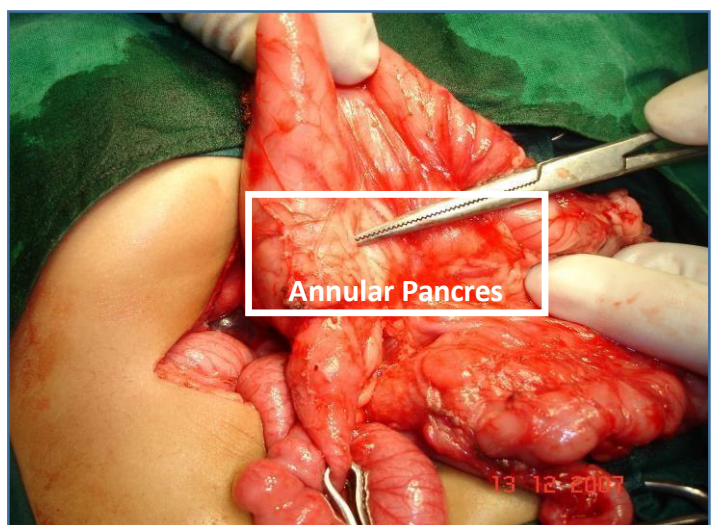


Fig-6 Intraoperative photographs showing annular pancreas encircling the duodenum

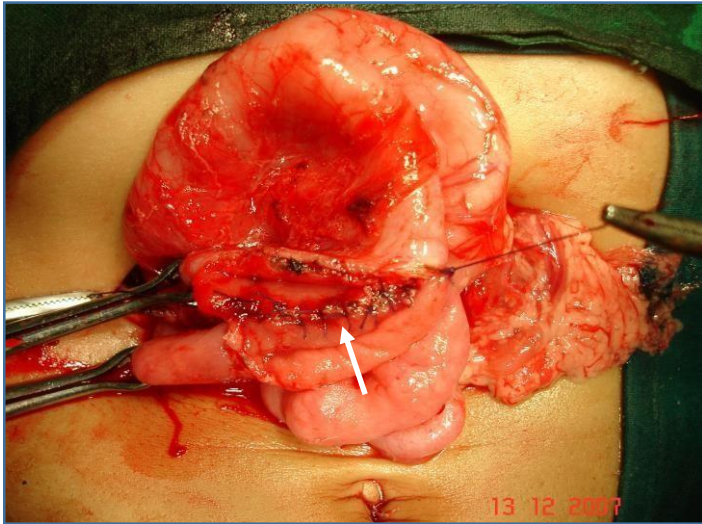


Fig-7 Intraoperative photographs showing gastrojejunostomy procedure

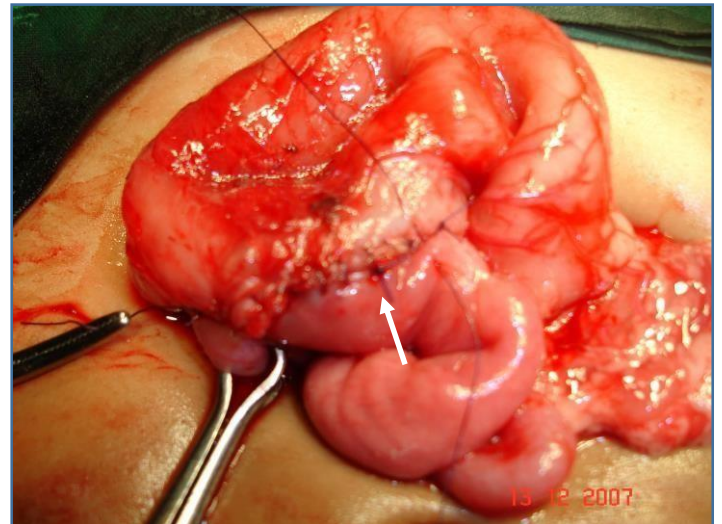


Fig-8 Intraoperative photographs showing gastrojejunostomy procedure completed

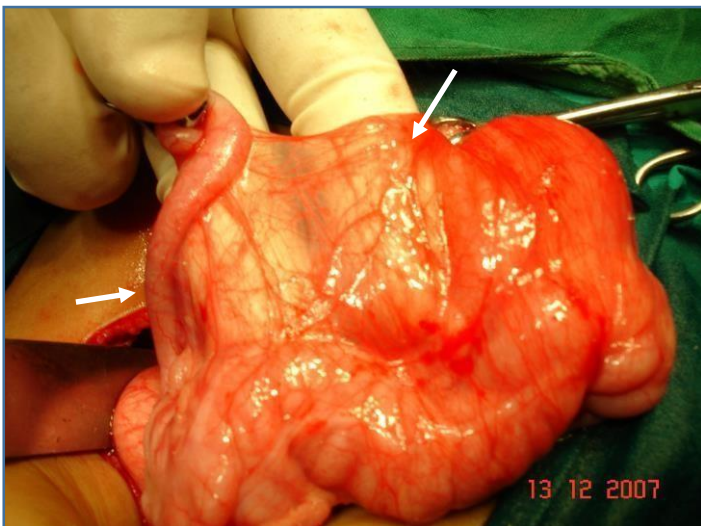


Fig-9 Intraoperative photographs showing Ladd's band at cecum

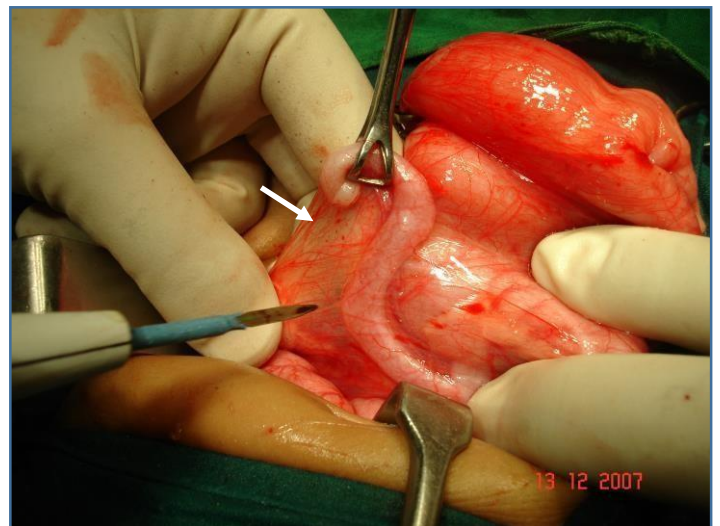


Fig-10 Intraoperative photographs showing modified Ladd's procedure with appendectomy

Discussion

Annular pancreas is a congenital anomaly in which the pancreas develops from a single dorsal bud and two ventral buds that appear during the 5th week of gestation as outgrowths of the primitive foregut. The two ventral buds eventually fuse. By the 7th week of gestation, the duodenum's expansion causes the vertical bud to rotate and pass behind the duodenum from right to left, fusing with the dorsal bud. The ventral bud forms the inferior part of the uncinate process and the inferior head of the pancreas, while the dorsal bud gives rise to the body and tail of the pancreas. The fusion of the ducts from these two buds forms the main pancreatic

duct. "Annular pancreas occurs when the ventral bud fails to properly rotate with the duodenum, resulting in the encircling of the duodenum by a band of pancreatic tissue that either partially or completely encircles the second part of the duodenum. In about 85% of diagnosed cases, this encircling band is located above the papilla of Vater". [1,4,6]

Various theories have been proposed to explain this anomaly:

1. Lecco's Theory - Suggests adherence of the right ventral bud to the duodenal wall before rotation and encirclement of the duodenum.
2. Baldwin's Theory - Points to the persistence and enlargement of the left ventral bud.
3. Hypertrophy and fusion of the ventral and dorsal buds before gut rotation, leading to the complete encircling of the duodenum. [4,5,9]

Annular pancreas has been classified into six types based on the drainage site of the annular duct:

- Type I: The annular duct directly flows into the main pancreatic duct.
- Type II: The duct of Wirsung encircles the duodenum but still drains at the major papilla.

"The other four subtypes are much less common, and in 40% of cases, a definitive diagnosis is only made during laparotomy. Annular pancreas is often associated with conditions like Down syndrome, polyhydramnios, intestinal malrotation, duodenal and biliary atresia, omphalocele, colorectal malformations, and congenital heart disease. More than two-thirds of children with annular pancreas present with gastric outlet obstruction". [2,4,5]

"Diagnosis can be made through ultrasonography or plain abdominal radiographs, which often show the classical "Double bubble sign." In adults, CT and MRI imaging are typically used for diagnosis, while newer techniques like endoscopic retrograde cholangiopancreatography (ERCP) and endoscopic ultrasonography (EUS) may also be employed". [4,5,10]

Surgical management remains the preferred treatment for symptomatic annular pancreas. The goal of surgery is to alleviate duodenal or gastric outlet obstruction through bypass procedures such as gastrojejunostomy, duodenojejunostomy, or duodenoduodenostomy. Resection of the annulus should generally be avoided, as it is associated with serious complications, including pancreatitis, pancreatic fistula, and incomplete relief of obstruction, which can lead to mortality. In neonates, duodenoduodenostomy is the treatment of choice due to its lower incidence of postoperative complications. In adults, gastrojejunostomy or duodenojejunostomy is recommended. [4,5,7,8]

Conclusion

Annular pancreas with intestinal malrotation is a rare. We performed gastro-jejunostomy with modified Ladd's procedure for malrotation. Prognosis is excellent. We treat this condition without touching the actual organ annular pancreas which is involved.

Ethical Approval:

As per international standards or university standards written ethical approval has been collected and preserved by the author(s).

Consent

As per international standards, parental written consent has been collected and preserved by the author(s).

References

1. Alahmadi R, Almuhammadi S. Annular pancreas: a cause of gastric outlet obstruction in

a 20-year-old patient. Am J Case Rep. 2014 Oct 9;15:437-40. doi:
10.12659/AJCR.891041. PMID: 25300027; PMCID: PMC4206480.

2. Shabaka A, Mateos-Sánchez P, Amador-Borrero B, Antolín J, Cigüenza R. Symptomatic annular pancreas in an adult: an unusual cause of abdominal pain. *Dig Med Res* 2019;2:3.
3. Suk-Bae Moon, Annular pancreas in an 11-year-old girl: a case report, *International Medical Case Reports Journal*, IMCRJ (dovepress.com)
4. Husaric, Edin & Husarić, Edin & Hotić, Nešad & Halilbašić, Amir & Rahmanović, Emir & Suljendić, Sanimir. (2014). Annular pancreas with duodenal stenosis and intestinal malrotation in two years girl: A case report. *Paediatrics Today* 2014;10(1):47-50 DOI 10.5457/p2005-114.88. 10. 10.5457/p2005-114.88.
5. Shashikant Kulgod, Amit Shivshankar Ammanag, A Case of Malrotation of Mid Gut with Incidental Finding of Annular Pancreas, *International Journal of Anatomy, Radiology and Surgery*. 2017 Apr, Vol-6(2): SC01-SC02
6. B Selvaraj, K Senthil Kumaran, G P Sekar. Annular pancreas – a case report and review of the literature. *International Journal of Recent Trends in Science and Technology* January to March 2020; 10(1): 70-74 <http://www.statperson.com>
7. Dr Ayushi Vig, Dr Kirtikumar J Rathod, Dr Neeraj Gupta, Dr Kamlesh Kumari, Dr Arvind Sinha, Laparoscopic treatment of annular pancreas in a neonate, *Journal of Pediatric Surgery Case Reports*, <https://doi.org/10.1016/j.epsc.2021.101914>.
8. Dr. Niharika Prasad, Dr. Sanjay M. Khaladk, Partial malrotation with incomplete annular pancreas, midgut volvulus and Superior mesenteric artery syndrome
URL:<https://www.eurorad.org/case/17089>
9. Makkadafi, M., Fauzi, A.R., Wandita, S. et al. Outcomes and survival of infants with congenital duodenal obstruction following Kimura procedure with post-anastomosis jejunostomy feeding tube. *BMC Gastroenterol* 21, 100 (2021).
<https://doi.org/10.1186/s12876-021-01679-8>
10. Urayama S, Kozarek R, Ball T, Brandabur J, Traverso L, Ryan J, et al. Presentation and treatment of annular pancreas in an adult population. *Am J Gastroenterol* 1995; 90(6): 995-9