

## Original Research Article

# Assessment of testosterone levels and sperm motility variables of Mercury toxicity induced male Albino Rats treated with *Pentaclethra macrophylla* seed (Ugba)

### ABSTRACT

**Aim:** To assess testosterone levels and sperm motility variables of mercury toxicity induced male Albino Rats treated with *Pentaclethra macrophylla* seed (Ugba).

**Study design:** An experimental study.

**Place and Duration of Study:** Department of Animal and Environmental Biology Animal House, Rivers State University, Port Harcourt, Nigeria, between January 2019 and January 2021.

**Methodology:** Thirty-six (36) adult male albino rats weighing approximately  $135 \pm 1.5$ g were purchased from University of Port Harcourt, Rivers State, Nigeria. They were housed in plastic suspended cages, placed in well-ventilated conditions, and provided with rat diet and water and acclimatize for two weeks. Fresh matured seeds of *Pentaclethra macrophylla* (African oil bean seed) were sourced locally from markets in Imo state, Nigeria. The washed and sliced seeds were stored at room temperature and allowed to ferment. The fermented seeds were dried, ground and preserved in airtight container in the refrigerator at  $4^{\circ}\text{C}$ . The total weight of the powdered seed of *Pentaclethra macrophylla* produced was 250g. Seeds were thoroughly washed with distilled water, cooked for more than 2 hours at  $100^{\circ}\text{C}$ . Maceration technique was used to carry out an ethanolic extract of the plant seed. Mercury chloride salt was purchased in Port Harcourt. A standard dose of 3.0mg/kg body weight of mercury chloride obtained from acute toxicity study dose determination was administered to the rats for 30 days after they were divided into six groups of six rats per group. After 30 days, all the animals were weighed, anaesthetized using chloroform. Blood sample was drawn via cardiac puncture and tissue samples of the testis were collected and used for histological analysis. Epididymal sperm number was estimated by crushing excised cauda epididymis in suspension medium. SPSS version 23 was used for statistical analysis and p values less than 0.05 were considered significant.

**Results:** The results showed that there was a significant reduction ( $p < 0.05$ ) in percentage sperm viability, motility, testosterone levels, sperm count and a significantly elevated abnormal sperm morphology and dead sperm percentage in group 2 animals after induction with varying concentration of mercury compared to that of the control rats, but the former parameters were significantly elevated while there were significant reductions in the latter parameters after treatment with PM (groups 4 and 5).

**Conclusion:** Induction with mercury caused a reduction in testosterone levels and poor sperm quality index (motility, count & viability), but were significantly improved after treating with PM.

**Keywords:** Testosterone, sperm motility variables, Mercury toxicity, Albino Rats, *Pentaclethra macrophylla* seed (Ugba)

## 1. INTRODUCTION

Despite considerable progress in understanding the underlying mechanisms of mercury toxicity and available treatment or management option, mercury intoxication is still a serious health concern [1,2]. Due to their ubiquitous nature, humans are at high risk of exposure to mercury, their metabolites, and derivatives, which are capable of disrupting hormonal, renal and hepatic functions [2,3,4].

Administration of mercury has been acknowledged to aggravate destruction of testicular role as evidenced by pathological alterations of the testis and indicators of reproductive viability like, sperm quality variables, androgen, and testicular architectures [2,3,5]. Mercury compounds are identified to have effect on testicular spermatogenic and steroidogenic roles in humans and experimental models [2,6]. Mercury intoxication has been reported to encourage androgen lack and to decrease secretory epididymal components needed for sperm maturation [2,6]. Reductions in serum testosterone, sperm count, motility, vitality, and viability have been reported in mercury administered rats and mice [5]. Although, the effects of inorganic mercury on the male reproductive system have been investigated, small information is accessible concerning the basic mechanisms in the pathogenesis of male reproductive malfunction[5].

The transition metals act as catalysts in the oxidative deterioration of biological macromolecules, therefore, the toxicities associated with metals may be due at least in part to oxidative damage to tissues. A few evidence advocate the role of oxidative stress in mercury induced tissue toxicity [3].

Indeed, the use of plants and natural products in the therapeutic management of testis associated toxicity possibly due to fewer side effects is a focus of most research models. Thus, the search for viable therapeutic candidates of plant origin that could protect against mercury-induced organ damage is desirable [4]. The aim of this study was to assess testosterone levels and sperm motility variables of mercury toxicity induced male Albino Rats treated with *Pentaclethra macrophylla* seed (Ugba).

## 2. MATERIALS AND METHODS

### 2.1 Experimental Animals

Thirty - six (36) adult male albino rats weighing approximately  $135 \pm 1.5$ g were purchased from University of Port Harcourt, Rivers State, Nigeria and were used for this research work. The animals were housed in plastic suspended cages, placed in well-ventilated conditions, and provided with rat diet and water. The ethical regulations on animal care and handling of the National Academy of Science were observed and the rats were made to acclimatize for 14 days prior to experiment.

### 2.2 Collection and identification of Plant Materials

Fresh matured seeds of *Pentaclethra macrophylla* (African oil bean seed) were sourced locally from markets in Imo state, Nigeria. The seeds were identified by Dr. Mbagwu V. of the department of plant science and Biotechnology, Imo state University, Owerri.

### 2.3 Preparation of *Pentaclethra macrophylla* powder from Seed

Seeds were thoroughly washed with distilled water, cooked for 2 hours at  $100^{\circ}\text{C}$  to remove the seed coats, washed three times, sliced, and cooked for another 2 hours at  $100^{\circ}\text{C}$ , rinsed three times with distilled water [7]. The washed and sliced seeds were stored at room temperature and allowed to ferment. The fermented seeds were dried, ground and preserved in airtight container in the refrigerator at  $4^{\circ}\text{C}$ . The total weight of the powdered seed of *Pentaclethra macrophylla* produced was 250g.

### 2.4 Ethanol Extraction (Maceration method) [8]

Maceration technique was used to extract the phytochemical content of the plant seed used in this research work. 52g of the ground seed powder was soaked in 100mls of ethanol and allowed to stand at room temperature of 25°C for 72 hours with agitation at interval of one hour. At the end of the third day, the content was filtered using Whatman no 1 filter paper and filtrate was subjected to rotary evaporator to remove the ethanol content. The recovered solute (powder) was then weighed again to enable the calculation of percentage yield.

### **2.5 Calculation for Percentage yield of Ethanol Seed Extract**

To calculate the percentage yield of ethanol seed extract (g) =  $W1 \times 100/W2$ .

Where,

W1 = Weight of dried powder of the extract obtained after solvent removal = 52grams.

W2 = Weight of the dried powdered seed sample before adding to solvent = 100grams.

To calculate the percentage yield of ethanolic seed extract =  $52 \times \frac{100}{100} = 52\%$

### **2.6 Preparation of Seed extract for Treatment**

Following the ethanolic extraction and evaporation of ethanol, a total of 52grams of the seed in powdered form were recovered. 52grams of the post – ethanolic extract powder was dissolved in 100mls of corn oil. Therefore, 1.0ml of the solution contain 0.5g/ml of the extract. Therefore, in 135±1.5g rats, 0.5g/ml will be equivalent to 3.7g/kg body weight of rats.

### **2.7 Procurement and Preparation of Mercury Chloride Salt**

Mercury chloride salt was purchased in Port Harcourt from Joe Kings Chemicals and made in China in a granular form. The salt is of industrial grade of 99.5% purity. Since the salt was purchased in a granular form, there was a need to dissolve the salt in Corn oil to facilitate oral treatment in the rats. 3.0mg of mercury chloride were weighed and dissolved in sterile container containing 8.0ml of corn oil. The contents of the container were mixed to ensure complete dissolution of the salt. This implies that 1.0ml of this solution contains 0.375mg of mercury chloride.

### **2.8 Administration of Mercury Chloride and *Pentaclethra macrophylla* seed extract**

The method of treatment in the acute studies involved oral technique. In the oral treatment, mercury chloride salt and *Pentaclethramacropohylla* seed extract were administered using gavage tube inserted directly into the oesophagus of the rats through the mouth to ensure complete delivery of the salt and seed extract respectively.

### **2.9 Reagents and Chemicals**

Mercury chloride (Kermel, China), tetraoxosulphate vi acid, sulphanilamide, hydrochloric acid, thiobarbituric acid, trichloroacetic acid, sodium hydroxide, ethylene - diaminetetraaceticacid, sodium pyrophosphate, 5, 5 – dithiobis – 2 – nitrobenzoate, sodium nitroprusside, urease, phenol, picric acid, 2, 4 – dinitrophenyl hydrazine ( UK ), were obtained in Port Harcourt.

### **2.10 Toxicity Induction with Mercury Chloride (HgCL<sub>2</sub>)**

After two weeks of acclimatization, toxicity was induced in the male albino rats with mercury chloride (HgCL<sub>2</sub>). A standard dose of 3.0mg/kg body weight of mercury chloride obtained from acute toxicity study dose determination was used to induce organ toxicity in the experimental rats. Organ and Tissue damage were determined by evaluating testicular parameters under review.

### **2.11 Experimental Design**

Thirty-six (36) male adult albino rats weighing approximately  $135 \pm 1.5$ g/kg were used for this research study. The animals were placed into six groups, each containing six rats and the duration of the experiment was 30 days. Mercury (II) chloride ( $\text{HgCl}_2$ ) was dissolved in corn oil and administered three times a week by oral gavage. The administered dose of 3.0mg/kg body weight was done orally using gavage tube. *Pentaclethra macrophylla* seed extract was dissolved in corn oil and administered to the rats daily for 30 days.

Group 1: Control (rats received corn oil at 2ml/kg)

Group 2:  $\text{HgCl}_2$  (rats were administered 3.0 mg/kg  $\text{HgCl}_2$ )

Group 3: 100mg/kg P.M +  $\text{HgCl}_2$  (rats were treated with 100mg/kg P. M. and 3.0mg/kg  $\text{HgCl}_2$ )

Group 4: 200mg/kg P.M +  $\text{HgCl}_2$  (rats were treated with 200mg/kg P. M. and 3.0mg/kg  $\text{HgCl}_2$ )

Group 5: 100mg/kg P.M (rats were treated with 100mg/kg *Pentaclethra macrophylla* alone)

Group 6: 200mg/kg P.M (rats were treated with 200mg/kg *Pentaclethra macrophylla* alone)

## **2.12 Blood and Tissue samples Collection and Preparation.**

After 30 days, all the animals were weighed, anaesthetized using chloroform. Blood was collected by cardiac puncture into plain tubes. Samples were obtained by centrifugation of the clotted blood at 3500rpm for 10minutes. The serum specimen was stored at  $20^\circ\text{C}$  prior to the biochemical analysis. Testicular tissues and cells were immediately excised, washed in isotonic water and 1% formal saline.

## **2.13 Laboratory Procedures**

### **2.5.1.6 Determination of Serum Testosterone by ELISA method**

#### **3.5.1.7 Principle**

The principle of testosterone measurement is based on competitive binding between testosterone in sample and testosterone - HRP conjugate for a constant amount of rabbit anti - testosterone. On incubation of goat anti - rabbit IgG coated wells with testosterone containing samples; a fixed amount of HRP - labelled testosterone competes with the endogenous testosterone in the sample for a fixed number of binding sites of the specific testosterone antibody. The amount of testosterone peroxidase enzyme conjugates immunologically bound to the well progressively decreases as the concentration of testosterone increases. After washing off unbound testosterone, bound HRP - testosterone in the sample in the presence of testosterone peroxidase conjugate enzyme oxidizes the chromogen (TMB) to give a blue colour whose intensity is inversely proportional to the concentration of testosterone and directly proportional to testosterone peroxidase conjugate enzyme.

## **3.6 Sperm quality analysis.**

### **3.6.1 Procedure for sperm collection**

After thirty (30) days of the experiment, all the experimental animals were weighed, anaesthetized using chloroform. The surfaces of the testes were sterilized with 70% alcohol to avoid germs and surface contamination of the semen. The rat epididymis (where the mature and motile spermatozoa are housed) were lacerated to press out the semen from the organ. The semen was emulsified thoroughly with 0.5% of eosin stain. The mixture was placed on a clean microscope viewing slide covered with cover slip ready for immediate examination.

#### **3.6.1.1 Sperm motility determination by Sonmez et al.[8]**

### **3.6.1.2 Procedure.**

Small drop of semen suspended in the semen incubation medium (Tris aminomethane, citric acid and fructose) was placed on a slide. A coverslip was placed on the drop, and it was examined under the microscope for the estimation of spermatozoa motility. Observation was done at 100x magnification.

### **3.6.1.3 Sperm viability (live-dead count) by Wyrobeck and Bruce [9]**

#### **3.6.1.4 Principle**

The live-dead staining principle is based on the observation that eosin B penetrates and stains the dead sperm cells, whereas the viable cells repel this stain. To benefit from the live-dead method, staining should be done without delay. The live-dead count supplements, rather than replaces the motility test.

#### **3.6.1.5 Procedure**

Aliquots of sperm suspension in semen incubation medium were placed on a slide and stained with 1% eosin B and 5% nigrosin. The slide was examined at 100X magnification. At least 100 stained and unstained cells were counted, and the percentage of each group was estimated.

### **3.6.1.6 Sperm morphology examination by Wyrobeck and Bruce [9]**

The examination is performed to determine the presence and extent of occurrence of morphologically abnormal forms of spermatozoa according to Wyrobeck and Bruce [9]

#### **3.6.1.7 Procedure**

The same stained smear used for live-dead count can be used for the detection of abnormal sperm cells. Alternatively, aliquots of sperm suspension can be stained with the Wells and Awa stain instead of eosin B and nigrosin. Cell morphology was studied under high power (400x). Individual cells were examined and classified according to the classification proposed by Blom[10].

### **3.6.1.8 Epididymal sperm count by Pant and Srivastava, [11]**

#### **3.6.1.9 Procedure**

Number of sperms in rat epididymis was estimated according to the method described by Pant and Srivastava, [11]. Epididymal sperm number was estimated by crushing excised caudaepididymis in suspension medium containing 140 mmol of NaCl, 0.3 mmol of KCl, 0.8 mmol of Na<sub>2</sub>HPO<sub>4</sub>, 0.2 mmol of KH<sub>2</sub>PO<sub>4</sub> and 1.5 mmol of D-glucose (pH adjusted to 7.3). Sperms were collected and counted using hemacytometer under Phase Contrast Olympus Trinocular microscope at x 200 magnification. The values were expressed as an average of total sperm counts per ml of suspension [12].

### **3.3.1.7 Histological and morphometric analyses of the Testis**

Histological examination of the testis was carried out according to the procedure described by Drury and Wallington [13]. Bouin's fixed testicular tissues of the experimental rats were dehydrated in graded series of ethanol and embedded in ethanol. Serial sections (5µm) for histological evaluation with light microscope by an experienced pathologist.

## **2.14 Statistical Analyses**

Data were expressed as mean  $\pm$ SD, and the statistical analysis was performed with the SPSS statistics 23.0 (SPSS Inc. Chicago, IL). All the statistical analysis were analysed by

ANOVA followed by Tukey's multiple tests.  $P < .05$  were considered to indicate statistical significance.

### 3. RESULTS AND DISCUSSION

**Table 1: Percentage sperm viability and Abnormal sperm morphology of rats exposed to mercury chloride (HgCl<sub>2</sub>) and *Pentaclethra macrophylla* (PM) Seed Extract for thirty (30) days**

Parameters	Sperm viability (%)	Abnormal sperm morphology (%)
Control	72.50±5.24	23.33±6.83
HgCl (3.0mg/kg)	34.17±3.76 <sup>a</sup>	37.50±2.74 <sup>a</sup>
HgCl(3.0mg/kg)+PM(100mg/kg)	43.33±2.58 <sup>a,b</sup>	30.00±4.47 <sup>b</sup>
HgCl (3.0mg/kg)+PM(200mg/kg)	52.50±2.74 <sup>a,b</sup>	27.50±2.74 <sup>a,b</sup>
PM (100mg/kg)	71.67±4.08 <sup>b</sup>	16.67±4.08 <sup>a,b</sup>
PM (200mg/kg)	82.50±5.24 <sup>a,b</sup>	14.17±3.76 <sup>a,b</sup>
p-value	0.000	0.001
F-value	129.467	24.126
Remark	S	S

Each value represents the mean ± SD; <sup>a</sup>Significantly different from the control; <sup>b</sup>Significantly different from HgCl<sub>2</sub> ( $p < 0.05$ ).

Key: S - Significant

**Table 2: Percentage sperm motility and Dead sperm of rats exposed to mercury chloride (HgCl<sub>2</sub>) and *Pentaclethra Macrophylla* (PM) Seed Extract for thirty (30) days.**

Parameters	Motility sperm (%)	Dead sperm (%)
Control	64.17±3.76	16.67±2.58
HgCl (3.0mg/kg)	23.33±2.58 <sup>a</sup>	29.16 ± 4.92 <sup>a</sup>
HgCl(3.0mg/kg)+PM(100mg/kg)	35.00±3.16 <sup>a,b</sup>	17.50±2.74 <sup>b</sup>
HgCl (3.0mg/kg)+PM(200mg/kg)	42.83±2.48 <sup>a,b</sup>	13.33±0.81 <sup>b</sup>
PM (100mg/kg)	64.50±9.14 <sup>b</sup>	8.33±2.58 <sup>a,b</sup>
PM (200mg/kg)	79.17±5.85 <sup>a,b</sup>	5.83±2.04 <sup>a,b</sup>
p-value	0.000	0.001
F-value	104.072	32.000
Remark	S	S

Each value represents the mean ± SD; <sup>a</sup>Significantly different from the control; <sup>b</sup>Significantly different from HgCl<sub>2</sub> ( $p < 0.05$ ).

**Table 3: Serum testosterone concentration and Sperm count of rats exposed to mercury chloride (HgCl<sub>2</sub>) and *Pentaclethra Macrophylla* (PM) Seed Extract for thirty (30) days.**

Parameters	Testosterone (ng/ml)	Sperm count (millions/mL)
Control	0.41±0.04	219.83±17.66
HgCl (3.0mg/kg)	0.21±0.02 <sup>a</sup>	125.83±22.00 <sup>a</sup>
HgCl(3.0mg/kg)+PM(100mg/kg)	0.24±0.07 <sup>a</sup>	147.00 ± 13.13 <sup>b</sup>
HgCl (3.0mg/kg)+PM(200mg/kg)	0.32±0.06 <sup>a</sup>	161.17±6.88 <sup>b</sup>
PM (100mg/kg)	0.33±0.07 <sup>b</sup>	183.33±32.65
PM (200mg/kg)	0.37±0.09 <sup>a,b</sup>	220.17 ± 20.10
p-value	0.121	0.005
F-value	6.548	0.005
Remark	NS	S

Each value represents the mean ± SD; <sup>a</sup> Significantly different from the control; <sup>b</sup> significantly different from HgCl<sub>2</sub> (p < 0.05).

Key : S - Significant.  
NS – Not significant.

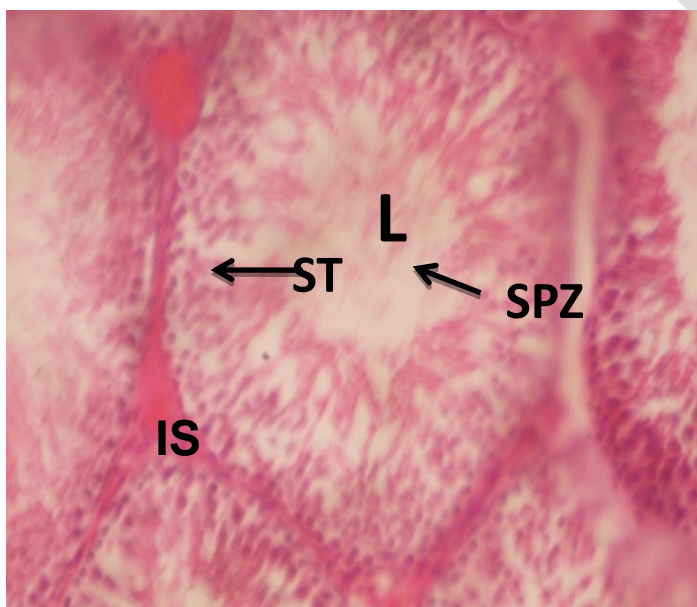

Plate 1: Representative photomicrograph of section of the Testis from control group 1. H&E, MAG: 400X, Treatment substance. nil. A well outlined seminiferous tubules (ST). The interstitial (IS) cells of Leydig were intact. The luminal (L) cell types in its normal arrangement were intact. The centre of seminiferous tubules was filled with spermatozoa (SPZ) - like cells.

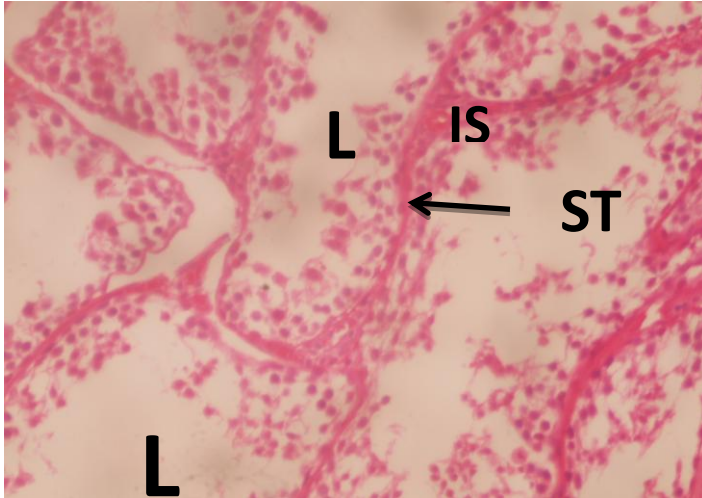


Plate 2: Photomicrograph of section of the Testis from group 2. H&E, MAG: 400X, DOSE: 3.0mg/kg Hgcl<sub>2</sub> alone for 30 days. Treatment substance.mercury chloride. Seminiferous tubules (ST) squeezed against itself. The luminal (L) spermatogonia cell arrangement was distorted. Most of the cell types appeared degenerated. There was gross desquamation of luminal (L) cell types.

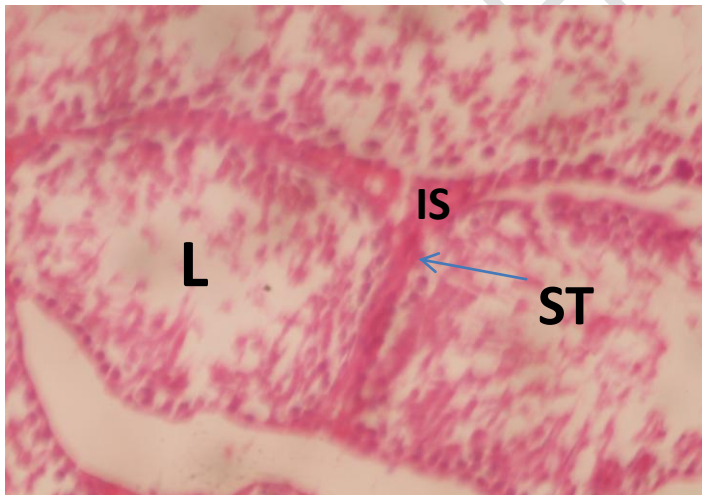

Plate 3: Representative histomicrograph of the Testis from group 3. H&E, MAG: 400X, DOSE: 3.0mg/kg Hgcl<sub>2</sub> + 100mg/kg PM Seed for 30 days. Treatment substance.mercury chloride and PM Seed. Some seminiferous tubules (ST) of the testis. There was slight desquamation of luminal (L) cell types. The interstitial (IS) cells of leydig were slightly distorted.

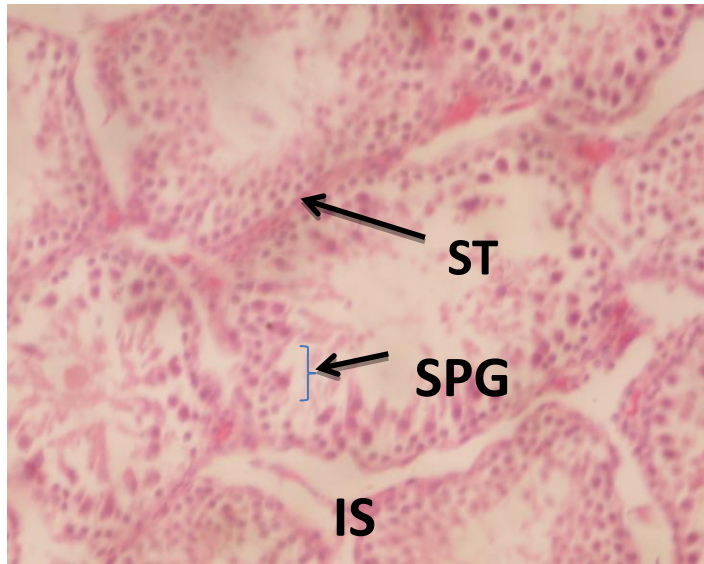


Plate 4: Histomicrograph of the Testis from group 4. H&E, MAG: 400X, dose: 3.0mg/kg Hgcl<sub>2</sub> + 200mg/kg PM Seed for 30 days. Treatment substance. mercury chloride and pm Seed. Normal seminiferous tubules (ST) of the testis with slight degeneration of interstitial (IS) cells. The spermatogonia (SPG) cells were intact with slight desquamation of cell types.

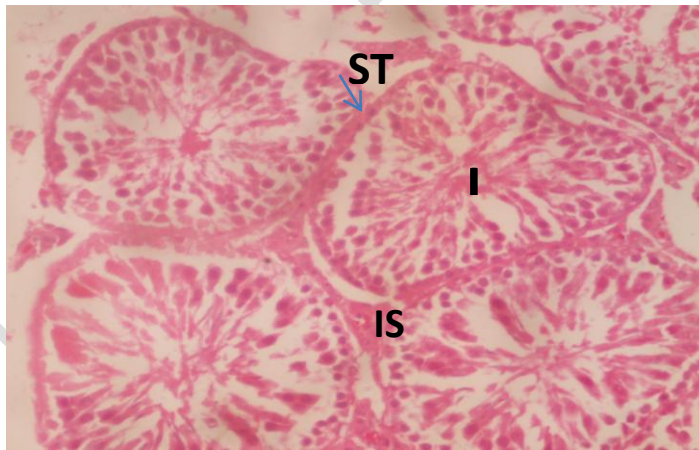


Plate 5: Photomicrograph of the section of the Testis from group 6. H&E, MAG: 400X, dose: 200mg/kg PM Seed alone for 30 days. Treatment substance. *Pentaclethra macrophylla* Seed. Normal histoarchitecture of the testis with moderate seminiferous tubules (ST). The interstitial (IS) cells of leydig were intact. The Luminal (L) cell types were intact and well outlined.

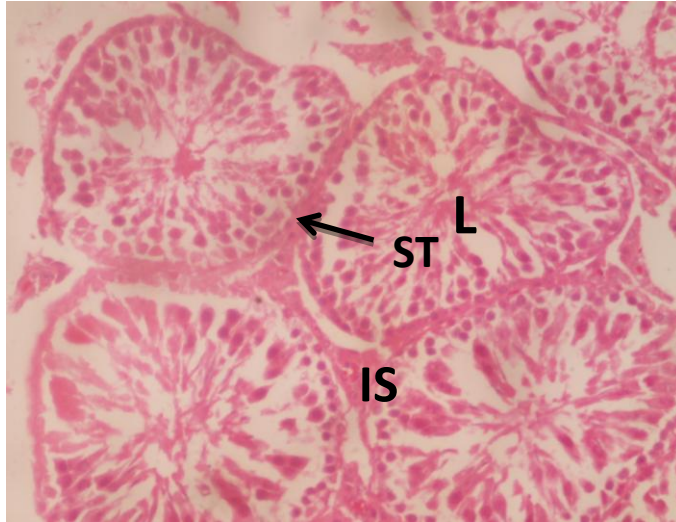


Plate 6: Representative histomicrograph of the Testis from group 5. H&E, MAG: 400X, dose: 100mg/kg PM Seed alone for 30 days. Treatment substance. *Pentaclethramacrophylla* Seed. A normal cytoarchitecture of the testis with moderate seminiferous tubules (ST). The interstitial (IS) cells of leydig were normal. The Luminal (L) cell types were intact and well

### Discussion

In this study, the results showed that the reduction in percentage sperm viability in group 2 rats reached significant level. This could be attributed to mercury intoxication to testicular cells and tissues, probably resulting to generation of free radicals and reactive oxygen species, causing damage and malfunction of the testis. This corresponds with the findings of some research teams who reported that mercury compounds are known to affect testicular spermatogenic and steroidogenic functions in human and experimental models [2,6]. The elevation in percentage sperm viability in PM seed treated groups 3 & 4 rats (Table 1) was significant and could be because of great ameliorative potentials of PM seed extract to testicular cells and tissues. The percentage sperm viability in groups 5 & 6 (Table 1) rats were strongly enhanced at the end of the experiment.

The elevation in percentage abnormal sperm morphology in group 2 rats (Table 1) reached significant level and could be due to mercury intoxication to testicular cells and tissues, provoking lipid peroxidation and oxidative stress, leading to increased seminal disorders and abnormal spermatogenesis. This tallied with previous submissions by some research teams who discovered that administration of mercury has been documented to promote impairment of testicular function as evidenced by pathological alterations of the testis and markers of reproductive viability such as, sperm quality variables, androgen, and testicular architectures [2,3,5]. There was significant decrease in percentage abnormal sperm morphology (Table 1) in PM seed treated groups 3 & 4 rats. This could be because of wonderful ameliorative potential exhibited by PM seed extract on testicular cells and tissues. The percentage abnormal sperm morphology in groups 5 & 6 rats were further reduced at the end of the experiment.

The reduction in percentage sperm motility in group 2 (Table 2) rats reached significant level and could be attributed to mercury intoxication to testicular cells and tissues precipitating generation of free radicals and reactive oxygen species (ROS), resulting to dysfunction of the testis. This agrees with the discovery of Rao and Sharma [5] who reported decrements in serum testosterone, sperm count, motility, viability, vitality and viability in mercury exposed rats and mice.

The elevation in percentage sperm motility in PM seed treated groups 3 & 4 rats (Table 2) reached significant level and could be because of great ameliorative potential of PM seed extract on testicular cells and tissues. The percentage sperm motility in groups 5 & 6 animals (Table 2) were maintained and enhanced at the end of the experiment.

The elevation in percentage dead sperm cells in group 2 (Table 2) rats reached significant level. This could be attributed to mercury intoxication to testicular cells and tissues through oxidative stress and lipid peroxidation mechanisms, leading to increased destruction of spermatozoa and their eventual death. This corresponds with the report of Mahboob and his team [14] that mercuric chloride induces biological toxicity in the testis, and other tissues of experimental animals through oxidative stress and lipid peroxidation mechanisms. The significant reduction in percentage dead sperm cells in PM seed treated groups 3 & 4 rats (Table 2) could be due to great ameliorative potentials of PM seed extract to testicular cells and tissues. The percentage dead sperm in groups 5 & 6 rats (Table 2) where only PM seed extract was administered at different concentrations were reasonably minimized by PM seed extract.

There was no statistically significant decrease in testosterone concentration in group 2 rats. This could be that mercury chloride did not exert significant effect on testosterone concentration. The increase in testosterone concentration in groups 3 & 4 rats did not reach statistically significant levels. This could mean that *Pentaclethra macrophylla* seed did not have reasonable impact on increasing testosterone levels in treated groups 3 & 4 rats.

The significant reduction in sperm count in group 2 rats could be due to mercury intoxication to testicular cells and tissues. Decrements in sperm count, motility, vitality, and viability in mercury exposed rats and mice have been reported [5]. Abarikwu and his team [2], and Martinez and his team [6] agreed with my finding in their report on mercury intoxication which they ascertained that mercury intoxication promotes androgen deficiency and reduces secretory epididymal components necessary for sperm maturation. The significant elevation in sperm count in PM seed treated groups 3 & 4 rats (Table 3) could be because of amelioration influence of PM seed extract on testis. The sperm count in groups 5 & 6 rats (Table 3) were enhanced and maintained to near normal levels at the end of the experiment. Plate 1 represents the histomicrograph of the testis from group 4 (3.0mg/kg Hgcl + 200mg/kg PM seed). Normal seminiferous tubules of the testis with slight degeneration of interstitial cells. The spermatogonia cells were intact with slight desquamation of cell types. Plate 2 is the representative histomicrograph of the testis from group 5 (100mg/kg PM seed alone). A normal cytoarchitecture of the Testis with moderate seminiferous tubules. The interstitial cells of Leydig were normal. The luminal cell types were intact and well outlined. Plate 3 represents the photomicrograph of the section of the Testis from group 6 (200mg/kg PM seed alone). Normal histoarchitecture of the Testis with moderate seminiferous tubules. The interstitial cells of Leydig were intact. The luminal cell types were intact and well outlined. In group 2 rats (Plate 2), the luminal spermatogonia cell arrangement was distorted with degenerated cell types. This could be attributed to mercury toxicity to testicular cells and tissues. Administration of mercury has been documented to provoke impairment of testicular function as evidenced by pathological alterations of the testis and markers of reproductive viability, such as, sperm quality variables, androgen, and testicular architecture [2,3,5]. In PM seed treated groups 3 & 4 rats (Plates 3 & 4), slight desquamation of luminal cell types with slight degeneration of interstitial cells were observed. However, spermatogonia cells, some tubules, and sustentacular cells were all intact, demonstrating great ameliorative potentials exhibited by PM seed extract to testicular tissues and cells. In groups 5 & 6 rats, a normal histoarchitecture of the testis was observed. Also, the interstitial cells of Leydig, connective tissues and sustentacular cells were intact and normal at the end of the experiment.

#### 4. CONCLUSION

Induction with mercury caused a reduction in testosterone levels and poor sperm quality index (motility, count & viability), but were significantly improved after treating with PM.

#### Ethical Approval

Animal Ethic committee approval has been taken to carry out this study.

#### REFERENCES

1. Rafati-Rahimzadeh, M., Kazemi, S., & Moghadamnia, A. A. Current approaches of the management of mercury poisoning: need of the hour. *Daru Journal of Pharmaceutical Sciences*, 2014; 22(1), 46-57.
2. Abarikwu, S. O., Benjamin, S., Ebah, S. G., Obilor, G., & Agbam, G. Oral administration of Moringa oleifera oil but not coconut oil prevents mercury-induced testicular toxicity in rats. *Andrologia*, 2017; 49(1), e12597.
3. Sener, G. O., Sehirlı, A., Tozan, A., Velioglu – Ovunc, N., Gedik, & Omurtag, G. Ginkgo biloba extract protects against mercury (II) chloride – induced oxidative tissue damage in rats. *Food and Chemical Toxicology*, 2007; 45, 543 – 50.
4. Abarikwu, S. O., Njoku, R. C. C., & Onuah, C. L. Aged coconut oil with a high peroxide value induces oxidative stress and tissue damage in mercury-treated rats. *Journal of Basic and Clinical Physiology and Pharmacology*, 2018; 29(4): 365-76.
5. Rao, M.V. & Sharma, P.S.N. Protective effect of vitamin E against mercury chloride reproductive toxicity in male mice. *Reproductive Toxicology*, 2001; 15(16): 705 – 12.
6. Martinez, C. S., Peçanha, F. M., Brum, D. S., Santos, F. W., Franco, J. L., Zemolin, A. P. P., & Vassallo, D. V. Reproductive dysfunction after mercury exposure at low levels: evidence for a role of glutathione peroxidase (GPx) 1 and GPx4 in male rats. *Reproduction, Fertility and Development*, 2017; 29(9): 1803-12.
7. Osabor, V. N., Okonkwo, P. C., & Ikeuba, A. I. Chemical profile of leaves and seeds of Pentaclethra macrophylla Benth. *Journal of Medicinal plant and Herbal Therapy Research*, 2017; 5: 11 – 17.
8. Sonmez, M., Turk, G., & Yuce A. The effect of ascorbic acid supplementation on sperm quality, lipid peroxidation and testosterone levels of male Wistar rats. *Theriogenology*, 2005; 63(7): 2063 – 72.
9. Wyrobek A.J., & Bruce, W.R. The induction of sperm shape abnormalities in mice and human. In: Hollander A, de Serres FJ (eds) Chemical mutagens (vol 5, pp 257–287), Plenum Press, New York. 1980.
10. Bloom, E. The ultrastructure of some characteristic sperm defects. Nord, *Veterinary Medicine*, 1973; 25: 283-94
11. Pant, N., & Srivastava, S. P. Testicular and spermatotoxic effects of quinalphos in rats, *Journal of Applied Toxicology: An International Journal*, 2003; 23(4): 271–4.
12. Robb, G. W., Amann, R. P., & Killian, G. J. Daily sperm production and epididymal sperm reserves of pubertal and adult rats. *Reproduction*, 1978; 54(1): 103-7.
13. Drury, R. A. B., & Wallington, E. A. Preparation, and fixation of tissues. *Carleton's Histological Technique*, 1980; 5: 41-54.
14. Mahboob, M., Shireen, K. F., Atkinson, A. & Khan, A. T. Lipid different organs of mice exposed to low level of mercury. *Journal of Environmental Science and Health*, 2001; 36: 687 – 97.

UNDER PEER REVIEW