

DIAGNOSIS ABOUT GRAPHITE TATTOO:AN EXCISIONAL BIOPSY ASSAY

Abstract:

Amalgam tattoos and graphite tattoos are the most commonly seen lesions of exogenous origin. Graphite tattoos mainly result from accidental injury from the tip of the pencil being inserted into the oral mucosa. A 4-year-old male patient reported to the department for evaluation of pigmentation present in the left hard palate. The patient's mother gave a history of trauma. The graphite particles may be randomly distributed in the connective tissue or around vessels and along fibers. However, the particles are not selective for vessels, nerves, collagen fibers, or the basement membrane. We report a rare case of graphite tattoo in a 4-year-old child. Excisional biopsy of the lesion was performed to provide a definitive diagnosis, prevent discomfort, and avoid any future complications.

Keywords: Amalgam tattoos, collagen fibers, Physiologic pigmentation, metallic silver

INTRODUCTION

Oral pigmented lesions are commonly noted in clinical practice. The presence of pigmentations in abnormal amounts and/or locations leads to these lesions.¹ Pigmentation may be either endogenous or exogenous in origin.² It may also be physiologic or non-physiologic in nature.

Physiologic pigmentation results from melanin production. Non-physiologic pigmentation can either be pathologic or non-pathologic. Localized, non-physiologic, pathologic pigmented lesions include hemangiomas, Kaposi's sarcoma, and melanoma.³ In the oral mucosa, localized, non-physiologic pigmentations are usually due to exogenous sources such as implanted materials. The exogenous sources may include carbon, iron dust, metallic silver (amalgam tattoos) or graphite.¹

Amalgam tattoos and graphite tattoos are the most commonly seen lesions of exogenous origin. Graphite tattoos mainly result from accidental injury from the tip of the pencil

being inserted into the oral mucosa. In our search, very few cases of graphite tattoos have been reported in literature. Consequently, here we report a rare case of graphite tattoo in a child.

CASE REPORT

A 4-year-old male patient reported to the department for evaluation of pigmentation present in the left hard palate. The patient's mother gave a history of trauma. The patient accidentally inserted the lead of a pencil into his palate. After the incident, patient was taken to a nearby hospital for first-aid. Bleeding was controlled as the first aid measure. The pigmentation in the palate was noticed and three days after the trauma, the patient reported to the department.

On examination, a grayish-black macule was noticed on the posterior hard palate approximately 5mm from mid-palatal suture. The macule was present 1cm medial to tooth number 65 and just anterior to junction of hard palate and soft palate. The macule was asymptomatic. No other lacerations or injuries were noticed. On palpation the affected region was tender, hard, non-fluctuant, and firm. The provisional diagnosis was rendered to be graphite tattoo.

An excisional biopsy was performed. After the surgical removal of the lesion, the specimen was of 0.2cmx0.2cmx0.5cm in dimension. A solid black mass was observed inside the soft tissue. The black mass resembled a piece of graphite. The specimen was then fixed in 10% formalin and sent for histopathological examination.

Histopathology revealed sections of parakeratinized stratified squamous epithelium. The underlying connective tissue showed dense fibrous areas of granular black foreign deposits, proliferating fibroblasts and mild inflammatory infiltrate. On corroborating histopathological findings with the clinical findings and elicited history, the diagnosis of graphite tattoo was confirmed.

DISCUSSION

Graphite is a naturally occurring or synthetically made crystalline form of carbon.³ In pencils, clay rich in silica is added to the graphite.⁴ Graphite pencils are capable of causing traumatic injury and foreign body reaction. Injuries occur due to introduction of pencil into oral mucosa especially during early childhood.⁵

In our search, we did not come across any reports of graphite tattoo present in the palate of a child. The reports we found are described in Table 1.^{2,3,5,6} Although a limited number of cases have been documented, it is presumed that these injuries occur frequently than they have been reported.⁷

Graphite tattoo typically appears as an irregular gray to black macule usually in hard palate. It is predominantly seen in women and in younger age groups (5-21 years). The most commonly affected sites are gingiva and palate. The size generally ranges from 1 to 15 mm.^{3,5,6}

Diagnosis of graphite tattoo can be confirmed based on history, radiography, histology, Energy-Dispersive X-Ray Spectroscopy (EDS), and scanning electron microscope (SEM).² A history of injury could confirm the diagnosis of a foreign-body lesion.^{2,3,8} Periapical or soft tissue radiographs of graphite tattoo may reveal pinpoint radiopacities.⁹ However, biopsy is mandatory to rule out similarly appearing lesions melanocytic nevus, blue nevus, and melanoma, or for esthetic reasons. The biopsy allows for a definitive diagnosis.¹

Histologically, the graphite particles may be randomly distributed in the connective tissue or around vessels and along fibers. However, the particles are not selective for vessels, nerves, collagen fibers, or the basement membrane.⁴ Inflammation may be present. Chronic inflammatory response with formation of foreign body granulomas exhibiting the presence of multinucleated giant cells might be identified.^{3,5,6} Other investigations include: EDS and SEM. EDS shows the presence of a larger quantities of carbon and silica.⁴ SEM analysis depicts more irregular and larger granules of graphite.²

Graphite tattoos are harmless in nature. Therefore, removal of the lesion is not mandatory. Excision may be performed for esthetic purposes.³ However, literature does report that pencil lead may lead to foreign body granuloma. Swelling and tenderness may occur with lag periods of five or more years.¹⁰

In conclusion, we report a rare case of graphite tattoo in a 4-year-old child. Excisional biopsy of the lesion was performed to provide a definitive diagnosis, prevent discomfort, and avoid any future complications.

Table 1: Reports of graphite tattoo till date^{2,3,5,6}

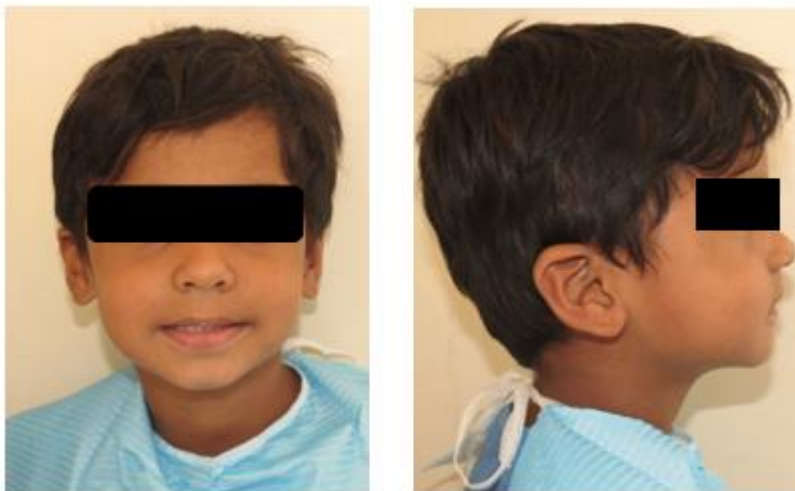Authors	Year	Age of Patient	Gender of patient	Location of graphite tattoo	Treatment
Anderegg and Lyles	1992	21 years	F	Attached gingiva	Biopsy
Phillips and John	2005	17 years	F	Interdental papilla	Biopsy+ Subepithelial Connective Tissue Graft
Rihani and Da'ameh	2006	5 years	F	Attached gingiva	Biopsy
Renata MendonçaMoraes	2015	62 years	F	Palate	Biopsy

References

1. Molini PR, Velloso TR, Silva DN, Bertollo RM, de Azevedo SL, Pereira TC, de Barros LA. Pigmented lesion in hard palate: a graphite tattoo. *Journal of Oral Diagnosis*. 2016;1(1)
2. Moraes RM, Gouvêa Lima GD, Guilhermino M, Vieira MS, Carvalho YR, Anbinder AL. Graphite oral tattoo: case report. *Dermatology online journal*. 2015;21(10).
3. Phillips GE, John V. Use of a subepithelial connective tissue graft to treat an area pigmented with graphite. *Journal of periodontology*. 2005 Sep;76(9):1572-5.
4. Peters E, Gardner DG. A method of distinguishing between amalgam and graphite in tissue. *Oral Surgery Oral Medicine Oral Pathology Oral Radiology and Endodontics* 1986; 62: 73-6. [PMID: 3523365]
5. Rihani F B, Da'ameh D M. Intraoral graphite tattoo. *Arch Dis Child* 2006; 91:563.
6. Anderegg CR, Lyles MB. Graphite tattoo - report of a case and differential-diagnosis. *Military Medicine* 1992; 157: 323- 4. [PMID: 1620404]
7. Neville B W, Damm D D, Allen C M, Bouquot J E. *Oral and Maxillofacial Pathology*. 3rd ed. Toronto: W.B Saunders Company; 2009.
8. Kauzman A, Pavone M, Blanas N, Bradley G. Pigmented lesions of the oral cavity: review, differential diagnosis, and case presentations. *J Can Dent Assoc* 2004; 70:682-683.

9. Flaitz CM, McCandless G. Palatal blue nevus in a child. *Pediatric dentistry*. 2001 Jul 1;23(4):354-5.
10. Terasawa N, Kishimoto S, Kibe Y, Takenaka H, Yasuno H. Graphite foreign body granuloma. *The British journal of dermatology*. 1999 Oct 1;141(4):774-6.

Fig 1 :Extra-Oral image



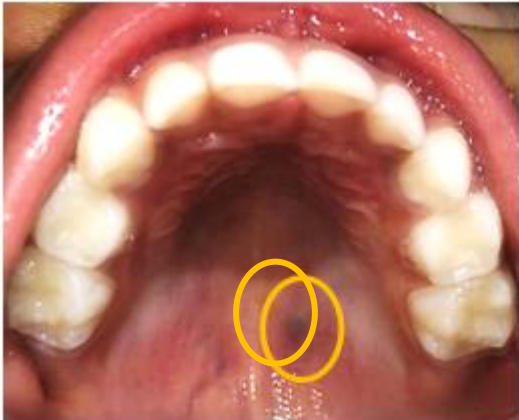

Fig 2 :Pre-Operative image

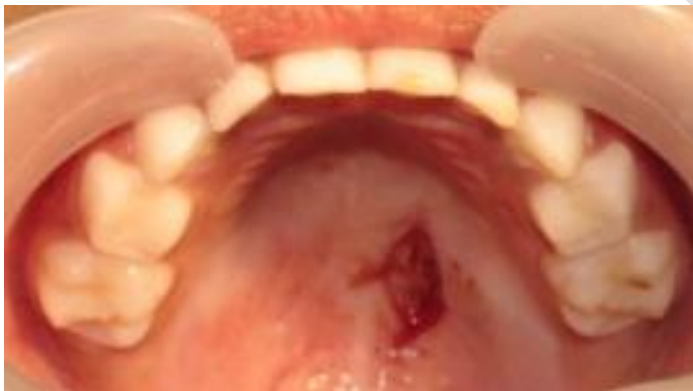

Fig 3 :Incision in the teeth

Fig 4 :Suture in the teeth

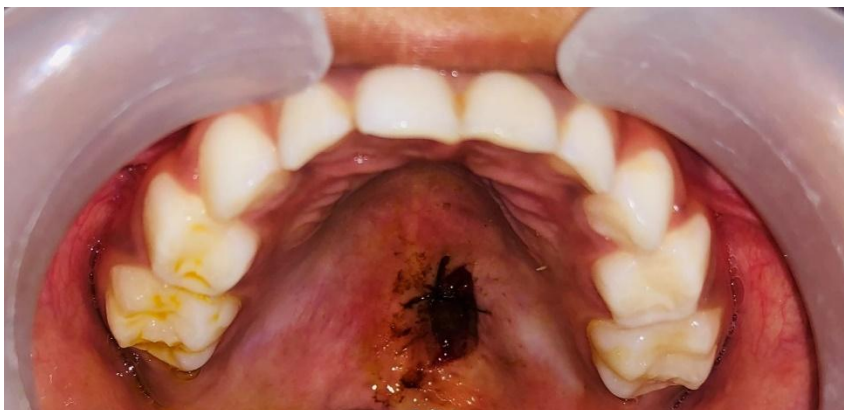

Fig 5 :Excised Foreign Body (Graphite)

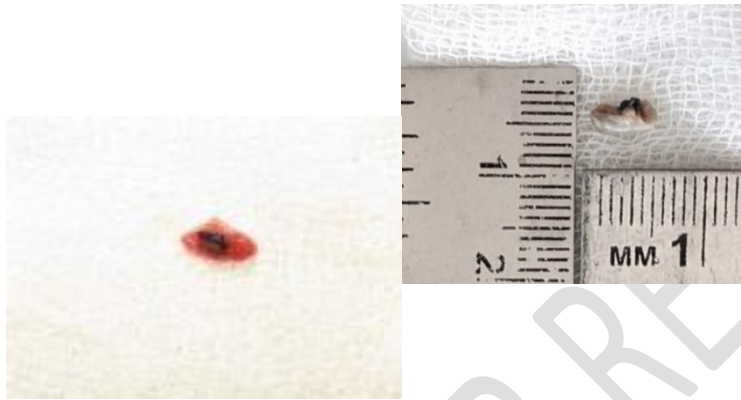


Fig 6 :Post-Operative Follow Up (Day 1)

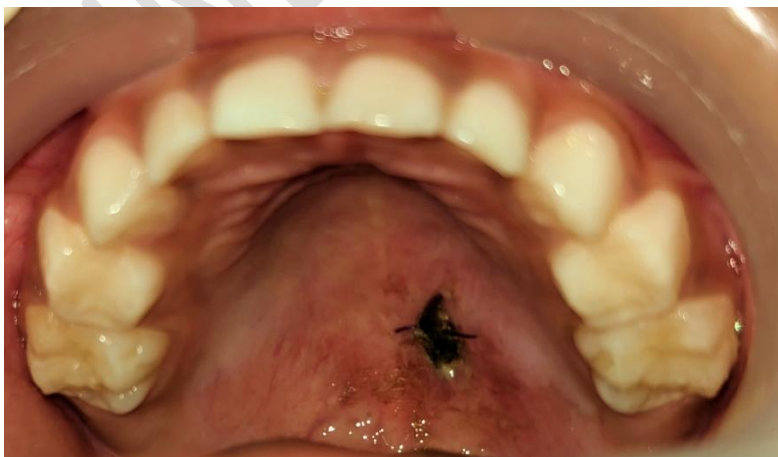
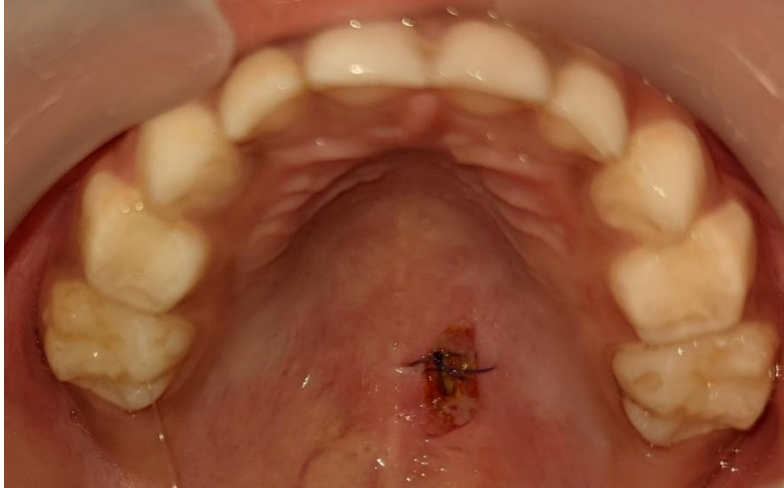
Fig 7 :Post-Operative Follow Up (Day 2)



1 WEEK

UNDER PEER REVIEW

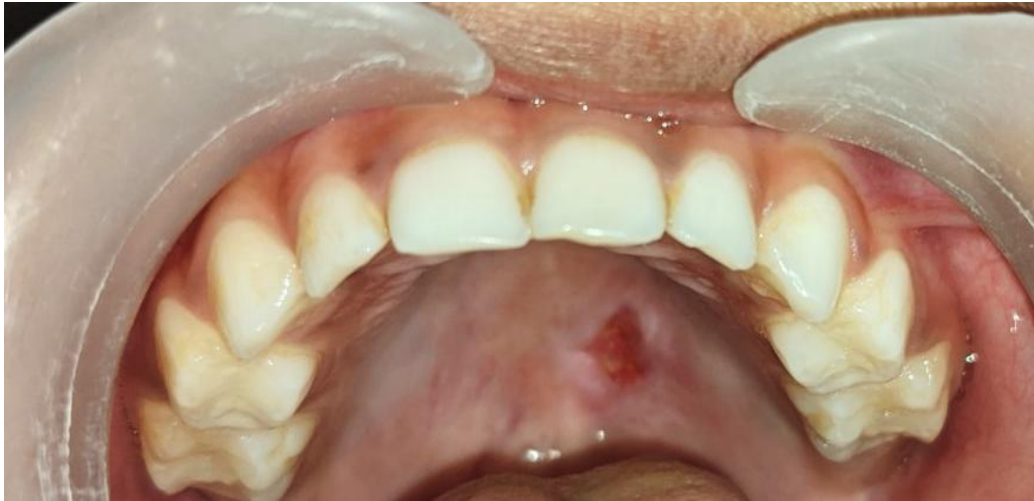

Fig 8 :Post-Operative Follow Up (1 week)

Fig 9 : Post-Operative Follow Up (6 months)

