

Case study

A UNIQUE CASE OF EMPHYSEMATOUS PYOMETRA AND UTERINE ADENOCARCINOMA CO-INCIDENCE IN A DOBERMAN FEMALE DOG

ABSTRACT

Emphysematous pyometra is one of the rare, life-threatening illnesses noted in intact female dogs, which is characterized by accumulation of infectious exudate along with gas filled endometrium. The present report describes a rare case of two medical conditions that occurred simultaneously in a female Doberman pinscher. The first condition is emphysematous pyometra, which is a severe infection of the uterus with the presence of gas pockets. The second condition is uterine adenocarcinoma, which is a type of cancer that develops in the lining of the uterus. The co-occurrence of these two conditions is uncommon and represents a significant medical challenge in terms of diagnosis and treatment. The report discusses the symptoms, diagnostic methods, treatment options and prognosis of the case.

Keywords: Doberman bitch, emphysematous pyometra, ovariohysterectomy, uterine adenocarcinoma

INTRODUCTION

Pyometra is the most common disease found in adult intact female dogs, caused by acute or chronic suppurative bacterial infection of the uterus and is characterized by accumulation of inflammatory exudates in the uterine lumen with diverse clinico-pathological manifestation either locally or systemically [8,13,15]. Disease is frequently noticed in adult female dog in luteal phase of estrous cycle during which progesterone level is high (progesterone sensitized uterus) and thus playing key role in pathogenesis [11]. Though many bacterial isolates are known to cause pyometra in nulliparous bitches, one of the rare, life threatening illness noted in female dogs is emphysematous pyometra, which is characterized by accumulation of infectious exudate along with gas filled endometrium [7,16]. In emphysematous pyometra, *Clostridium perfringens*, *Staphylococcus* spp., *Pseudomonas aeruginosa* and *Enterococcus avium* are believed to be the involved [4,7] and results in development of a bifurcating gas-filled tubular structure and distension of uterine horns. This disease is associated with wide range of clinical signs, which can even be life threatening if left untreated.

Further, development of uterine tumor more commonly reported in female dogs are leiomyomas; while fibroadenomas, lipomas and adenocarcinomas are less frequently reported [1,2,9]. Uterine tumor coexist with pyometra are very rarely seen in canine [3,14,17]. Clinical signs associated with uterine tumors depend on concurrent reproductive disease like endometrial hyperplasia, pyometra and metasis of tumor mass [3]. The presence of metastatic disease may influence the survival time of the patient. So, any proliferative lesion should be checked for further examination [2,3]. As the patient's condition rapidly gets deteriorated if not immediately taken into consideration, thus timely diagnosis and early intervention will

Comment [p1]: Divided it into 3 sections (background, aim of study, and conclusion)

Comment [p2]: The references should be written in sequences as it appear in the text

prevent disease progression and increases the chances of survival [4,5,18]. This is the first time to our knowledge a case of uterine adenocarcinoma along with emphysematous pyometra has been reported in an intact bitch.

History and Clinical Observation

Comment [p3]: Where is the ethical approval?

A four years old intact female Doberman was presented to Small Animal Obstetric and Gynaecological unit of Teaching Veterinary Clinical Complex, Madras Veterinary College, Chennai with the complaint of vomiting, poor general condition, vaginal discharge sticking to the tail hair and perineum and fatigue. On physical examination dog appear dull, depressed and mucopurulent discharge was noticed from vagina. Last estrus was noticed eight months back and not whelped before. Previous treatment details were unknown. Vital parameters show some deviation from normal parameter; Temperature was 104°F, Respiration shallow and deep, capillary refill time 3 sec and mild dehydration. Abdomen was distended and evinces pain on palpation. Lateral radiograph was taken which revealed gas filled tubular structure, distended uterine horns and displacement of colon. Ultrasonographic examination reveal tubular uterus with hyperechoic interface and mixed echogenicity of uterine contents suspected to be presence of gas in uterine lumen. Complete Blood Count (CBC) and biochemistry shows elevation in white blood cell count (neutrophilia > 25000 cells/mm³), elevated globulin (7.23 g/dl), thrombocytopenia (11000 per cmm) and hypoglycemia (45 mg/dl).

DIAGNOSIS AND TREATMENT

On the basis of history, physical examination, hematology and clinical observations, tentative diagnosis of open-cervix emphysematous pyometra was made. After diagnosis, the dog was treated with Amoxicillin and Cloxacillin @ 10 mg/kg I/V, Metronidazole @ 25 mg/kg I/V, Ondansetron @ 0.1 mg/kg slow I/V, Amikacin @ 20 mg/kg I/V, Pantoprazole @ 1 mg/kg I/V, Ringer's lactate solution @ 20 ml/kg I/V and Vitamin B complex @ 1.5 ml I/M. After three days of treatment, diagnostic reevaluation included CBC, chemistry panel, abdominal radiographs, and abdominal ultrasound was made. The WBC count remained elevated (30000 cells/mm³), blood glucose level normalized (107 mg/dl), Abdominal radiography revealed presence of thick tubular structure consistent with enlarged uterus (Fig. 1), thoracic radiograph shows normal cardiac silhouette and bronchial pattern (Fig. 2). Ultrasound examination showed irregular and hyperplastic endometrial wall with mixed echogenicity of uterine contents (Fig. 3). The condition of the patient appears poor and quick decision of explorative laparotomy was made. Ovariohysterectomy was performed with midline incision, which revealed an enlarged uterus with thick walls filled with mixed fluid and gas contents (Fig. 6). Grossly, mucosal surface was irregular with prominent folds and transmural thickening and multiple cysts filled with thick yellow fluid was noticed (Fig. 7). Uterine fluid sample was collected and subjected to bacterial culture, which shows presence of *Staphylococcus* spp. Uterine tissue sample was submitted for histopathological examination, which revealed thick endometrial folds, irregular shaped glands, presence of neoplastic cells and nuclear polymorphism which is characteristic of adenocarcinoma (Fig. 4&5). Thus,

confirmed a case of emphysematous pyometra coexisted with uterine adenocarcinoma. Post operatively patient was treated with broad spectrum antibiotics and supportive therapy for two weeks. Over the next several days, patient's appetite was improved and overall activity was normal. Four weeks following ovariohysterectomy, the patient was reevaluated for neoplastic metastasis. Abdominal ultrasound and thoracic radiography revealed no obvious abnormality in any organ and the bitch recovered uneventfully.

DISCUSSION

Pyometra is the major reproductive disorder in intact sexually mature bitches during diestrous phase (progesterone dominant phase) of oestrous cycle coupled with bacterial infection. Gas producing bacteria (*E.coli*, *Staphylococcus*, *Streptococcus* Spp.) are mainly responsible for causing emphysematous pyometra in bitch. Diagnostic evaluation continues to be ultrasonography and radiographic examination (4). Leucocytosis with a predominant absolute neutrophilia, lymphopenia and monocytosis were consistent findings in emphysematous pyometra (14). Along with pyometra, uterine adenocarcinoma is a concomittent finding and considered to be a rare condition seen in female dogs. Factors like age, endometrial hyperplasia, lymphovascular invasion, lymph node involvement and any sarcomatous growth actors can be used to accurately prognosticate for uterine adenosarcoma patients (13). However, in the present case, age, myometrial invasion and endometrial hyperplasia plays an important role for higher chances of occurrence of uterine tumor. Uterine adenocarcinoma may influence the survival time of the patient. So, it should be included in differential list when diagnosis diseases like pyometra. Simple atypical hyperplasia turns into cancer in about 8% of cases if it's not treated. Complex atypical hyperplasia (CAH) has a risk of becoming cancer in up to 29% of cases if it's not treated, and the risk of having an undetected endometrial cancer is even higher (12,13). Most endometrial cancer cells have estrogen and/or progesterone receptors on their surfaces and interaction of these receptors and hormones leads to increased growth of the endometrium. This increased growth can become more and more abnormal until it develops into a cancer. Successful management includes early diagnosis and timely intervention. Though the disorder can be managed by medical treatment (6), but the present case did not show complete recovery after treating medically which could be attributed to pus and gas along with tumour present in the uterine horns. Thus, ovariohysterectomy was performed and is the choice of treatment.

Comment [p4]: Check spelling

Comment [p5]: What is the limitation of this case study?

Comment [p6]: Where is the conclusion?

REFERENCES

1. Anderson C, Pratschke K. Uterine adenocarcinoma with abdominal metastases in an ovariohysterectomised female cat. *J Feline Med Surg* 13: 44-47. 2011.
2. Baldwin C, Roszel JF, Clark TP. Uterine adenocarcinoma in dogs. *Compend Contin Educ* 14: 731-737. 1992.
3. Cave TA, Hine R, Howie F, Thompson H, Argyle DJ. Uterine carcinoma in a 10- month-old golden retriever. *J Small Anim Pract* 43: 133-135. 2002.

4. Chang J, Jung J, Jeong Y, Hong K, Kim K, Yoon J, et al. What is your diagnosis? Emphysematous pyometra with a large amount of gas. *J Small Anim Pract.* 48: 717–719. 2007.
5. Chang AC, Cheng CC, Wang HC, Lee WM, Shyu CL, Lin CC, et al. Emphysematous pyometra secondary to *Enterococcus avium* infection in a dog. *Tierarztl Prax Ausg K Kleintiere Heimtiere.* 44: 195–9. 2016
6. Fieni F, Topie E, Gogny A. Medical Treatment for Pyometra in Dogs. *Reproduction of Domestic Animals.* 49(2): 28–32. 2014
7. Hernandez, Juan & Besso, J.G. & Rault, D.N. & Cohen, A.H. & Guionnet, A & Begon, D & Ruel, Yannick. Emphysematous pyometra in a dog. the official journal of the American College of Veterinary Radiology and the International Veterinary Radiology Association. 44: 196-8. 2003.
8. Johnston SD, Root Kustritz MV, Olson PNS. *Canine and Feline Theriogenology.* Philadelphia: WB Saunders Co. 168–224. 2001
9. Klein, m. K. Tumors of the female reproductive system. In: *Small Animal Clinical Oncology.* 3rd edn. Eds S. J. Withrow and E. G. MacEwen. W. B.Saunders, Philadelphia, PA, USA. 445-454. 2001
10. Mattei, C., Fabbi, M. & Hansson, K. Radiographic and ultrasonographic findings in a dog with emphysematous pyometra. *Acta Vet Scand* 60: 67. 2018.
11. Mateus L, Eilts BE. Cystic endometrial hyperplasia and pyometra. In: Ettinger SJ, Feldman EC, editors. *Textbook of veterinary internal medicine.* 7th ed. Philadelphia: Saunders Elsevier; 1913–21. 2009.
12. Michael J. Nathenson & Anthony P. Conley Prognostic factors for uterine adenocarcinoma: a review, *Expert Review of Anticancer Therapy*, 18: 11; 1093-1100. 2018.
13. Nelson RW, Feldman EC. Pyometra. *Veterinary Clinics of North America.* 16: 561–76. 1986.
14. Pires MA, Seixas F, Palmeira C, Payan-Carreira R. Histopathologic and immunohistochemical exam in one case of canine endometrial adenocarcinoma. *Reprod Domest Anim* 45: 545–549, 2010.
15. Ravishankar N, Manoharmurli B, Balchandran C, et al. Haemato-biochemical alterations and pathological changes in canine pyometra. *Ind J Vet Pathol.* 28(1): 14–17p.
16. Robert, S.J. Infertility in bitches and queens. *Veterinary Obstetrics and Genital Diseases.* 2nd edn., (CAB Publisher and Distributors, India,) 227-236. 2004.
17. Tsioli VG, Gouletsou PG, Loukopoulos P, Zavlaris M, Galatos AD. Uterine leiomyosarcoma and pyometra in a dog. *J Small Anim Pract.* 52(2): 121-4. 2011.
18. Thilagar S, Vinita WP, Heng HG, Aisah S, Khairani-Bejo S. What is your diagnosis? Small intestinal and colonic obstruction; emphysematous pyometra. *J Small Anim Pract.* 47: 687–8. 2006.

Comment [p7]: Where is the year?

FIGURES

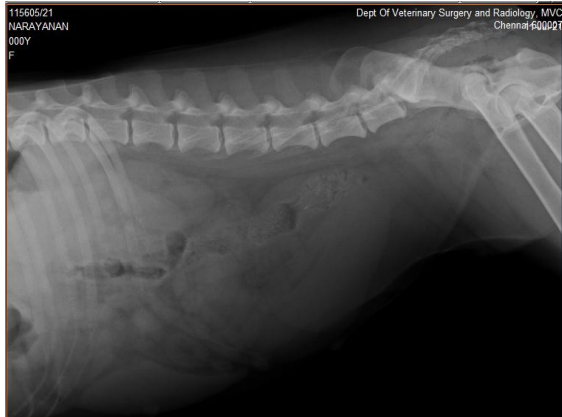

Fig. 1. Uterus noticed as tubular, distended uterine horns and displacement of colon

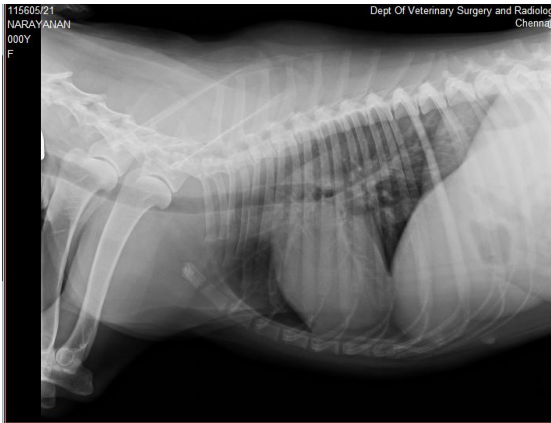


Fig. 2. Normal cardiac silhouette, bronchial pattern (tram lines) noticed.

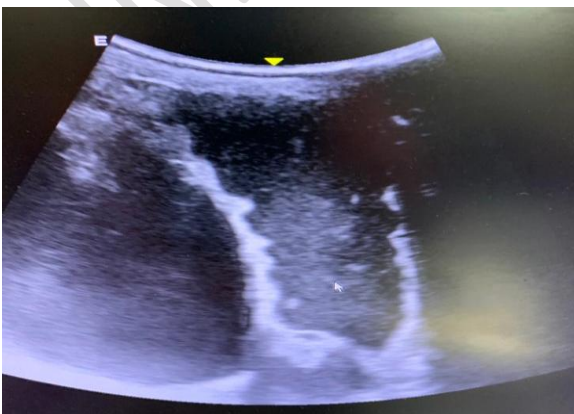


Fig. 3. Multiple cysts, thickening of uterine wall and mixed echogenicity of uterine contents

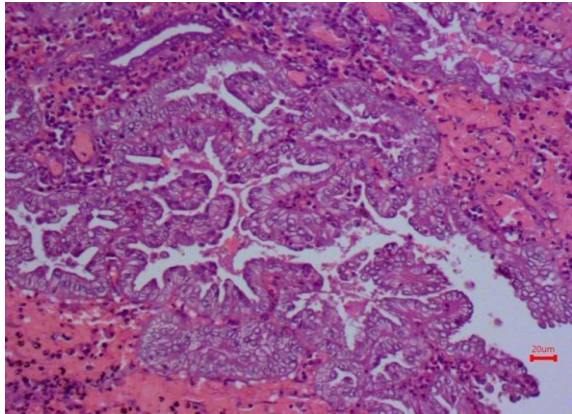


Fig. 4. Marked nuclear pleomorphism and solid growth pattern; the endometrium has prominent folds of neoplastic epithelial cells. Cystic lumens are plugged with neutrophils. H&E

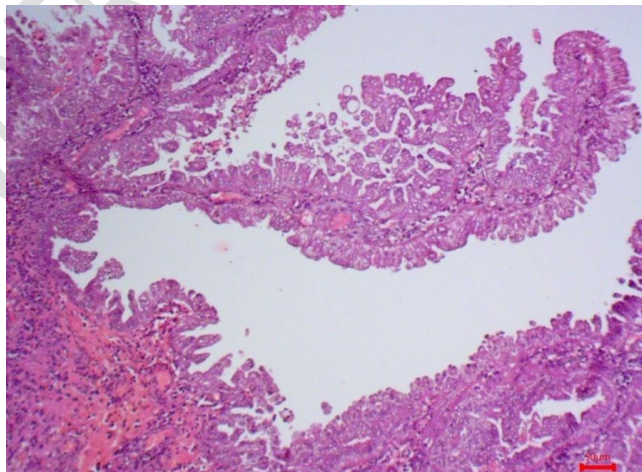


Fig. 5. Irregular shaped glands. Nuclei demonstrate pleomorphism

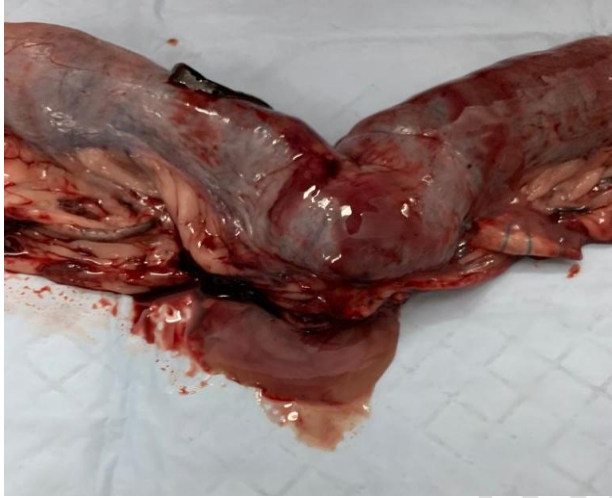

Fig 6; Post-surgical gross appearance of the uterus. Uterine horns thin-walled, distended and fluctuant due to the gaseous and liquid content

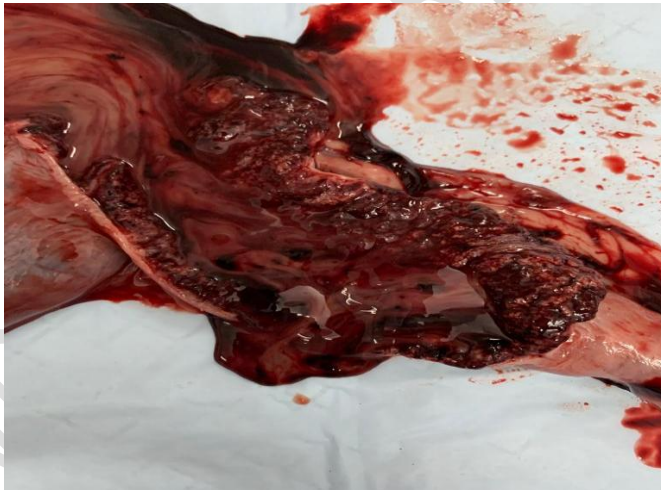

Fig 7; Multiple cysts noticed on the uterine wall and presence of gas and liquid contents in uterus.