

A UNIQUE CASE OF EMPHYSEMATOUS PYOMETRA AND UTERINE ADENOCARCINOMA CO-INCIDENCE IN A DOBERMAN FEMALE DOG

ABSTRACT

Background

Emphysematous pyometra is a rare and potentially life-threatening condition observed in intact female dogs, characterized by the accumulation of infectious exudate within the uterus and accompanied by the presence of gas. This report highlights an exceptional case where two distinct medical conditions manifested concurrently in a female Doberman pinscher – the coexistence of emphysematous pyometra and uterine adenocarcinoma. This juxtaposition not only creates an uncommon clinical scenario but also introduces complex challenges in terms of effective clinical management and therapeutic decision-making.

Case presentation

In this current case, a 4-year-old Doberman female dog underwent an ovariohysterectomy due to advanced purulent uterine infection. Upon gross examination, the uterine horns displayed distension and contained a mixture of fluid and gas. A uterine tissue sample was submitted for histopathological analysis, which unveiled thickened endometrial folds and the presence of neoplastic cells. Both gross and histopathological features confirmed the presence of emphysematous pyometra and uterine adenocarcinoma.

Conclusion

To the best of the authors' knowledge, this represents a novel case of concurrent emphysematous pyometra and uterine adenocarcinoma reported in canines. The extraordinary rarity of encountering both conditions simultaneously underscores the importance of thorough veterinary diagnostic protocols and prompt therapeutic interventions.

Keywords: Doberman bitch, emphysematous pyometra, ovariohysterectomy, uterine adenocarcinoma

1. BACKGROUND

Pyometra is the most common disease found in adult intact female dogs, caused by acute or chronic suppurative bacterial infection of the uterus and is characterized by accumulation of inflammatory exudates in the uterine lumen with diverse ~~clinical~~ clinical-pathological/clinicopathological manifestation either locally or systemically [1-4]. ~~Disease~~ The disease is frequently noticed in adult female ~~dog dogs~~ in the luteal phase of the estrous cycle during which progesterone level is high (~~progesterone sensitized~~ progesterone-sensitized uterus) and thus ~~playing~~ plays a key role in pathogenesis [5]. Though many bacterial isolates are known to cause pyometra in nulliparous bitches, one of the rare, ~~life-threatening~~ life-threatening illness noted in female dogs is emphysematous pyometra, which is characterized by ~~the~~ accumulation of infectious exudate along with ~~gas-filled~~ gas-filled

endometrium [6,7]. In emphysematous pyometra, *Clostridium perfringens*, *Staphylococcus* spp., *Pseudomonas aeruginosa*, and *Enterococcus avium* are believed to be ~~the~~ involved [6,8] and results in the development of a bifurcating gas-filled tubular structure and distension of uterine horns. This disease is associated with a wide range of clinical signs, which can even be ~~life-threatening~~ life-threatening if left untreated.

Further, the development of uterine ~~tumor~~ tumors more commonly reported in female dogs are leiomyomas; while fibroadenomas, lipomas, and adenocarcinomas are less frequently reported [1,2,9]. Uterine ~~tumor~~ tumors coexist with pyometra and are very rarely seen in ~~canine~~ canines [12-14]. Clinical signs associated with uterine tumors depend on concurrent reproductive ~~disease~~ diseases like endometrial hyperplasia, pyometra, and metastasis of tumor mass [12]. The presence of metastatic disease may influence the survival time of the patient. So, any proliferative lesion should be checked for further examination [10,12]. As the patient's condition rapidly gets ~~deteriorated~~ deteriorates if not immediately taken into consideration, thus timely diagnosis and early intervention will prevent disease progression and increases the chances of survival [8,16,17]. This is the first time to our knowledge a case of uterine adenocarcinoma along with emphysematous pyometra has been reported in an intact bitch.

2. CASE PRESENTATION

A four years old intact female Doberman was presented to the Small Animal Obstetric and Gynaecological unit of Teaching Veterinary Clinical Complex, Madras Veterinary College, Chennai with the complaint of vomiting, poor general condition, vaginal discharge sticking to the tail hair and perineum, and fatigue. On physical examination dog appear dull, and depressed, and mucopurulent discharge was noticed from the vagina. ~~Last~~ The last estrus was noticed eight months back and not whelped before. Previous treatment details were unknown. Vital parameters show some deviation from normal ~~parameter~~ parameters; Temperature was 104°F, Respiration shallow and deep, capillary refill time 3 sec, and mild dehydration. ~~Abdomen~~ The abdomen was distended and ~~evince~~ evinced pain on palpation. ~~Lateral~~ The lateral radiograph was taken which revealed ~~gas-filled~~ gas-filled tubular structure, distended uterine horns, and displacement of the colon. Ultrasonographic examination ~~reveal~~ revealed a tubular uterus with the hyperechoic interface and mixed ~~echogeneicity~~ echogenicity of uterine contents suspected to be the presence of gas in the uterine lumen. Complete Blood Count (CBC) and biochemistry ~~shows~~ show elevation in white blood cell count (neutrophilia > 25000 cells/mm³), elevated globulin (7.23 g/dl), thrombocytopenia (11000 per cmm), and hypoglycemia (45 mg/dl).

Comment [21]: ???

Diagnosis and treatment

On the basis of history, physical examination, hematology, and clinical observations, a tentative diagnosis of open-cervix emphysematous pyometra was made. After diagnosis, the dog was treated with Amoxicillin and Cloxacillin @ 10 mg/kg I/V, Metronidazole @ 25 mg/kg I/V, Ondansetron @ 0.1 mg/kg ~~kg~~ I/V, Amikacin @ 20 mg/kg I/V, Pantoprazole @ 1 mg/kg I/V, Ringer's lactate solution @ 20 ml/kg I/V and Vitamin B complex @ 1.5 ml

I/M. After three days of treatment, diagnostic reevaluation included CBC, chemistry panel, abdominal radiographs, and abdominal ultrasound was made. The WBC count remained elevated (30000 cells/mm³), blood glucose level normalized (107 mg/dl), Abdominal radiography revealed the presence of a thick tubular structure consistent with an enlarged uterus (Fig. 1), thoracic radiograph shows normal cardiac silhouette and bronchial pattern (Fig. 2). Ultrasound examination showed an irregular and hyperplastic endometrial wall with mixed ~~echogenicity~~ echogenicity of uterine contents (Fig. 3). The condition of the patient appears poor and quick decision of explorative laparotomy was made. Ovariohysterectomy was performed with a midline incision, which revealed an enlarged uterus with thick walls filled with mixed fluid and gas contents (Fig. 6). Grossly, the mucosal surface was irregular with prominent folds and ~~transmural~~ transmural thickening and multiple cysts filled with thick yellow fluid was noticed (Fig. 7). Uterine fluid sample was collected and subjected to bacterial culture, which shows the presence of Staphylococcus spp. ~~Uterine~~ The uterine tissue sample was submitted for histopathological examination, which revealed thick endometrial folds, ~~irregular~~ irregularly shaped glands, the presence of neoplastic cells, and nuclear polymorphism which is characteristic of adenocarcinoma (Fig.4,5). Thus, confirmed a case of emphysematous pyometra coexisted with uterine adenocarcinoma. ~~Postoperatively~~ Postoperatively patient was treated with ~~broad-spectrum~~ broad-spectrum antibiotics and supportive therapy for two weeks. Over the next several days, the patient's appetite was improved and overall activity was normal. Four weeks following the ovariohysterectomy, the patient was reevaluated for neoplastic metastasis. Abdominal ultrasound and thoracic radiography revealed no obvious abnormality in any organ and the bitch recovered uneventfully.

3. DISCUSSION

Pyometra is the major reproductive disorder in intact sexually mature bitches during the diestrus phase (progesterone dominant phase) of the oestrous cycle coupled with a bacterial infection. ~~Gas~~ Gas-producing bacteria (*E.coli*, *Staphylococcus*, *Streptococcus* ~~Spp~~ spp) are mainly responsible for causing emphysematous pyometra in bitch. Diagnostic evaluation continues to be ultrasonography and radiographic examination [8,17]. Leucocytosis with a predominant absolute neutrophilia, lymphopenia, and monocytosis were consistent findings in emphysematous pyometra [13]. Along with pyometra, uterine adenocarcinoma is a concomitant finding and is considered to be a rare condition seen in female dogs. Factors like age, endometrial hyperplasia, lymphovascular invasion, lymph node involvement, and any sarcomatous growth factors can be used to accurately prognosticate ~~for~~ uterine adenocarcinoma patients [2]. However, in the present case, age, myometrial invasion, and endometrial hyperplasia ~~plays~~ play an important role ~~for~~ in higher chances of occurrence of uterine ~~tumor~~ tumors. Uterine adenocarcinoma may influence the survival time of the patient. So, it should be included in the differential list when ~~diagnosis~~ diagnosing diseases like pyometra. Simple atypical hyperplasia turns into cancer in about 8% of cases if ~~it's~~ not treated. Complex atypical hyperplasia (CAH) has a risk of becoming cancer in up to 29% of cases if it's not treated, and the risk of having ~~an~~ undetected endometrial cancer is even higher [2,18]. Most endometrial cancer cells have estrogen and/or progesterone receptors on

their surfaces and interaction of these receptors and hormones leads to increased growth of the endometrium. This increased growth can become more and more abnormal until it develops into a cancer. Successful management includes early diagnosis and timely intervention. Though the disorder can be managed by medical treatment [19], but the present case did not show complete recovery after treating medically which could be attributed to pus and gas along with ~~the~~ tumors present in the uterine horns. Thus, ovariohysterectomy was performed and is the choice of treatment. The limitations of the study include the presentation of a single case, which might not fully capture the range of possible variations in the occurrence and characteristics of emphysematous pyometra with concurrent uterine adenocarcinoma in female dogs. Further research involving a larger sample size and comprehensive data collection would be necessary to draw more robust conclusions and insights into these complex conditions.

4. CONCLUSION

In conclusion, pyometra represents a significant reproductive disorder in intact female dogs, often accompanied by bacterial infection and occasionally leading to emphysematous pyometra. The co-occurrence of uterine adenocarcinoma adds complexity to diagnostic considerations, with factors like age and histopathological characteristics playing crucial roles. Timely intervention is vital given the risk of malignant progression. Surgical intervention, such as ovariohysterectomy, remains the preferred treatment, especially when medical approaches fall short, as observed in the present case.

ACKNOWLEDGEMENT

The authors would like to thank the Dean of Madras Veterinary College, Professor, and Head, Department of Veterinary Gynaecology & Obstetrics for providing the necessary facilities to carry out this work.

COMPETING INTERESTS

Authors ~~have~~ have declared ~~that~~ that no competing interests exist.

ETHICS APPROVAL AND CONSENT

Not applicable

AUTHOR CONTRIBUTION

R.Akhter: Writing (original draft), J.Umameswari: Conceptualization, Writing (editing), R.Sureshkumar and T.Sarath: Visualization, R.Rangasamy and N.Pazhanivel: Methodology, K.Krishnakumar: Review

REFERENCES

1. Johnston SD, Root Kustritz MV, Olson PNS. Canine and Feline Theriogenology. Philadelphia: WB Saunders Co. 2001; 168–224.

2. Nelson RW, Feldman EC. Pyometra. *Veterinary Clinics of North America*. 1986; 16: 561–76.
3. Ravishankar N, Manoharmurli B, Balchandran C, et al. Haemato-biochemical alterations and pathological changes in canine pyometra. *Ind J Vet Pathol*. 2004; 28(1): 14–17
4. Rocha MFG, Paiva DDQ, Amando BR, Melgarejo CMA, Freitas AS, Gomes FIF et al., Antimicrobial susceptibility and production of virulence factors by bacteria recovered from bitches with pyometra. *Reprod Domest Anim*. 2022;57(9):1063-1073.
5. Mateus L, Eilts BE. Cystic endometrial hyperplasia and pyometra. In: Ettinger SJ, Feldman EC, editors. *Textbook of veterinary internal medicine*. 7th ed. Philadelphia: Saunders Elsevier.2009; 1913–21.
6. Hernandez, Juan Besso, J.G. Rault, D.N. Cohen, A.H. Guionnet, A. Begon, D. Ruel, Yannick. Emphysematous pyometra in a dog. the official journal of the American College of Veterinary Radiology and the International Veterinary Radiology Association. 2003; 44: 196-8.
7. Robert, S.J. Infertility in bitches and queens. *Veterinary Obstetrics and Genital Diseases*. 2nd edn., CAB Publisher and Distributors, India.2004; 227-236.
8. Chang J, Jung J, Jeong Y, Hong K, Kim K, Yoon J, et al. What is your diagnosis? Emphysematous pyometra with a large amount of gas. *J Small Anim Pract*. 2007; 48: 717–719.
9. Anderson C, Pratschke K. Uterine adenocarcinoma with abdominal metastases in an ovariohysterectomised female cat. *J Feline Med Surg*.2011; 13: 44-47.
10. Baldwin C, Roszel JF, Clark TP. Uterine adenocarcinoma in dogs. *Compend Contin Educ*.1992; 14: 731-737.
11. Klein, m. K. Tumors of the female reproductive system. In: *Small Animal Clinical Oncology*. 3rd edn. Eds S. J. Withrow and E. G. MacEwen. W. B.Saunders, Philadelphia, PA, USA. 2001; 445-454.
12. Cave TA, Hine R, Howie F, Thompson H, Argyle DJ. Uterine carcinoma in a 10- month-old golden retriever. *J Small Anim Pract*.2002; 43: 133–135.
13. Pires MA, Seixas F, Palmeira C, Payan-Carreira R. Histopathologic and immunohistochemical exam in one case of canine endometrial adenocarcinoma. *Reprod Domest Anim*.2010; 45: 545–549
14. Tsioli VG, Gouletsou PG, Loukopoulos P, Zavlaris M, Galatos AD. Uterine leiomyosarcoma and pyometra in a dog. *J Small Anim Pract*. 52(2): 121-4. 2011.
15. Chang AC, Cheng CC, Wang HC, Lee WM, Shyu CL, Lin CC, et al. Emphysematous pyometra secondary to *Enterococcus avium* infection in a dog. *Tierarztl Prax Ausg K Kleintiere Heimtiere*. 2016; 44: 195–9.
16. Thilagar S, Vinita WP, Heng HG, Aisah S, Khairani-Bejo S. What is your diagnosis? Small intestinal and colonic obstruction; emphysematous pyometra. *J Small Anim Pract*. 2006; 47: 687–8.
17. Mattei, C., Fabbi, M. & Hansson, K. Radiographic and ultrasonographic findings in a dog with emphysematous pyometra. *Acta Vet Scand*. 2018; 60: 67.
18. Michael J. Nathenson & Anthony P. Conley Prognostic factors for uterine adenosarcoma: a review, *Expert Review of Anticancer Therapy*. 2018; 18: 11; 1093-1100.

19. Fieni F, Topie E, Gogny A. Medical Treatment for Pyometra in Dogs. *Reproduction of Domestic Animals*. 2014; 49(2): 28–32.

FIGURES

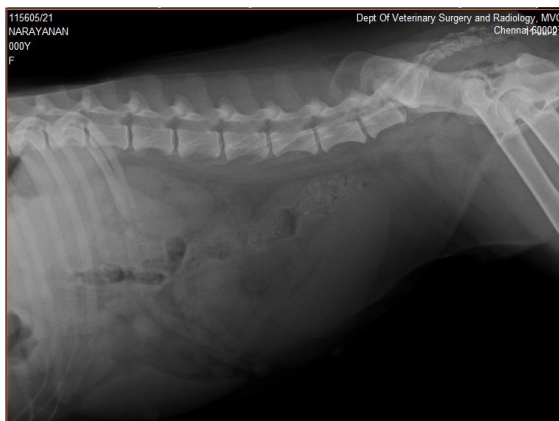

Fig. 1. Uterus noticed as tubular, distended uterine horns and displacement of colon

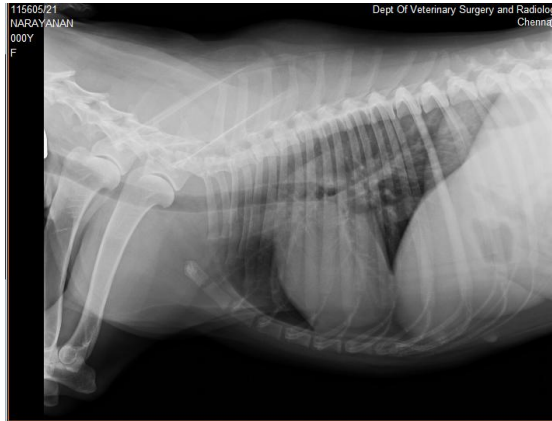


Fig. 2. Normal cardiac silhouette, bronchial pattern (tram lines) noticed.

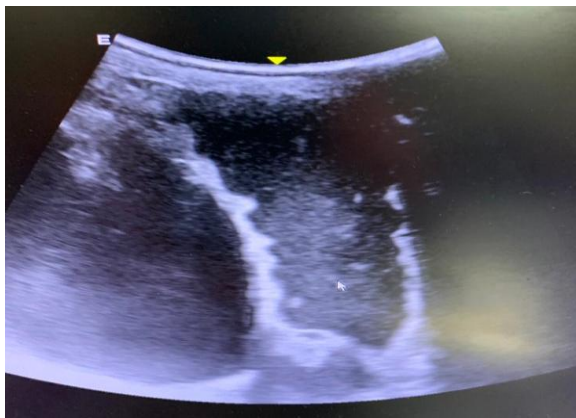


Fig. 3. Multiple cysts, ~~thickning~~ thickening of uterine wall and mixed echogenicity of uterine contents

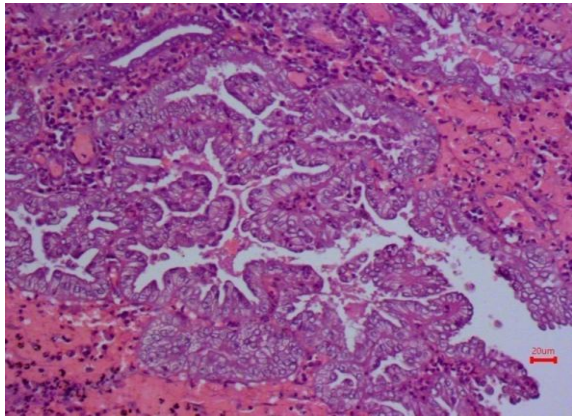


Fig. 4. Marked nuclear pleomorphism and solid growth pattern; the endometrium has prominent folds of neoplastic epithelial cells. Cystic lumens are plugged with neutrophils. H&E

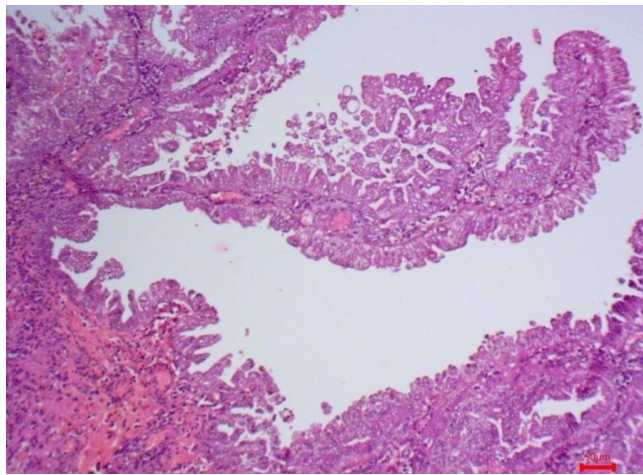


Fig. 5. Irregular shaped glands. Nuclei demonstrate pleomorphism

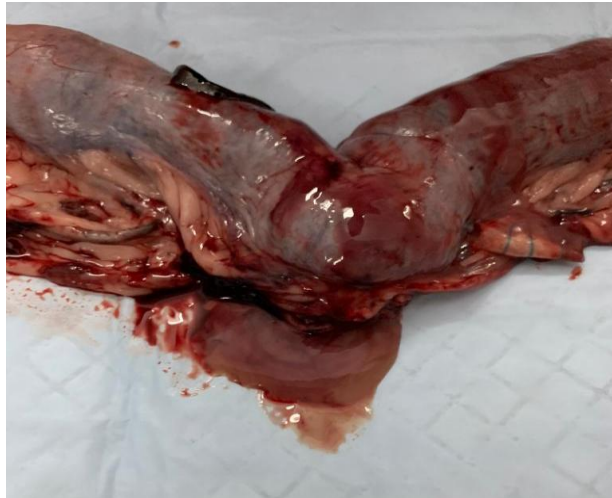

Fig. 6. Post-surgical gross appearance of the uterus. Uterine horns thin-walled, distended and fluctuant due to the gaseous and liquid content

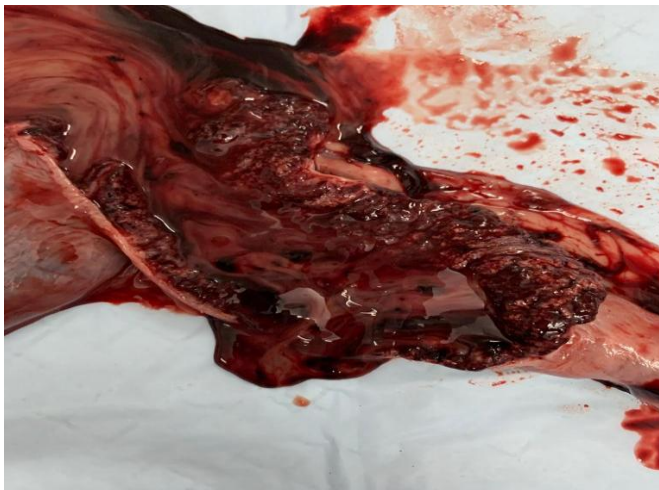

Fig. 7. Multiple cysts were noticed on the uterine wall and presence of gas and liquid contents in uterus.