

Short communication

In Vitro Acaricidal Effect of Proparacaine HCl on Demodex folliculorum

Abstract

Purpose: This research aimed to assess the underlying cause behind the in vitro acaricidal impact of proparacaine HCl on Demodex folliculorum.

Methods: By modifying the classical Coston method [byin accordance with](#) Gao's suggestion we epilated a total of 8 eyelashes 4 from the lower and 4 from the upper eyelid of a patient who applied for rosacea and blepharitis symptoms to our İstanbul Medipol University Ophthalmology clinic. We fixated 4 of these eyelashes with classical immersion oil and covered them with a coverslip. We wetted 4 of them with Proparacaine Hydrochloride 5 mg (0.5%) (Alcaine; Alcon, Puurs, Belgium) drops and painted them lightly with Na-fluorescein, and covered them with a coverslip.

Results: When we examined the eyelashes that were wetted with Proparacaine Hydrochloride under the light microscope there was no difference in mobility in the Demodex of the eyelashes at first 15 minutes. After 30 minutes we saw that the creamy lipid-like structure which is seen normally in the middle of the Demodex was saponified in Demodex. The other demodex samples that were in the immersion oil were still alive.

Conclusions: In this case report, we wanted to evaluate the reason for the acaricidal effect of Proparacaine Hydrochloride a local anesthetic agent on Demodex folliculorum. The idea came true while trying to demonstrate Na-fluorescein uptake of Demodex folliculorum under the microscope after using Proparacaine Hydrochloride 5 mg (0.5%) (Alcaine; Alcon, Puurs, Belgium) to wet the Na-fluorescein paper and surprisingly we obtained these findings suggesting that it is a substance that may have an anti-acaricidal, anti-demodex effect potential to be a new player for treatment of demodicosis in the future.

Key words: Demodex, proparacaine, parasites, eye

Introduction:

Demodex mite is the most common obligate human ectoparasite found on human skin and eyes.(1) Demodex, a member of the class Arachnida and subclass Acari, shares a common lineage with other arthropods. They are commonly known as prostigmatid mites, characterized by having one or two pairs of stigmata near the gnathosoma region associated with the chelicerae.(2) The widespread presence of these skin mites among mammals indicates that the parasitic relationship is highly ancient, potentially originating soon after the initial diversification of mammals approximately 220 million years ago, coinciding with the emergence of animals possessing hair follicles.(3) Although there are much more subtypes in animals only two subtypes are seen only in humans which are Demodex Folliculorum (DF) and Demodex Brevis(DB). (2) Their detection and identification are based on the sizes. DB from 100 to 200 µm and DF from 200 to 400 µm.(3) Treating Demodex infestation and confirmed demodicosis is a challenging and time-consuming process that often extends over several months. The primary objectives of therapy are to hinder parasite reproduction, eliminate mites, and prevent future infestations. Systemic treatment for demodicosis typically involves administering antibiotics such as Tetracycline, Doxycycline, Metronidazole, and Ivermectin. Topical treatments commonly used for demodicosis include Metronidazole, Permethrin, Benzocyl Benzoate,

Crotamiton, Lindane, and Sulfur. In addition to antibiotics, various medicinal oils like Camphor oil, Bergamot oil, Tea Tree oil, Peppermint oil, and Salvia oil, as well as a sulfur ointment, yellow or white mercury ointment, and cholinesterase inhibitors are used in therapy.(4) There is no FDA-approved treatment for demodicosis.

In this research, we wanted to evaluate the reason for the acaricidal effect of proparacaine HCL a local anesthetic agent on DF. The idea came true while trying to demonstrate Na-fluorescein uptake of DF under the microscope after using Proparacaine Hydrochloride 5 mg (0.5%) (Alcaine; Alcon, Puurs, Belgium) to wet the Na-fluorescein paper and surprisingly we obtained findings suggesting that it is a substance that may have an anti-acaricidal, anti-demodex effect potential to be a new player for treatment of demodicosis in the future.

Materials & Methods:

The beginning point of this research was how demodex takes in Na-fluorescein and if we can see the emission of Na-fluorescein under cobalt blue light and compare the images taken under the standard protocol of our ophthalmology clinic. By modifying the classical Coston method [by in accordance with Gao's suggestion](#) we epilated a total of 8 eyelashes 4 from the lower and 4 from the upper eyelid of a patient who applied for rosacea and blepharitis symptoms to our İstanbul Medipol University Ophthalmology clinic.(5) We fixated 4 of these eyelashes with classical immersion oil and covered them with a coverslip. We wetted 4 of them with Proparacaine Hydrochloride 5 mg (0.5%) (Alcaine; Alcon, Puurs, Belgium) drops and painted them lightly with Na-fluorescein, and covered them with a coverslip.

Results:

When we examined the eyelashes that were wetted with proparacaine HCL under the light microscope there was no difference in mobility in the Demodex of the eyelashes at first 15 minutes. After 30 minutes we saw that the creamy lipid-like structure which is seen normally in the middle of the Demodex was saponified in the Demodex. This was [really](#) a surprise for us because our research was to show the diffusion of Na-fluorescein in demodex and examine the emission of it with cobalt blue light but we encountered these interesting images.(Figure 1-2) The lashes which were wetted with olive oil were not affected after 30 minutes even after 1 hour.(Figure 3) When we investigated the reason for this effect, we found that the origin of Proparacaine HCL molecules, which we use as an anesthetic, is also used as an anti-parasitic that has an effect on voltage-gated Na channels of the insects and we thought that this subject is worth investigating.

Discussion:

Demodex mite is an important saprophytic pathogen in ophthalmology as well as dermatology.(1) They are the most common ectoparasite on human skin and eyes. They were first identified by an anatomist Henle in 1841 and reported in 1842 by Gustav Simon, a German dermatologist, who examined mites in sebaceous follicle samples taken from an individual with acne lesions on the skin surface. (6) For nearly 200 years they did not thought to be disease-causing agents.(7) They are examined in 3 anatomical parts. 4 pairs of legs, the head, and [the](#) tail to which they are attached. DF and DB differ in structure and location. DF has a longer tail, is more in eyelashes, and is located at the root of the cilia with their heads attached to the lash root, while DB has a shorter tail, and is more common in the body, unlike DF, it is found alone deep in the glands. Female Demodex mites exhibit a slightly shorter and rounder physique compared to males. Both genders possess a genital opening,

and fertilization occurs internally. Mating transpires within the opening of the hair follicle, while eggs are deposited inside the hair follicles or sebaceous glands.(1) As individuals age, the quantity of Demodex mites within lesions tends to increase, and older individuals are more prone to carrying these mites. It is presumed that Demodex is transmitted to newborns through close physical contact shortly after birth. However, infants and children, due to their low sebum production, typically lack significant colonization by Demodex.(9) They have an undeveloped digestive system and are even believed to have no anus and due to this anatomic difference he vomits the epithelial cells and fat it eats in a certain period. Demodexes, who lead a melatonin-dependent life, have adapted very well to the human host. Demodexes, which are very sensitive to light and heat, are activated by the melatonin of the human host and go to the eyelash edge to find a mate generally after 8 pm. Demodexes, which have a life cycle of 14-18 days, lay their eggs on the edge of the lid in 12-14 numbers. While they cause mechanical damage to the eyelash edge with their fork-like hands that function like claws, they inflict chemical damage with lipases and cytokines like IL-17, and MMP9 in their vomit and cause inflammation in patients. (10)

Treating Demodex infestation and confirmed demodicosis poses a significant challenge, as it involves a complex and often protracted therapy lasting several months. The primary objectives of treatment are to impede parasite reproduction, eradicate the mites, and prevent re-infestation. Systemic treatment for demodicosis relies on the administration of antibiotics, such as Tetracycline, Doxycycline, Metronidazole, and Ivermectin. Metronidazole, Permethrin, Benzocyl Benzoate, Crotonamiton, Lindane, and Sulfur are among the most commonly used topical treatments for demodicosis. However, it is important to note that the application of these agents may occasionally result in skin irritation for patients.(11) In addition to antibiotics, various medicinal oils, including Camphor oil, Bergamot oil, Tea Tree oil, Peppermint oil, and Salvia oil, as well as a sulfur ointment, yellow or white mercury ointment, and cholinesterase inhibitors, are employed as part of the therapeutic approach.(4) To date there is no FDA-approved treatment ~~for~~ demodicosis.

In this research, we surprisingly realized the death and saponification in the Demodex body which is opposite of the one we see due to mineral oils such as tea tree oil and immersion oil. In those cases we see immobility and after hours we see the empty skeleton of the Demodex but when the death is due to proparacaine HCL at first we see creamy saponification and then immobility which is similar to the mechanism we observe after using ivermectin antiparasite drug. Upon investigating the underlying cause of this situation, we found from the literature that certain medications such as local anesthetics, antiarrhythmics, and anticonvulsants contain charged and electroneutral compounds that block voltage-gated sodium channels.(12) Local anesthetics like lidocaine, for example, disrupt the initiation and propagation of nerve impulses by inhibiting sodium channels, resulting in pain relief or prevention.(13) Sodium channels play a vital role in membrane depolarization, opening up to allow sodium ions into the cell and causing membrane potential depolarization.(14) Proparacaine HCL exhibits local anesthetic properties as a hydrochloride salt form of proparacaine. It stabilizes neuronal membranes by binding to and inhibiting voltage-gated sodium channels, thereby preventing the influx of sodium ions required for impulse initiation and conduction within neuronal cells, leading to a loss of sensation.

These sodium channels are targeted by various natural and synthetic insecticides, including DDT (dichlorodiphenyltrichloroethane), pyrethroids, and sodium channel blocker insecticides (SCBI), which demonstrate high selectivity for insects.(15) Some peptide venom toxins found in scorpions and sea anemones selectively affect insect sodium channels while sparing their mammalian counterparts.(16,17) It is worth noting that ligands targeting the same region of sodium channels and exhibiting similar electrophysiological characteristics display a wide range of mechanisms,

highlighting the diversity in their action. Studies have indicated that local anesthetics have similar effects on insect and mammalian sodium channels expressed in *Xenopus oocytes*.(18)

While bacterial and eukaryotic voltage-gated sodium channels share similarities that make them suitable models for studying tonic block, there are also functional and structural differences between them.(19) Insecticides, like local anesthetics, preferentially bind to the inactivated state of sodium channels, irreversibly blocking them.(20,21) The distinct pharmacology exhibited by insect sodium channels holds promise for the discovery and development of new insecticides.

Conclusions:

In conclusion, the observed acaricidal effect of Proparacaine HCl in this case report indicates its potential as a new therapeutic option for the treatment of ocular demodicosis. Researchers should take this effect into account when collecting eyelashes for investigations, as it may influence the study results. Further research is necessary to explore the effectiveness, safety, and optimal dosage of Proparacaine HCl for this indication. The development of new, non-toxic treatments for demodicosis is of utmost importance in enhancing patient outcomes and alleviating the burden of this condition.

REFERENCES

- 1- Rather PA, Hassan I. Human demodex mite: the versatile mite of dermatological importance. *Indian J Dermatol.* 2014; 59(1):60-6.
- 2- Sastre N, Francino O, Curti JN, Armenta TC, Fraser DL, Kelly RM, Hunt E, Silbermayr K, Zewe C, Sánchez A, Ferrer L. Detection, Prevalence and Phylogenetic Relationships of *Demodex* spp and further Skin Prostigmata Mites (Acari, Arachnida) in Wild and Domestic Mammals. *PLoS One.* 2016; 11(11):e0165765.
- 3- Zhou C-F, Wu S, Martin T, Luo Z-X. A Jurassic mammaliaform and the earliest mammalian evolutionary adaptations. *Nature.* 2013; 500: 163–7.
- 4- Chudzicka-Strugała I, Gołębiewska I, Brudecki G, Elamin W, Zwoździak B. Demodicosis in Different Age Groups and Alternative Treatment Options—A Review. *Journal of Clinical Medicine.* 2023; 12(4):1649.
- 5- Gao YY, Di Pascuale MA, Li W, Liu DT, Baradaran-Rafii A, Elizondo A, Kawakita T, Raju VK, Tseng SC. High prevalence of *Demodex* in eyelashes with cylindrical dandruff. *Invest Ophthalmol Vis Sci.* 2005; 46(9):3089-94.
- 6- Metin Z, Boyraz N, Örnek F, Şingar Özdemir E, Ekşioğlu HM. Evaluation of the incidence of *Demodex* in eyelashes in rosacea patients with ocular involvement. *Turkderm-Turk Arch Dermatol Venereol* 2022; 56:70-5.
- 7- Wesolowska M, Knysz B, Reich A, Blazejewska D, Czarnecki M, Gladysz A, Pozowski A, Misiuk-Hojlo M. Prevalence of *Demodex* spp. in eyelash follicles in different populations. *Arch Med Sci.* 2014; 10(2):319-24.
- 8- Liu J., Sheha H., Tseng S.C. Pathogenic role of *Demodex* mites in blepharitis. *Curr. Opin. Allergy Clin. Immunol.* 2010; 10:505.

- 9- Sengbusch HG, Hauswirth JW. Prevalence of hair follicle mites, *Demodex folliculorum* and *D. brevis* (Acari: Demodicidae), in a selected human population in western New York, USA. *J Med Entomol.* 1986; 23:384–8.
- 10- Kim J.T., Lee S.H., Chun Y.S., Kim J.C. Tear cytokines and chemokines in patients with *Demodex* blepharitis. *Cytokine.* 2011; 53:94–9.
- 11- Jacob, S, VanDaele, MA, Brown, JN. Treatment of *Demodex*-associated inflammatory skin conditions: A systematic review. *Dermatologic Therapy.* 2019; 32:e13103.
- 12- Tikhonov DB, Zhorov BS. Mechanism of sodium channel block by local anesthetics, antiarrhythmics, and anticonvulsants. *J Gen Physiol.* 2017; 149(4):465-81.
- 13- Catterall WA. Cellular and molecular biology of voltage-gated sodium channels. *Physiol Rev.* 1992; 72(4 Suppl):S15-48.
- 14- Silver KS, Du Y, Nomura Y, Oliveira EE, Salgado VL, Zhorov BS, Dong K. Voltage-Gated Sodium Channels as Insecticide Targets. *Adv Insect Phys.* 2014; 46:389-433.
- 15- Zhang J, Shi Y, Fan J, Chen H, Xia Z, Huang B, Jiang J, Gong J, Huang Z, Jiang D. N-type fast inactivation of a eukaryotic voltage-gated sodium channel. *Nat Commun.* 2022; 13(1):2713.
- 16- Bosmans F, Martin-Eauclaire MF, Swartz KJ. Deconstructing voltage sensor function and pharmacology in sodium channels. *Nature.* 2008; 456(7219):202-8.
- 17- Moran Y, Kahn R, Cohen L, Gur M, Karbat I, Gordon D, Gurevitz M. Molecular analysis of the sea anemone toxin Av3 reveals selectivity to insects and demonstrates the heterogeneity of receptor site-3 on voltage-gated Na⁺ channels. *Biochem J.* 2007; 406(1):41-8.
- 18- Martin LJ, Akhavan B, Bilek MMM. Electric fields control the orientation of peptides irreversibly immobilized on radical-functionalized surfaces. *Nat Commun.* 2018; 9(1):357.
- 19- Golzari SE, Soleimanpour H, Mahmoodpoor A, Safari S, Ala A. Lidocaine and pain management in the emergency department: a review article. *Anesth Pain Med.* 2014 Feb 15;4(1):e15444.
- 20- Song W, Silver KS, Du Y, Liu Z, Dong K. Analysis of the action of lidocaine on insect sodium channels. *Insect Biochem Mol Biol.* 2011; 41(1):36-41.
- 21- Dong K. Insect sodium channels and insecticide resistance. *Invert Neurosci.* 2007; 7(1):17-30.

FIGURES

FIGURE 1: Saponification of *Demodex folliculorum* ectoparasite after wetted with Proparacaine HCl and Na-Fluorescein

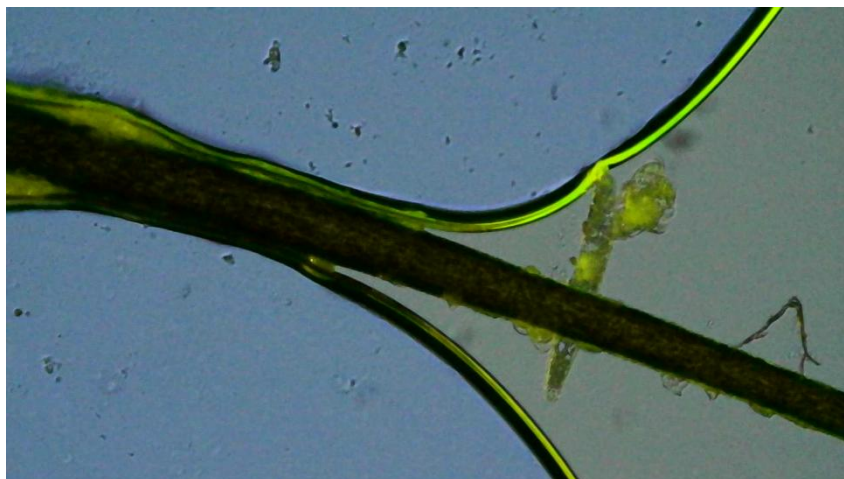



FIGURE 2: The Demodex couple saponification of *Demodex folliculorum* ectoparasite after wetted with Proparacaine HCl and Na-Fluorescein

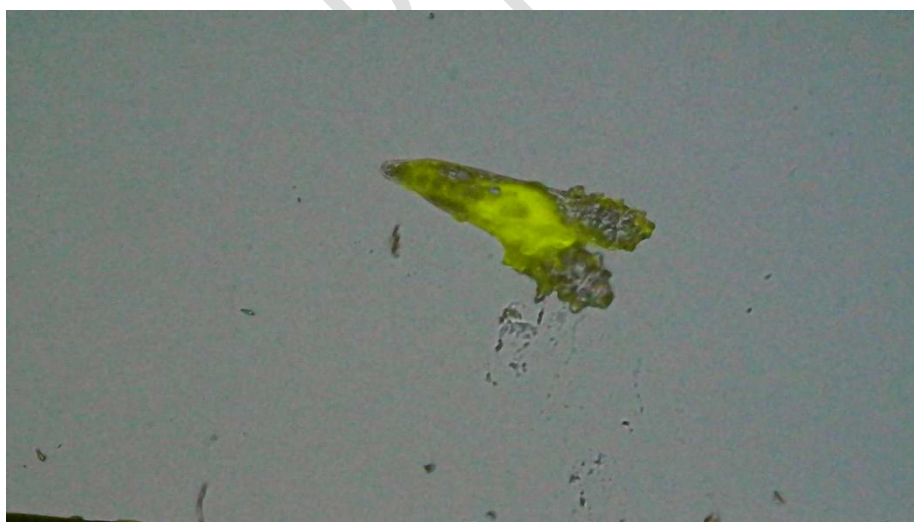

FIGURE 3: There is no saponification in the Demodex folliculorum after being wetted only with immersion oil.



UNDER PEER REVIEW