

Case report
Primary Hydatid Cyst of The Thigh – A Case Report

Abstract

Hydatid cyst is caused by the dog tapeworm *Echinococcus granulosus*. Hydatid cysts are most frequently found in the liver (75%) and lungs (15%) and 10% occur in any part of the human body. Primary muscular hydatidosis is very rare and occurs in 1-4% in of all hydatidosis. The localizations of hydatid cyst in muscles is rare 0.7-0.9% even in endemic countries. Muscular hydatidosis is rare, because of muscle lactic acid content and muscle contraction, there two factors that likely prevent cyst growth in striated muscles.

Muscle hydatid disease most often manifests as a slow growing soft-tissue tumour and mostly present with a painless growing mass. However, the cyst is clinically asymptomatic and diagnosed incidentally. The most common skeletal muscle sites include the hip and thigh and the shoulder and humours regions.

We report a rare case of primary hydatid cyst of the right thigh in a 32 years' male patient, with asymptomatic thigh mass and diagnosed on ultrasonography. We performed total surgical excision of the mass with pericystectomy, and Albendazole therapy was given preoperative and postoperatively.

Keywords

Echinococcus granulosus, Hydatid cyst, Skeletal muscles,

Introduction

“Hydatid disease is a major problem in the endemic areas, including Asia, Africa, the middle east, Australia, New Zealand and South America. Hydatid disease is caused by the tapeworm *Echinococcus granulosus*, with the liver and lungs most commonly affected organs in 75% and 15% of cases respectively. Due to the filtration action of the liver and lungs in preventing *Echinococcus* to enter the systemic circulation, Hydatid cysts are rarely found in the skeletal muscles. This is due to the contractility of muscles and high concentration of lactic acid and reported incidence in less than 1.5%”. [1,3,5]

“However, hydatid cysts are inclined to grow in the trunk, neck and legs because of relatively less muscle contraction and more vascularization of these areas. Intramuscular hydatid cysts have been reported in the muscles of chest wall and pectoralis major, Sartorius, quadriceps and gluteal muscles. Ultrasonography is non-invasive, in expensive and repeatable imaging modality, which is widely used and accepted in the diagnosis of hydatid disease”. [2,6,7]

Case Presentation

A 32 year old man was admitted to our centre on 15/09/2010, complaining of painless swelling in his right thigh which he had noticed for 1 year. He had no history of trauma, surgery or any other disease. Physical examination revealed a non-tender mass measuring 15x12 cm in his right thigh, located at the lower end, antero-medial aspect of thigh. There was no lymphadenopathy in the inguinal region. He had no restriction of movements at the hip and knee joints. Blood investigation were normal.

Right thigh ultrasonography revealed a large well defined double walled cystic lesion of size 15x12x8 cm in the muscle plane of the medial aspect of right thigh, with well-defined unilocular anechoic cystic lesion suggestive of hydatid cyst in the thigh muscles. CT and MRI was not done.

The patient was prescribed Albendazole 15 mg/kg/day orally of 4 weeks before the surgery. The patient was planned surgery under spinal anaesthesia. An antero-medial skin incision was made in the right thigh. The entire large cystic mass along with pericyst was carefully dissected from its

surrounding muscles and bone posteriorly. The total large cyst was taken out without any spillage from cyst. Locally betadine as a scolicial agent was used in the surrounding the muscles tissue. A Romo vac drain was inserted and the wound sutured in layers. Histopathological examination confirms the diagnosis of a hydatid cyst. (Fig 1-6)

Gross examination of the cyst revealed it to be 15x12x8 cm in size, and after cutting the cyst unilocular white gelatinous membrane of hydatid cyst was delivered out. Post-operative recovery was uneventful and the patient was discharge on the 8th postoperative day. Albendazole therapy was given for 6 months postoperatively. After one year follow-up there was no recurrence and the patient was healthy.

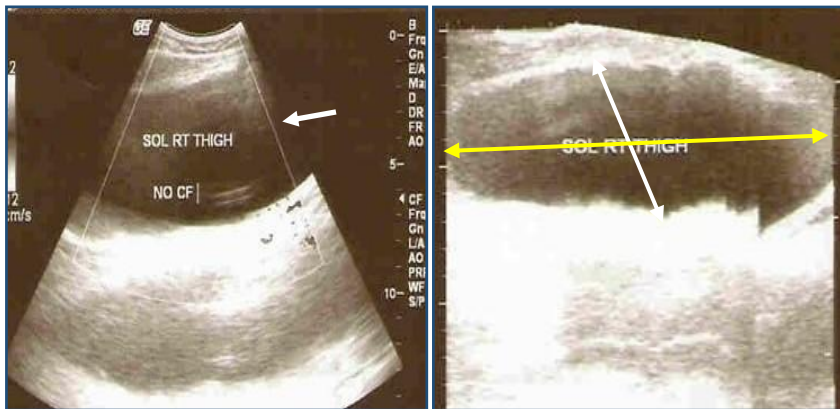


Fig-1 Ultrasonography of Right thigh showing hypoechoic unilocular cystic double walled lesion of size 15x12x8 cm

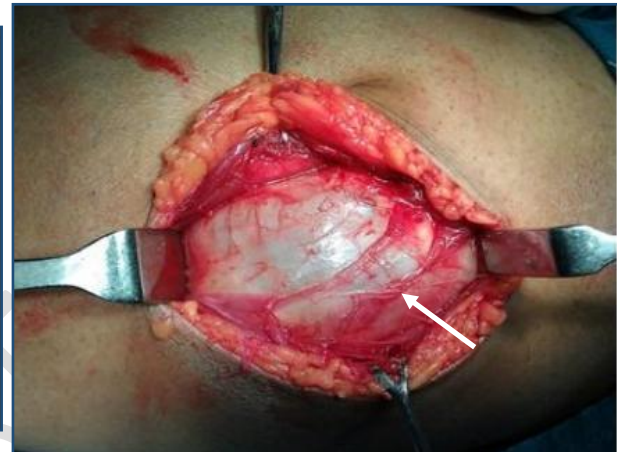


Fig-2 Intra-operative photograph showing cystic mass in Right thigh

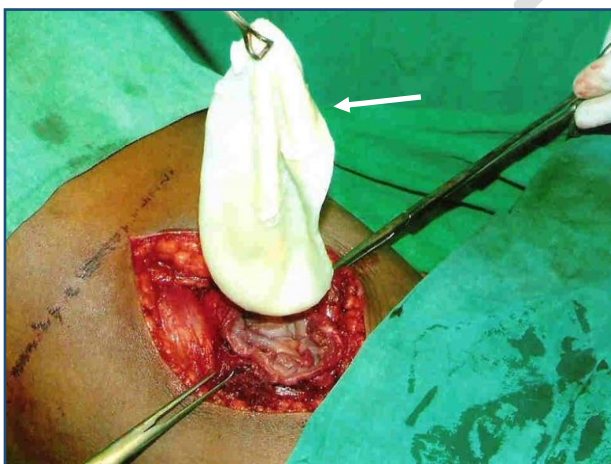


Fig-3 Intraoperative photograph showing white gelatinous laminated hydatid cyst

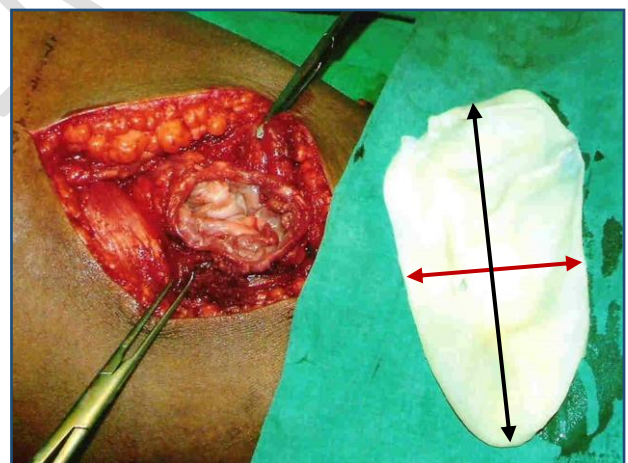


Fig-4 Intra-operative photograph showing unilocular hydatid cyst of size 15x12x8 cm

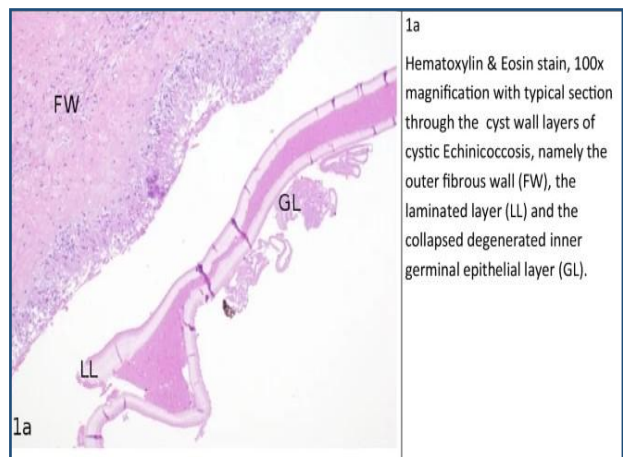
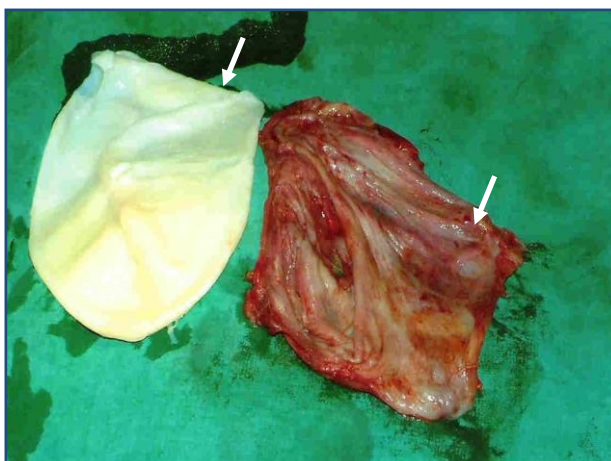


Fig-5 Photograph showing white laminated layer of a hydatid cyst with pericystectomy specimen

Fig-6 Photograph showing histopathological examination

Discussion

Mesddi et al reported 11 cases of intramuscular hydatid cysts in period of 17 years. Up to date, seventeen cases of hydatid disease of the thigh have been reported in the literature. Primary skeletal muscles hydatidosis is rare and have been reported in only 1-4% of all patients in endemic areas. "Intramuscular hydatid cyst is rare because the growth of cysts within the muscles is hindered by the contraction and relaxation of the muscle and by high local concentration of the lactic acid in the muscles. Parasite cysts most commonly grow in the muscles of neck, trunk and limbs probably because of less muscles activity and more vascular suppling in these areas". [2,8,]

"A hydatid cyst has three layers. The outer pericyst is composed of modified host cells a protective zone only a few millimetres thick. The middle, laminated membrane the white in colour and easily ruptured. It is acellular and 2 mm thick. The inner, germinal or geminating layers is thin and translucent called endocysts. It produces the scolices, brood capsules, forming hydatid sand. The cyst fluid is crystal clear, contains proteins and is antigenic causing eosinophilia or anaphylaxis" [11].

"Ultrasonography should be the first diagnostic tool used for detection of hydatid disease of soft tissue. The sensitivity of ultrasonography is 95% and sensitivity increase to 100%. The CT scan has an accuracy of 98% to demonstrate the daughter cysts and thin rim of calcification, a cyst suggestive of an echinococcus cyst. MRI no real advantage over CT scan". [3,4,7]

Serological test can be used for diagnosis, screening and post-operative follow up for recurrence. These included hydatid immunoelectrophoresis, ELISA, latex agglutination and indirect haem agglutination(IHA) test. The sensitivity of serological test is from 64 to 87%. Surgery is the most effective treatment of choice for hydatid cysts. It should be removed radically whenever possible. During surgery, Spillage of the cyst content is to be avoided as it causes dangerous anaphylaxis and dissemination. Intraoperative irrigation using 0.5% cetrimide, 15% hypertonic saline and 0.5% silver nitrate solution can be used to kills the daughter cysts and reduces the recurrence.

In our case after total excision of the cyst, the surgical site was irrigated using betadine and hydrogen peroxide to avoid dissemination of the hydatid cyst. "In the treatment of hydatid cyst, surgical excision and preoperative and postoperative Albendazole therapy are the gold standard treatment". [6,8]

Conclusion

Primary hydatid cyst of the thigh is an extremely rare manifestation of hydatid disease which is endemic in India and should be diagnosed with ultrasonography and MRI. Complete surgical excision of the hydatid cyst using pericystectomy is the first choice of treatment along with Albendazole therapy.

Ethical Approval

As per international standard or university standard written ethical approval has been collected and preserved by the author(s).

Consent

As per international standard or university standard, patient(s) written consent has been collected and preserved by the author(s).

Reference

1. Argy N, Abou Bacar A, Boeri C, Lohmann C, Pfaff AW, Hansmann Y, Christmann D, Candolfi E, Lefebvre N. Primary musculoskeletal hydatid cyst of the thigh: Diagnostic and curative challenge for an unusual localization. *Can J Infect Dis Med Microbiol*. 2013 Fall;24(3):e99-e101. doi: 10.1155/2013/829471. PMID: 24421841; PMCID: PMC3852467.
2. Gougoulas NE, Varitimidis SE, Bargiotas KA, Dovas TN, Karydakis G, Dailiana ZH. Skeletal muscle hydatid cysts presenting as soft tissue masses. *Hippokratia*. 2010 Apr;14(2):126-30. PMID: 20596270; PMCID: PMC2895288.
3. Recep Tekin, Alper Avci, Rojbin Ceylan Tekin, Mehmet Gem and Remzi Cevik, Hydatid cysts in muscles: clinical manifestations, diagnosis, and management of this atypical presentation, *Revista da Sociedade Brasileira de Medicina Tropical* 48(5):594-598, Sep-Oct, 2015 Major Article <http://dx.doi.org/10.1590/0037-8682-0197-2015>
4. Soltany S, Hemmati HR, Toussy JA, Nazifi H, Alibakhshi A, Toosi PA. Evaluation of Musculoskeletal Hydatid Cyst Cases in Terms of Clinical Manifestations, Method of Dealing, Treatment, and Recurrence. *Open Access Maced J Med Sci*. 2020 Mar 25; 8(E):99-104. <https://doi.org/10.3889/oamjms.2020.4274>
5. Arian, M, Kazerani, M. Primary hydatid cyst in the adductor muscles of thigh: A case report. *Clin Case Rep*. 2022; 10:e06664. doi:10.1002/ccr3.666
6. Agrawal DK, Singh SK, Suganita, et al. Unusual presentation of extensive hydatid cyst in calf muscle: a case report. *J Evolution Med Dent Sci* 2016;5(6):325-329, DOI: 10.14260/jemds/2016/70
7. Abdelhafid El Marfi, Mohamed Lahsika, Said Senhaji, Hachem Chafik, Ali Krite, Mohamed El Idrissi, Abdelhalim El Ibrahim , Abdelmajid El Mrini, Primary hydatid cyst of the thigh: about four cases, *PAMJ - Clinical Medicine - ISSN: 2707-2797 (www.clinical-medicine.panafrican-med-journal.com)*
8. Gupta V, Tayade A, Kale S, Intramuscular Hydatid Cyst of Adductor Magnus: A Rare Isolated Presentation, *NJR / VOL 3 / No. 1/ ISSUE 4 / Jan-June, 2013*
9. Özdemir M, Kavak RP, Kavak N, Akdur NC. Primary hydatid cyst in the adductor magnus muscle. *BJR Case Rep* 2020; 6: 20200019
10. Landolsi M, Kouki S, Abdennadher A Hydatid cyst of the thigh: a challenging diagnosis *Case Reports* 2017;2017:bcr-2017-222113.
11. Gupta V, Tayade A, Kale S. Intramuscular hydatid cyst of adductor Magnus: A rare isolated presentation. *Nepalese Journal of Radiology*. 2013 Oct 6;3(1):71-6.

UNDER PEER REVIEW