

# Gitelman Syndrome presenting as Hypokalemic Periodic Paralysis : A Case Report

## ABSTRACT

Gitelman Syndrome is a type of inherited tubulopathy that results in hypokalemia, hypomagnesemia, hypocalciuria and metabolic alkalosis.<sup>[6][10]</sup> It is generally due to loss of function mutation of SLC12A3 Gene.<sup>[2]</sup> The prevalence is estimated at approximately 1:40,000.<sup>[6]</sup> In the majority of cases, symptoms do not appear before the age of six years and the disease is usually diagnosed during adolescence or adulthood.<sup>[6]</sup> Some patients experience severe fatigue interfering with daily activities, while others never complain of tiredness. The symptoms and severity can even vary among members of the same family.<sup>[6]</sup> Blood pressure is lower than that in the general population.<sup>[6]</sup> The prognosis of patients with Gitelman Syndrome is excellent, except the few patients may be at risk for Cardiac arrhythmias.<sup>[6]</sup> Potassium and Magnesium depletion increases the risk of ventricular arrhythmia. Sudden cardiac arrest has been reported occasionally.<sup>[6]</sup> We describe case of a man in his early 40's having severe hypokalemia but only mild muscular weakness. **Patient did not have any neurological deficit. His tone, power (5/5 in all four limbs) and deep tendon reflexes (+2 in all four limbs) were absolutely normal.**

**KEYWORDS :** Hypokalemic periodic paralysis, Gitelman Syndrome, Inherited Tubulopathy, Metabolic Alkalosis, Hypomagnesemia, Hypocalciuria

## INTRODUCTION

Gitelman syndrome is an inherited hypokalemic salt losing tubulopathy, characterized by hypokalemic metabolic alkalosis, hypomagnesemia, hypocalciuria, secondary aldosteronism, a high urinary chloride concentration and an absence of thiazides from the urine.<sup>[5][8][9]</sup> It was first described by Gitelman in 1966.<sup>[9]</sup> It is generally inherited as an autosomal recessive trait due to biallelic inactivating mutation in SLC12A3 gene that encodes the thiazide sensitive sodium chloride cotransporter (NCC) expressed in the apical membrane of cells lining the distal convoluted tubule of the kidney.<sup>[1][6][12]</sup> The

abnormal luminal membrane transporters are shed into the urine in nanovesicles called urine exosomes. Reduced NCC activity in urine exosomes has been described in patients with Gitelman syndrome, and this may be utilized in future as a diagnostic test.<sup>[13]</sup> In a small minority of GS patients, mutations in the CLCNKB gene, encoding the chloride channel ClC-Kb have been identified.<sup>[6][11]</sup> Antenatal diagnosis for GS is technically feasible but not advised because of good prognosis in majority of patients.<sup>[6]</sup>

Main symptoms include mild muscular weakness and cramps, hypotension, salt craving, chondrocalcinosis of the knees, occasional episodes of tetany, constipation, abdominal pain and vomiting.<sup>[2][3]</sup> First line therapy is always oral supplementation with generous dose of sodium chloride or potassium chloride. Magnesium supplementation is necessary as hypomagnesemia worsens renal potassium wasting.<sup>[14]</sup> Potassium sparing diuretics (Spironolactone, Eplerenone, Amiloride) are generally the next line of therapy when supplementation alone is insufficient. NSAIDs, typically Indomethacin may be helpful.<sup>[15]</sup> ACEI reduce aldosterone levels and therefore renal potassium loss.

## CASE REPORT

A 40 year old male patient, not a known case of any comorbidity, presented on 17<sup>th</sup> march, 2023 with chief complains of **insidious onset** generalized weakness, decreased appetite, constipation and tetany. The patient was thin and lean, having good built but poor nourishment. [ height =164 cm and weight =45 kg (BMI-16.73 kg/m<sup>2</sup>)]. Patient works as a farmer. Patient is a tobacco chewer since 10 years ( 1 packet in 2 days ). There is no history of smoking, alcohol or drug abuse. The patient born out of non consanguineous marriage, **at full term by normal vaginal delivery**. The patient is having one elder brother. There is no history of similar illness in family.

Past History :

In October 2020, patient was having similar complains of generalized weakness and was diagnosed as having hypokalemic periodic paralysis. Serum potassium

was 1.73 and the patient was given intravenous supplementation of potassium chloride. At the time of discharge, he was advised to continue oral supplementation of potassium chloride.

Till one week prior to admission, patient was relatively in good health after which he developed complains of generalized weakness, decreased appetite, constipation and tetany, and seek outside medical facility on 14<sup>th</sup> march, 2023.

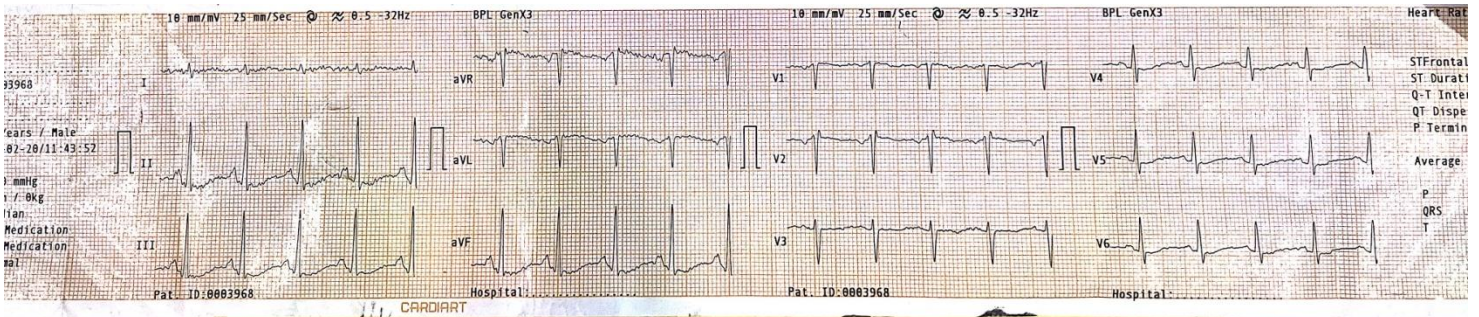
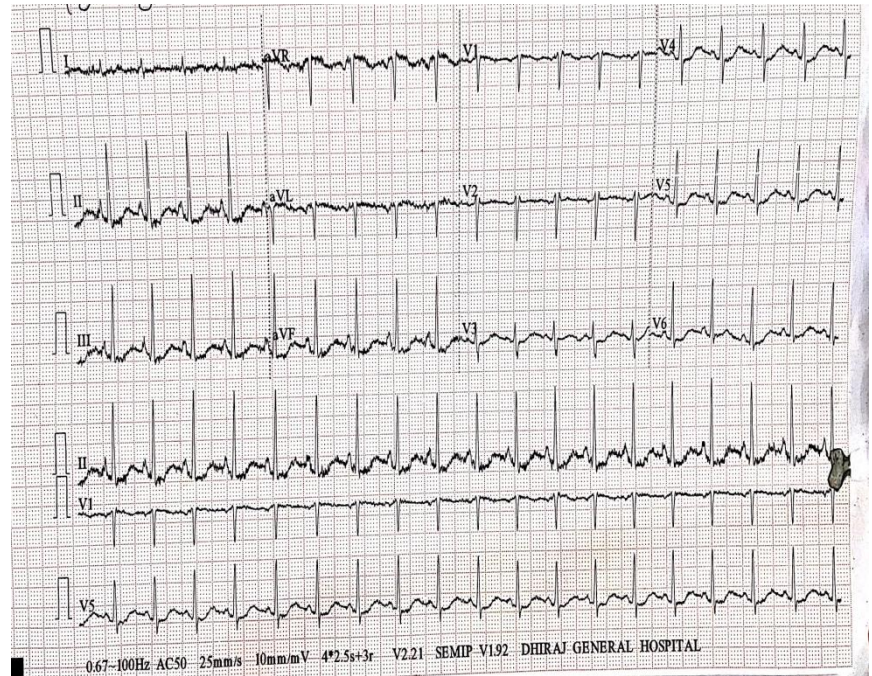
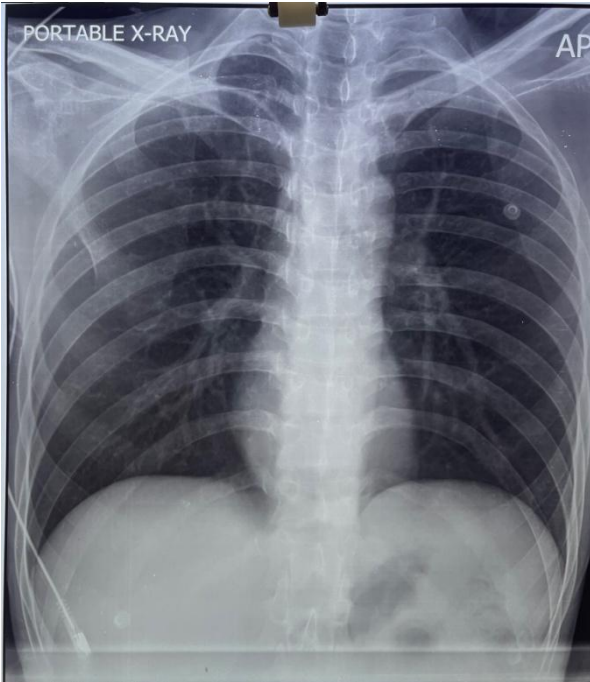
Investigation	14/03/23	15/03/23	16/03/23	17/03/23	REFERENCE RANGE
Hb	11			11	13-17 gm/dl
TC	11,400				4000-11000 cells/mm <sup>3</sup>
Platelets	3.86				1.5-4.5 lacs/mm <sup>3</sup>
RBS	70				70-140 mg/dl
S. TSH		2.86			0.39-5.0 uIU/ml
S. sodium	129.2	128.4	133.9	133.2	135-145 mEq/L
S. potassium	1.82	1.58	2.18	2.0	3.5-5.5 mEq/L
S. chloride	70	90	96	95	98-110 mEq/L
U. sodium			40.10		40-220 mEq/L
U. potassium			16.44		25-120 mEq/L
S. magnesium	1.6				1.8-2.6 mg/dl

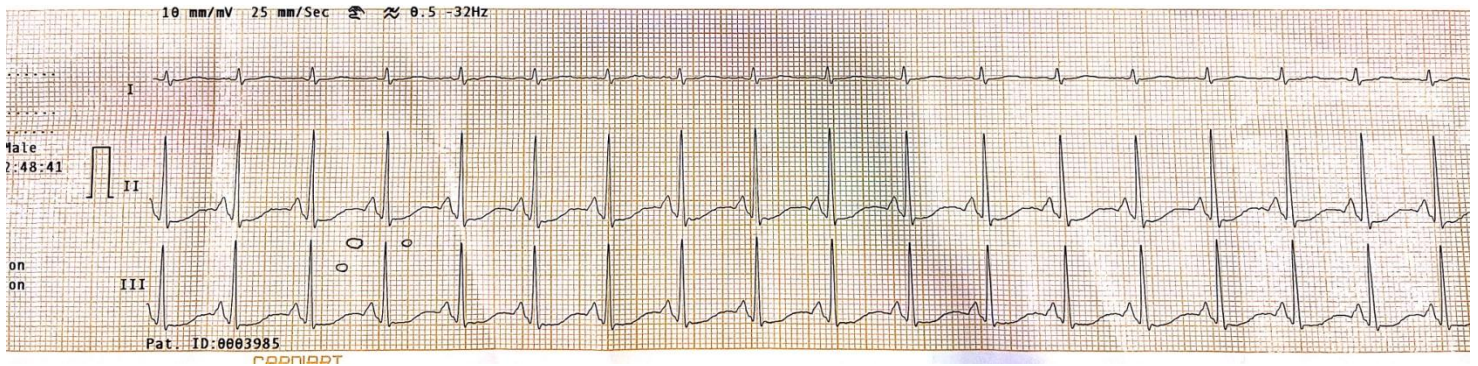
### Management :

Patient was given potassium chloride supplementation (40 mEq) intravenously at outside medical facility. Patient was started on Dopamine and Noradrenaline support and referred to our hospital.

On presentation to our hospital, patient was afebrile. He was having a pulse rate of 120 beats per minute. His blood pressure was 106/60 mmHg on Noradrenaline (0.48 mg/hour) and Dopamine (20 mg/hour) support. His respiratory rate was 18 per minute. Oxygen saturation was 100% on room air. There was no evidence of pallor, icterus or oedema. Systemic examination revealed no abnormality. Neurological examination was completely normal. On admission, patients's blood and urine samples were sent for analysis and immediate ECG was done. ECG was showing diminished T wave and prominent U wave, suggestive of hypokalemia. On ultrasound, bilateral kidneys showing raised cortical echotexture with few tiny (2-3 mm) concretions in left

kidney (10\*5.8 cm) and few simple cortical cyst (largest of size 17\*16 mm) in lower pole of right kidney (9.8\*5.9 cm). Echocardiography was completely normal. ABG was inconclusive. Urine Routine Micro was normal. ANA Profile was Negative.





INVESTIGATION	17/03/2023	19/03/2023	21/03/2023	23/03/2023	REFERENCE RANGE
Hb	12.6	12.8	12.3		13-17 gm/dl
TC	10,000	13,000	11,000		4000-11000 cells/mm <sup>3</sup>
Platelets	4.0	3.72	3.25		1.5-4.5 lacs/mm <sup>3</sup>
S. Sodium	134	138	136	137	135-145 mEq/L
S. Potassium	1.8	2.9	3.1	3.5	3.5-5.5 mEq/L
S. Chloride	96	93	91	96	98-110 mEq/L
S. Creatinine	0.6	0.6	0.7		0.6-1.3 mg/dl
S. Calcium	7.2				9-11 mg/dl
S. Magnesium	2.0				1.8-2.6 mg/dl
U. Sodium	119				40-220 mEq/L
U. Potassium	23				25-120 mEq/L
24 Hrs Urinary K			202.4		25-125 mEq/L
U. Chloride	68				110-250 mEq/L
U. Calcium		6.2			80-160 mg/L
U. Magnesium			4.4		0.4-15 mg/L
U. Creatinine		72			25-400 mg/L
U. Ca/Creat		0.08			
U. Mg/Creat			314		
U. Osmolality			215		500-800 mOsm/kg
U. Ph			6.5		4.5-7.8
S. Bicarbonate			27.2		22-26 mEq/L
S. Cortisol				15.1	8-25 mcg/dL

The patient was started on Infusion potassium chloride intravenously which continued till serum potassium became >4. Serum electrolytes were monitored 12 hourly. Patient's muscular weakness and constipation were improved with potassium supplementation. Patient was also given calcium and magnesium supplementation intravenously with which tetany improved. Gradually, Noradrenaline and Dopamine support was tapered off. Nephrology consultation was done and probable diagnosis of RTA Type II v/s Gitelman Syndrome was given.

## DISCUSSION

We have case of adult patient who was having symptoms suggestive of hypokalemia since last 3 years. After excluding pseudohypokalemia, on the basis of history, physical examination and basic laboratory tests, hypokalemia due to decreased intake and/or redistribution into cells were ruled out. 24 hour urinary potassium more than 15 millimole/day was suggestive of renal loss of potassium. TTKG (trans tubular potassium gradient) more than 4 (here, it was 7) was explaining increased distal potassium secretion. In a hypotensive patient with inconclusive acid base status and urinary chloride more than 20, an extremely low urinary calcium to creatinine ratio clinched the diagnosis of Gitelman Syndrome.<sup>[7]</sup> The tetany responded to calcium and magnesium supplementation.

In Gitelman Syndrome, loss of NCC function results in  $\text{Na}^+$  and  $\text{Cl}^-$  wasting from DCT leading to hypovolemia with secondary activation RAAS. The resulting increase in collecting tubule  $\text{Na}^+$  reabsorption is counterbalanced by  $\text{K}^+$  and  $\text{H}^+$  excretion causing hypokalemic alkalosis. The hypocalciuria is due to the associated plasma volume contraction. The renal magnesium wasting is caused by downregulation of the epithelial  $\text{Mg}^{2+}$  channel  $\text{Trpm6}$  in DCT.<sup>[8]</sup>

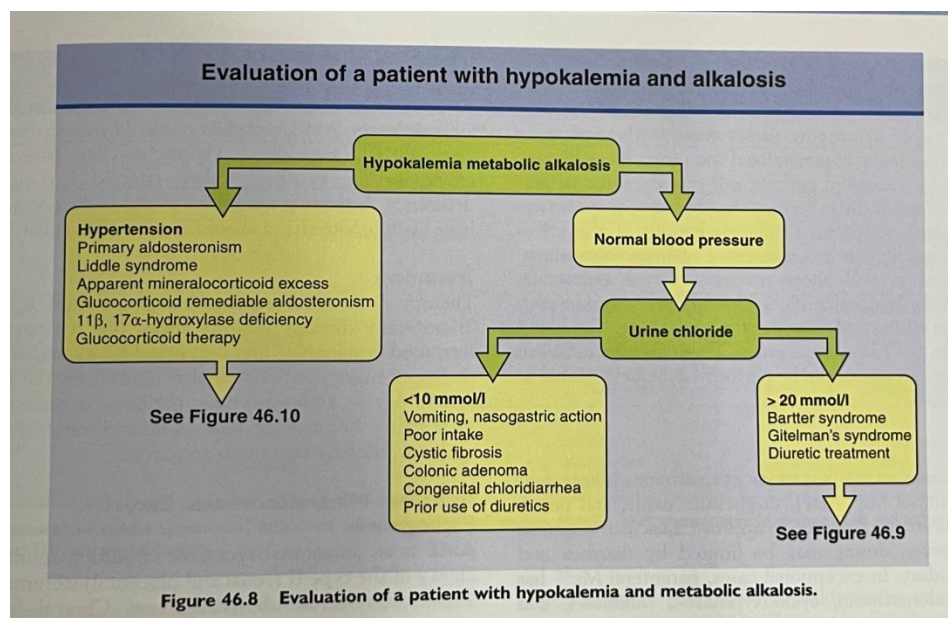


Figure 46.8 Evaluation of a patient with hypokalemia and metabolic alkalosis.

From Textbook of Comprehensive Clinical Nephrology (3<sup>rd</sup> edition)

Barter Syndrome type 3 and Gitelman Syndrome both usually present in adolescence or early adulthood. Measurement of urine calcium/creatinine ratio and urine magnesium/creatinine ratio can help differentiate between these two. Urine calcium excretion is high-normal or elevated in Barter syndrome type 3 but reduced with Gitelman syndrome. Renal magnesium wasting and hypomagnesemia are present in Gitelman syndrome but are usually not seen with Barter syndrome type 3. In absence of genetic confirmation, it can be difficult to differentiate these disorders.<sup>[4]</sup>

## **CONCLUSION**

We discussed the case of a patient who will require life long supplementation of potassium and magnesium salts. Periodically, he was developing muscular weakness associated with severe hypokalemia, improving with potassium supplementation. We can conclude that lifelong potassium supplementation would prevent the symptoms of such patients and provide a better quality of life. Carbonic anhydrase inhibitors such as Acetazolamide or a potassium sparing diuretic such as Spironolactone are also useful.

## **ACKNOWLEDGEMENT**

The authors are thankful to all faculties of Department of General Medicine, SBKS MI&RC, Dhiraj General Hospital, Sumandeep Vidyapeeth (Deemed to be University) for their inputs and continued support.

## **ABBREVIATIONS**

**GS:** Gitelman Syndrome ; **NCC** : Sodium Chloride Co-Transporter; **TTKG:** Trans Tubular Potassium Gradient ; **ECG** : Electrocardiogram; **ABG:** Arterial Blood Gas Analysis ; **DCT** : Distal Convolute Tubule ; **RAAS** : Renin Angiotensin Aldosterone System

## REFERENCES

1. Simon DB, Nelson-Williams C, Johnson Bia M, Ellison D, Karet FE, Morey Molina A, Vaara I, Iwata F, Cushner HM, Koolen M, Gainza FJ. Gitelman's variant of Barter's syndrome, inherited hypokalemic alkalosis, is caused by mutations in the thiazide sensitive Na-Cl cotransporter. *Nature genetics*. 1996 Jan 1;12(1):24-30.
2. Schmidt H, Kabesch M, Schwarz HP, Kiess W. Clinical, biochemical and molecular genetic data in five children with Gitelman's syndrome. *Hormone and metabolic research*. 2001 Jun;33(06):354-7.
3. Lee YT, Wang IF, Lin TH, Huang CT. Gitelman syndrome: report of three cases and literature review. *The Kaohsiung Journal of Medical Sciences*. 2006 Jul 1;22(7):357-62.
4. Matsunoshita N, Nozu K, Shono A, et al. Differential diagnosis of Bartter syndrome, Gitelman syndrome, and pseudo-Bartter/Gitelman syndrome based on clinical characteristics. *Genet Med*. 2016 Feb;18(2):180-8.
5. Bettinelli A, Bianchetti MG, Girardin E, et al. Use of calcium excretion values to distinguish two forms of primary renal tubular hypokalemic alkalosis: Bartter and Gitelman syndromes. *J Pediatr*. 1992;120:38-43.
6. Knoers, N. V., Levtchenko, E. N. Gitelman Syndrome. *Orphanet J Rare Dis* 3, 22 (2008).
7. *Harrison's Principles Of Internal Medicine*, 21<sup>st</sup> Edition, Vol. 1, Chapter 53, p351.
8. *Comprehensive Clinical Nephrology*, 3<sup>rd</sup> edition, chapter 46, p553-554.
9. Gitelman HJ, Graham JB, Welt LG: A new familial disorder characterized by hypokalemia and hypomagnesemia. *Trans Assoc Am Physic* 1966;79:221-235.
10. Shaer AJ: Inherited Primary Renal Tubular Hypokalemic Alkalosis: A review of Gitelman and Bartter syndromes. *Am J Med Sci* 2001;322:316-332.
11. Zelikovic I, Szargel R, Hawash A, et al: A novel mutation in the chloride channel gene, *ClCKB*, as a cause of Gitelman and Bartter Syndromes. *Kidney Int* 2003;63:24-32.
12. Simon DB, Lifton RJ: The molecular basis of inherited hypokalemic alkalosis: Bartter and Gitelman Syndromes. *Am J Physiol* 1996;271:F961-F966.
13. Corbetta S, Raimondo F, Tedeschi S, et al. Urinary exosomes in the diagnosis of Gitelman and Bartter syndromes. *Nephrol Dial Transplant*. 2015 Apr;30(4):621-30.
14. Blanchard A, Bockenhauer D, Bolignano D, et al. Gitelman syndrome: consensus and guidance from a Kidney Disease: Improving Global Outcomes (KDIGO) Controversies conference. *Kidney Int*. 2017 Jan;91(1):24-33.
15. Blanchard A, Vargas-Poussou R, Vallet M, et al. Indomethacin, amiloride, or eplerenone for treating hypokalemia in Gitelman syndrome. *J Am Soc Nephrol*. 2015 Feb;26(2):468-75.

