

Case report

Concurrent Right lung and Liver hydatidosis: An uncommon presentation-
Managed by one stage surgery

Abstract

Background

Hydatid cyst is a parasitic disease caused by larval stage of small tape worm (Echinococcus), causing cyst formation in the liver and in the lung. It affects liver primarily and secondary mostly the lungs. Hydatidosis is endemic in many countries and it is more prevalent in India. We came across a case of 4 years old female child presented with concomitant hydatidosis of the lung and liver and managed by single stage surgery involving cystotomy and partial excision for the cyst located in the lung and cystotomy, partial excision and inversion of the cavity with sutures for the cyst in the liver.

Keywords: Hydatid Cyst, Echinococcus Granulosus, Cystotomy, Single stage surgery

Introduction

Hydatid disease is a parasitic infestation caused by *Echinococcus Granulosus*. [1] Humans are infected by ingesting egg from vegetable, soil or water contaminated by the faeces of dogs [1,2]. Hydatid cysts may develop in any body organ but occur most frequently in the liver (50%–77%), lungs (18%–35%), spleen (less than 2%)

and rarely other parts of the body.[2-5] Concomitant pulmonary and liver hydatid disease may occur in 4% to 25% of patients with hydatidosis and characterized by round lesions in lungs and liver.[1] Peripheral organ hydatidosis is much less common, as few embryos can escape the capillary filtering systems of the liver and lung.[6] Here we report 4years old girl presented with concomitant lung and liver cysts managed by single stage surgery.

Case Report

A 4years-old female child presented with the history of right upper abdominal pain, recurrent respiratory infections along with off & on fever for 4-5 months. At the time of presentation, child was afebrile without any chest related signs or symptoms. On clinical examination, liver was enlarged 5cms below the right costal margin with mild tenderness. As per history of illness and physical examination, initially chest X-ray and ultrasound abdomen were suggested. Chest X-ray revealed a large dense round well demarcated opacity involving the mid zone of the right lung field with no effusion.[Figure.1a]

Ultrasound abdomen revealed well defined unilocular cystic lesion 12X10X9 cms with internal echoes involving right lobe of liver and no internal septations.[Figure.1b]

Based on chest X-ray and ultrasound abdomen findings contrast enhanced CT scan of chest and abdomen was done, that revealed hepatomegaly with large thin walled fluid filled cystic lesion of size 10.4X9X10.2 cms involving segment VI & VII of liver. Large size cyst also causing compression of hepatic ducts with indentation and displacement of 1st part of duodenum. Another similar looking lesion in anterior part

of right middle lobe causing splaying of pulmonary artery and veins.[Figure.2] All these findings and low socioeconomic strata of patient suggestive of hydatid cyst involving liver and right lung. Hydatid Serology was also done and came out positive. Child was then admitted and started on oral albendazole (4-5mg/kg/per dose) twice daily. After about a week of albendazole therapy, child started having pain abdomen with increasing intensity. So, decision was taken to explore on elective basis. Liver cysts were operated first in supine position. The edges of the wound and the surface of the liver surrounding the cyst were covered with sponges soaked in Hypertonic saline (10%) povidone-iodine solution (10%) to prevent inadvertent implantation of scolices or a daughter cyst. Huge cyst was present involving superior and posterior aspect of right lobe of liver. Cystotomy was performed to remove the germinative membrane. Partial cystectomy was also performed. Inner surface was also examined for any cysto-biliary communications. The biliary openings were sutured first. The inner surface of the cyst, the cavity along with the remaining pericystic liver tissue were inverted with sutures and filled with omentum. Drain was put in the cavity.[Figure.3] Right lung was then explored by right posterolateral thoracotomy. Huge cyst was identified involving the middle lobe. A large needle connected to the suction tip was inserted into the cyst. When the cyst was aspirated and its fluid evacuated, the most prominent part of the cyst was opened (cystotomy), and the cyst membranes were removed with sponge holding forceps. Then the cavity was irrigated with saline solution and cleaned with sponges moistened with diluted povidone-iodine. The bronchial openings were sutured. Chest drain was put in to the cavity.[Figure.3] The postoperative course was uneventful. Abdominal drain was removed on post-operative day 4 and intercostal drain was removed on post-operative day 5. Child was discharged on 7th day. In the post-operative period,

albendazole (10-20 mg/kg) was given for 6 weeks. On successive follow-ups patient was symptom free and thriving well.

Discussion

Hydatidosis is a parasitic disease caused by the tapeworm *Echinococcus granulosus*. The dog-sheep cycle is an important part for the life cycle of the parasite. On the contrary human, as an intermediate host becomes involved in this cycle when he is associated with infected dogs or by consuming contaminated water or vegetables.[6] liver is the most common site In adults, while in children it is the lung. Moreover, some patients have concomitant hepatic cysts in addition to pulmonary cysts. Concomitant pulmonary and hepatic hydatid disease may occur in 4% to 25% of cases (1,2). The right lower lobe is the most frequently affected area of the lung.[6,7] Symptoms are somewhat vague initially due to pressure effects and mainly depend upon site, size of the cyst and organ involved. Common features include pain, cough, low-grade fever, and abdominal fullness. Secondary complications may occur that include infection or rupture of the cyst [8].

Typical diagnostic techniques include ultrasound, CT scan, and MRI. The most valuable and initial diagnostic procedure is the plain chest radiograph and ultrasound abdomen. On radiographs the cysts appear as round, homogeneous, well-defined opacities and USG may suggest double wall sign or water lily appearance.[9,10] CT scan of the chest and upper abdomen is good diagnostic investigation to accurately localise and delineate the state of hydatid cyst. [7-9] These investigations are supplemented with hydatid serology.

Surgical removal remains the main form of definitive treatment. Various surgical procedures have been described in the literature, namely, excision of entire cyst by enucleation (Barrett technique), excision of pericyst (Perez Fontana), cystotomy, capitonnage, wedge resection, segmentectomy and lobectomy.[10] Intraoperative irrigation of 0.5% cetrimide, 15% hypertonic saline, and 0.5% silver nitrate solution prior to cyst opening may kill daughter cysts and further reduce the risk of dissemination and anaphylactic reaction.[8,9] We want to highlight that single-stage surgical management is safe and can be recommended to treat dual-seat hepatic and pulmonary hydatid disease with fewer complications and avoid second stage surgery as well as general anaesthesia.

Conclusion

Presence of hydatid cysts in multiple locations are not the common occurrences but still liver and lung are among the commoner sites. Early diagnosis and single stage surgical management can not only prevent complications but ensure speedy recovery as well.

Consent:

Taken from parents for data collection and submission of related information.

References

1. Aghajanzadeh M, Safarpour F, Amani H, Alavi A. One-Stage Procedure for Lung and Liver Hydatid Cysts. *Asian Cardiovasc Thorac Ann.* 2008; 16: 392-395.
2. Ghassemof H, Esfehiani RJ. Hydatid disease presented as acute abdomen, an interesting incidental finding: A case report. *Archives of Clinical Infectious Diseases.* 2015 Oct 1;10(4).
3. Dirican A, Yilmaz M, Unal B, Tatli F, Piskin T, Kayaalp C. Ruptured hydatid cysts into the peritoneum: a case series. *Eur J Trauma Emerg Surg.* 2010; 36: 375-379.
4. Gulalp B, Koseoglu Z, Toprak N, Satar S, Sebe A, Gokel Y, Sakman G, Karcioglu O. Ruptured hydatid cyst following minimal trauma and few signs on presentation. *Neth J Med.* 2007 Mar;65(3):117-8.
5. Akcan A, Akyildiz H, Artis T, Ozturk A, Deneme MA, Ok E, Sozuer E. Peritoneal perforation of liver hydatid cysts: clinical presentation, predisposing factors, and surgical outcome. *World J Surg.* 2007 Jun;31(6):1284-91.
6. Singal R, Sandhu KS, Mittal A, Gupta S, Jindal G. - A giant splenic hydatid cyst. *Proc (Bayl Univ Med Cent)* 2016;29:55–57.
7. Aytaç A, Yurdakul Y, Ikizler C, Olga R, Saylam A. Pulmonary hydatid disease: report of 100 patients. *The Annals of Thoracic Surgery.* 1977 Feb 1;23(2):145-51.

8. Smego RA, Smego DR: Management of Human Echinococcosis: Review of Surgical and Medical Approaches. Pakistan Journal of Surgery. 1987, 3: 29-34.
9. Haliloglu M, Saatci I, Akhan O, Ozmen MN, Besim A. Spectrum of imaging findings in pediatric hydatid disease.
10. Raymond A S, Douglas R S. Management of human echinococcosis: review of surgical and medical approaches.

UNDER PEER REVIEW

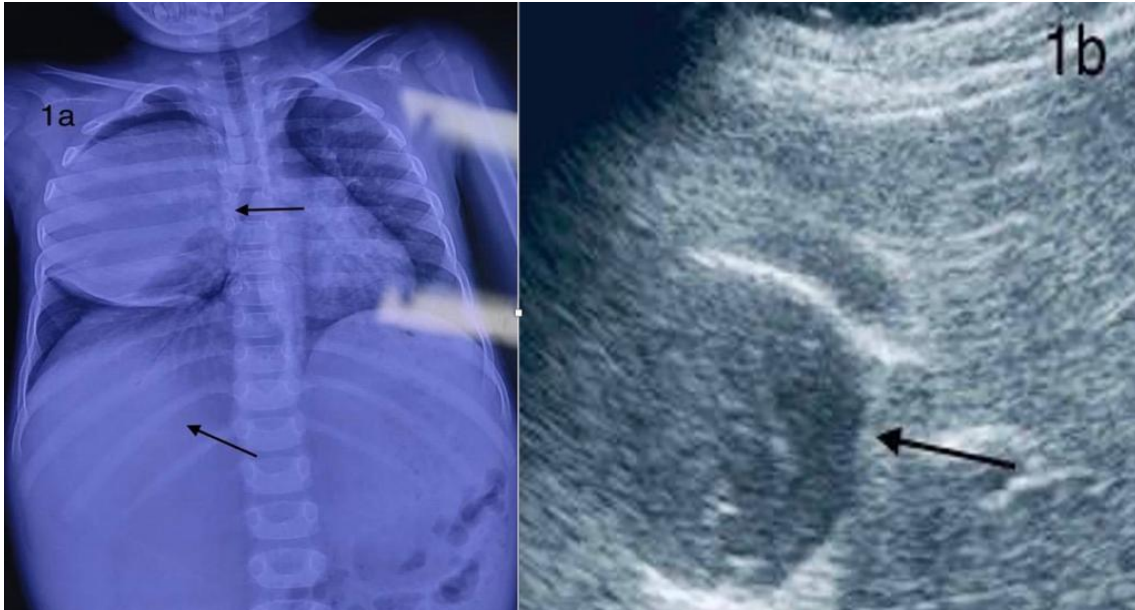

Figure.1a. Chest X-ray revealed a large dense round well demarcated opacity involving the right lung field and opaque homogenous zone of cyst in right upper abdomen (marked by arrows), 1b. Ultrasound abdomen revealed well defined unilocular cystic lesion with internal echoes and no internal septations (marked by arrow)

UNDER PEER REVIEW

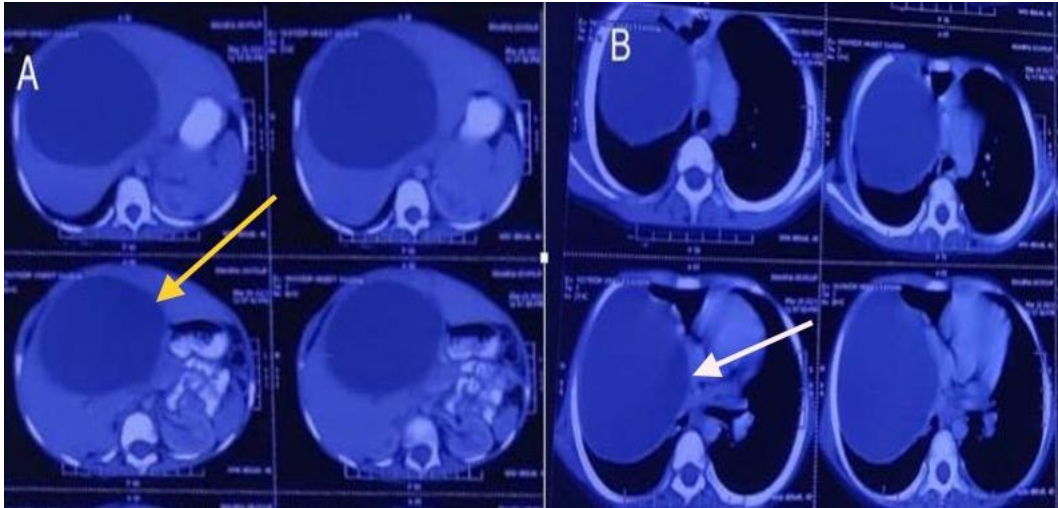


Figure.2 (A-C) Contrast enhanced CT scan revealed hepatomegaly with large thin walled fluid filled cystic lesion of involving right lobe of liver (yellow arrow). Another similar looking lesion in anterior part of middle lobe of right lung (white arrow)

UNDER PEER REVIEW

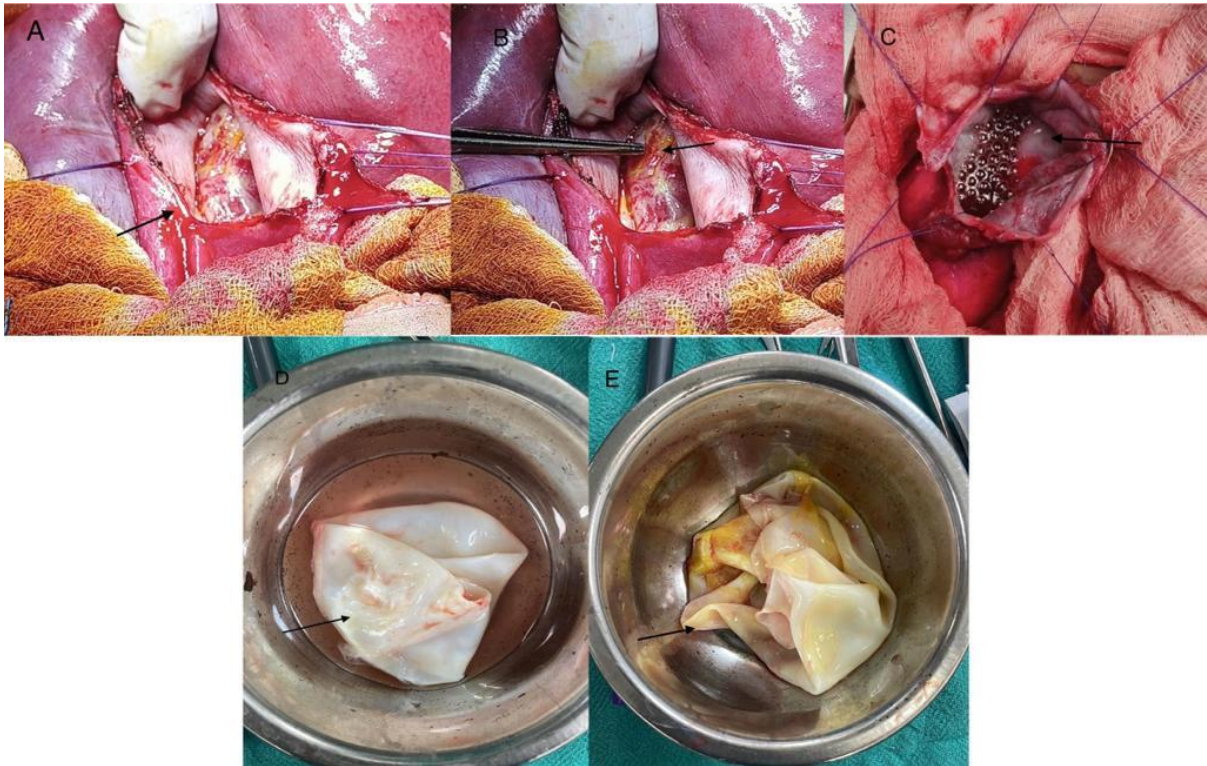


Figure.3 (A-E) A. Cyst involving right lobe of liver. Cystotomy was performed to remove the germinative membrane. B. Inner surface of cyst showing cysto-biliary communication indicated by bile staining (marked by arrow). C. Cyst involving right lung. Cystotomy was performed and air bubbles from bronchial connections can be observed. D-E Membrane removed from lung and liver cysts respectively.

UNDER REVIEW