

Bullous Wells syndrome responsive to low-dose dapsone

ABSTRACT

Wells' syndrome (WS) is an uncommon inflammatory dermatosis of unknown etiology which typically presents with pruritic cellulitis-like plaques on the extremities. The condition is thought to be a hypersensitivity reaction developing against a variety of exogenous and endogenous antigenic stimuli. Although the classic plaque type variant is the most common presentation, bullous, papulonodular, papulovesicular, granuloma-like, urticarial-like and fixed drug eruption types may be encountered as well. Histopathology is characterised by tissue eosinophilia, edema and flame figures. Treatment options include topical and systemic corticosteroids, topical calcineurin inhibitors, doxycycline, cetirizine, cyclosporine, TNF- α inhibitors and PUVA. Here, we present a case of bullous WS presenting with subcorneal pustule formation responding to low-dose dapsone treatment.

Key words, Eosinophilic cellulitis, Wells syndrome, Bullous Wells syndrome, dapsone

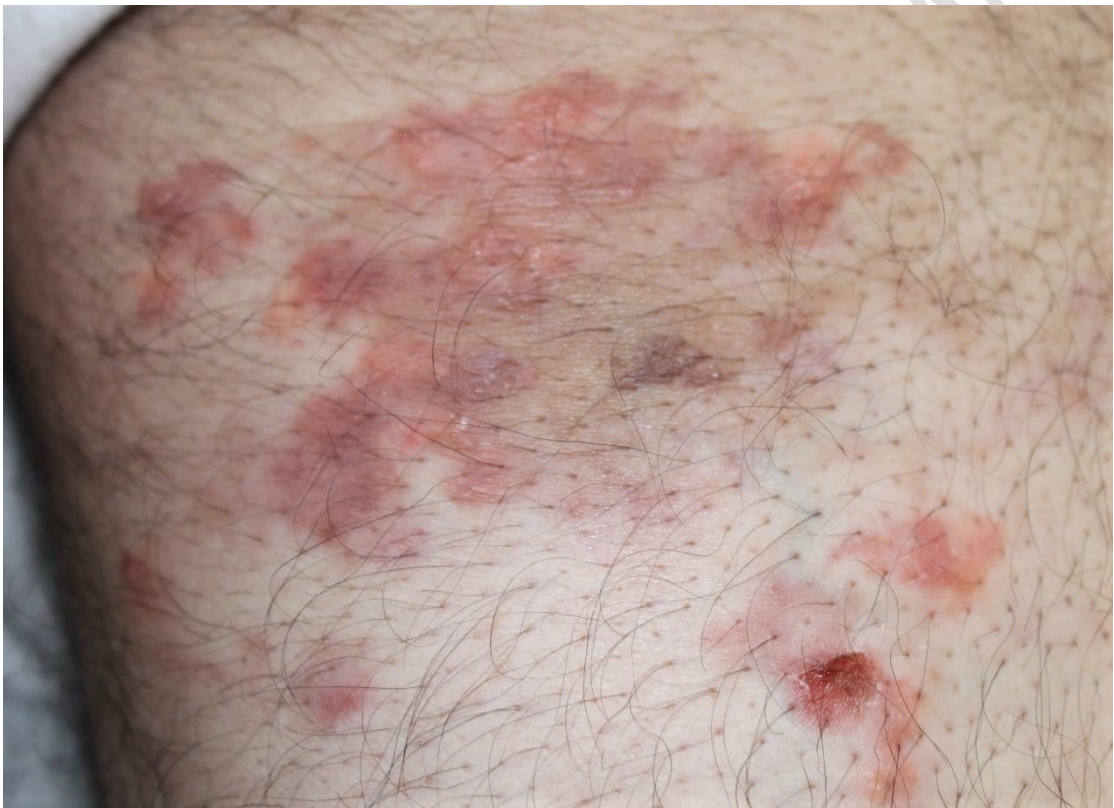1. INTRODUCTION

Eosinophilic cellulitis also called Wells' syndrome (WS) is an inflammatory dermatosis of unknown etiology which usually presents with cellulitis-like plaques^{1,2}. There are several clinical variants of WS: The most common variant is the plaque type; bullous, papulonodular, papulovesicular, urticaria-like, granuloma-like and fixed drug eruption types are other variants². The disease is thought to be a hypersensitivity reaction against a variety of exogenous and endogenous antigenic stimuli^{1,2,3}. Here, we present a case of bullous WS responding to low-dose dapson.

2. CASE PRESENTATION

A sixty-year-old man presented to the dermatology clinic with two plaques on the right leg which had developed nine months ago. The lesions were slightly pruritic. He had been treated with various topical corticosteroids and antihistamines with little improvement. The medical history was unremarkable and he was not on any medications. Physical examination demonstrated erythematous, violaceous plaques located to the posterior femoral area on the right leg. Bullae were also present on the plaques (Fig 1a). Complete blood count showed mild eosinophilia (5%, 440/mm³); serum biochemistry, IgE levels, protein electrophoresis, anti-HIV, anti nuclear antibody and anti neutrophilic cytoplasmic antibodies were in the reference range. Imaging studies including a chest X-ray and abdominal ultrasound were normal. Histopathological evaluation revealed widespread epidermal spongiosis with vesicle formation and lymphocyte exocytosis. Edema and an inflammatory infiltrate consisting of polymorphonuclear leucocytes and eosinophils were noted in the superficial dermis in addition to perivascular and peridnexial mononuclear inflammatory cells in the deep dermis (Figure 2 a,b). Direct immunofluorescence was negative. A diagnosis of WS was made based on the clinical and histopathological findings.

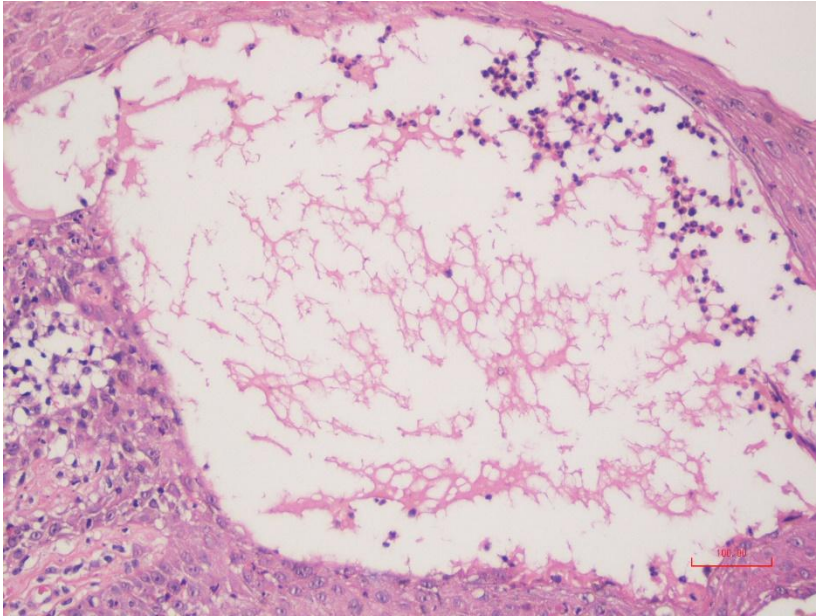
The patient was started on dapsone 25 mg/day and the dose was increased to 50 mg/day in a week; since serum transaminase levels increased (AST:46, ALT:117) the dosage was reduced to 25 mg/day and the enzyme levels normalized with dosage reduction. Improvement began in 3 weeks. The patient received dapsone 25 mg/day for 4 months and the lesions resolved with postinflammatory hyperpigmentation (Fig. 1b). He was followed for a year without any recurrences.



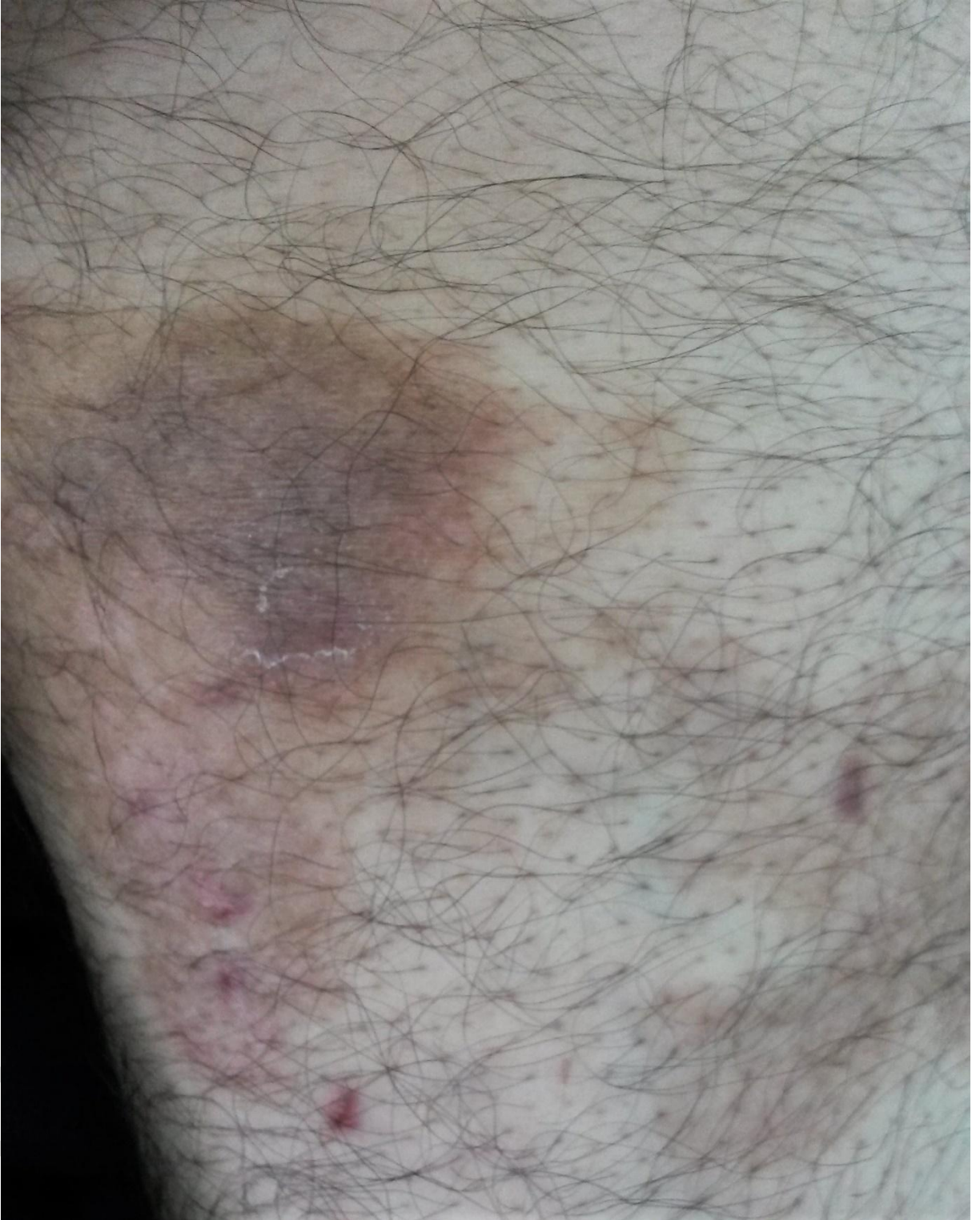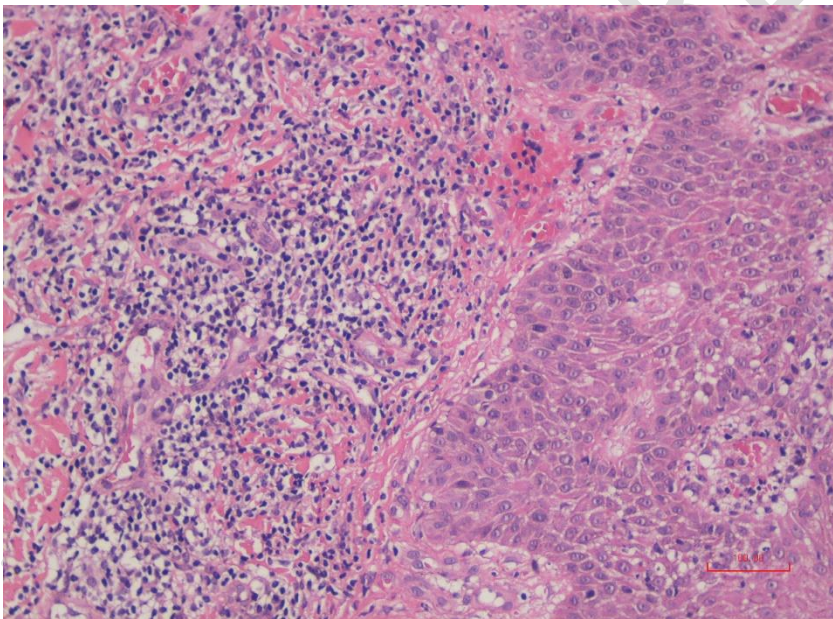


Fig.1 (a). Erythematous plaques with papules, vesicles, and bullae on the leg.

(b). Improvement of the lesion with postinflammatory hyperpigmentation after dapsone treatment.



(a)



(b)

Fig.2 (a). Spongiotic vesicle, fibrin, and mixed inflammatory cells composed of eosinophils, polymorphonuclear leukocytes and lymphocytes (H&E x200).

Legend (b). Inflammatory infiltrate consisting of polymorphonuclear leucocytes and eosinophils in perivascular and interstitial areas and erythrocyte extravasation in dermis (H&E x200).

3.DISCUSSION

WS is a cutaneous disorder characterized clinically by mildly pruritic or tender plaques resembling cellulitis with a typical histology characterized by tissue eosinophilia, edema and flame figures^[2,4]. Although the etiology is unknown, the disease is thought to be a hypersensitivity reaction against a variety of exogenous and endogenous antigenic stimuli such as infections, parasitic infestations, arthropod bites, vaccines hematological disorders, solid tumors or medications^{1,3}. The pathogenesis of the disease is unknown; immunophenotyping studies of peripheral T cells have shown increased CD3+ and CD4+ T cells⁴. These lymphocytes spontaneously release interleukin-5, which drives eosinophilic accumulation in a Th2 immune response⁵. There are also reports claiming an association between WS and rare multisystem eosinophilic disorders such as Churg-Strauss syndrome and hyper eosinophilic syndrome^{2,6}.

Three histopathological stages are characterised in WS: the acute stage is characterized by edema and eosinophilic infiltration of the dermis followed by a subacute stage with an infiltration of histiocytes and flame figures which correspond to collagen fibers coated with eosinophilic granules.^{1,2} Flame figures are not pathognomonic as they are observed in other eosinophilic dermatoses.^{1,7} Epidermal reaction ranges from a normal epidermis to minimal to moderate epidermal spongiosis, with or without vesiculation⁵. The healing stage demonstrates histiocytes and giant cells forming palisading granulomas with few eosinophils being present^{1,2}. In our case, flame figures were not observed.

The differential diagnosis of WS is wide and includes bacterial cellulitis, arthropod bites, chronic urticaria, bullous pemphigoid, fixed drug eruption, erythema chronicum migrans, Sweet's syndrome, hypereosinophilic syndrome, and Churg-Strauss syndrome^{1,2}. The bullous

presentation of WS is rare in the literature, and an association with lymphoproliferative diseases has been described in previous reports⁸. A search for underlying malignancy did not yield any results in our patient. It is recommended that such cases be monitored for the development of hemato-oncological diseases⁵.

Topical and systemic steroids, topical tacrolimus, dapsone, cetirizine, doxycycline, minocycline, griseofulvin, interferon alpha and gamma, antimalarial drugs, colchicine cyclosporine, azathioprine, adalimumab, omalizumab and PUVA have been used in the management of WS with variable results^{2,3,7,9}. In our case, we administered low-dose dapsone due to mild elevation of transaminases. It is proposed that dapsone inhibits eosinophilic peroxidase which is a cytotoxic granule protein of eosinophils that induces mast cell degranulation. As a result, eosinophilic peroxidase mediated tissue injury is prevented¹⁰.

4. CONCLUSION

WS is a rare disease; because of few case reports and periodic course of the disorder characterized by exacerbations and remissions it is difficult to deduce whether a treatment is effective or not. Our case demonstrates that dapsone might be an effective treatment option in the management of WS, even in low doses.

CONSENT We received the patient's consent form about publishing all photographic materials

References

1- Heelan K, Ryan JF, Shear NH, Egan CA. Wells syndrome (eosinophilic cellulitis): Proposed diagnostic criteria and a literature review of the drug-induced variant. *J Dermatol Case Rep* 2013; 7: 113-120.

- 2- Räßler F, Lukács J, Elsner P. Treatment of eosinophilic cellulitis (Wells syndrome) - a systematic review. *J Eur Acad Dermatol Venereol* 2016;30:1465-1479.
- 3- Bokotas C, Kouris A, Stefanaki C, Sgotzou T, Christofidou E, Kontochristopoulos G. Wells Syndrome: Response to Dapsone Therapy. *Ann Dermatol* 2014 Aug; 26: 541–542.
- 4- Plötz SG, Abeck D, Behrendt H, Simon HU, Ring J. Eosinophilic cellulitis (Wells syndrome). *Hautarzt* 2000; 51:182-186.
- 5- Lim CE, Ng SK, Thng ST. Bullous Presentation of Idiopathic Wells Syndrome (Eosinophilic Cellulitis). *Ann Acad Med Singapore* 2017;46: 324-326.
- 6- Fujimoto N1, Wakabayashi M, Kato T, Nishio C, Tanaka T. Wells syndrome associated with Churg-Strauss syndrome. *Clin Exp Dermatol* 2011; 36 :46-48.
- 7- Coelho de Sousa V, Laureano Oliveira A, Cardoso J. Successful treatment of eosinophilic cellulitis with dapsone. *Dermatol Online Journal*. 2016; 22(7).
- 8- Spinelli M, Frigerio E, Cozzi A, Garutti C, Garavaglia MC, Altomare G. Bullous Wells' syndrome associated with non-Hodgkin's lymphocytic lymphoma. *Acta Derm Venereol*. 2008; 88: 530-531.
- 9- Egeland Ø, Balieva F, Undersrud E: Wells syndrome: a case of successful treatment with omalizumab. *International Journal of Dermatology* 2018, 57, 994–995.
- 10- Bozeman PM, Learn DB, Thomas EL. Inhibition of the human leukocyte enzymes myeloperoxidase and eosinophil peroxidase by dapsone. *Biochem Pharmacol* 1992; 44: 553–

UNDER PEER REVIEW