

Case study

Tuberculous osteomyelitis presenting as a sternal mass in paediatric patient: A case report

Abstract :

Background : Sternal tuberculosis is an uncommon form of extrapulmonary tuberculosis and it can be a diagnostic challenge for pediatricians.

Case presentation : We report the case of a young 14-year-old boy, who had a gradually increasing swelling of the sternum over the past 2 months preceded by weight loss, asthenia and night sweats. Radiological, histological, and microbiological investigations confirmed it as a case of sternal tuberculosis (TB). He was managed with surgical debridement during the sternal biopsy and quadruple antituberculous therapy with good response.

Discussion : Tuberculosis (TB) of the sternum is one of the rarest forms of skeletal tuberculosis. The incidence of sternal tuberculosis has been calculated to be <1.5% among sterno-articular tuberculosis, with very few cases reported in infants. The diagnosis is based on histological and bacteriologic arguments.

Conclusion : Tuberculous osteomyelitis of the sternum is a rare finding in children. Our aim is to increase awareness around atypical presentations and the uncommon involvement of the sternum in musculoskeletal tuberculosis.

Key words: tuberculosis, musculoskeletal, sternum, swelling, osteomyelitis, infants.

Introduction :

Tuberculosis continues to be a worldwide public health problem. Tuberculosis presenting as sternal swelling is an unusual presentation in the pediatric population. Around 164 cases of sternal tubercular osteomyelitis have been reported in scientific literature till date. The incidence of sternal tuberculosis has been calculated to be <1.5% among sterno-articular tuberculosis, with very few cases reported in infants. Due to its subtle signs and symptoms, early diagnosis of this entity becomes a challenge. This case illustrates the unusual presentation of a child with a sternal swelling. A combination of history, examination and an extensive panel of investigations revealed a diagnosis of sternal tuberculosis.

Case presentation :

A 14-year-old boy, with no previous medical history or hospital admission, Bacille Calmette–Guérin (BCG) vaccination received at birth, an anterior contact with a case of pulmonary tuberculosis in the family was noted in the previous 6 months. He was admitted to the military training hospital of Rabat in Morocco, for chest pain and a painful sternal mass over the anterior chest wall in creasing gradually the volume over the last 2 months, preceded by manifesting constitutional symptoms of weight loss of 4 kg for 4 months, asthenia and profuse night sweats. There was no history of fever, cough, breathing difficulties, rash or any local traumatism noted.

Clinical examination revealed a small round mass over the upper 1/3 of the sternum on the horizontal medio-mamelon line, measuring 4 cm* 2 cm, with no signs of local inflammation, renitent consistency and painful on palpation (Fig.1). No pallor or lymphadenopathy was observed. The rest of the physical examination was normal.

The initial blood tests

demonstrated microcytic hypochromic anemia with the elevated erythrocyte sedimentation rate (ESR) of 120 mm and C-reactive protein (CRP) of 92. The patient's TB Quantiferon Gold test was positive.

Radiological imaging described the sternal mass and

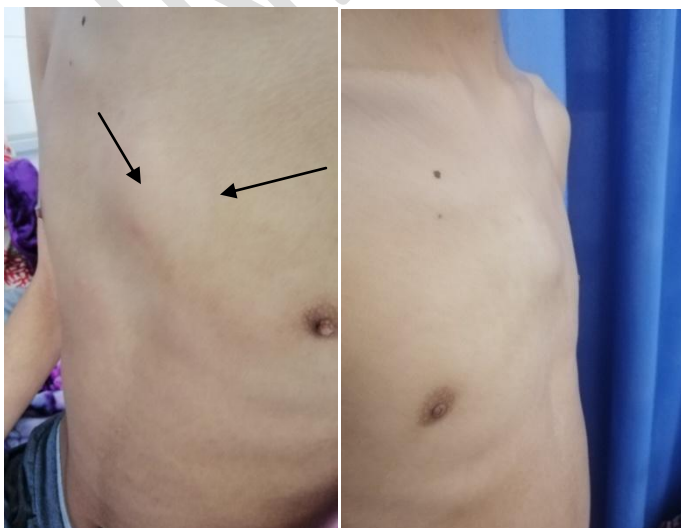pulmonary lesions suggesting tuberculosis infection.

Chest X-ray revealed a systematized heterogeneous left medio-thoracic opacity with mediastinal enlargement (Fig.2). Chest CT showed a lytic image of the sternal body measuring 28*53mm suggesting an abscess with infiltration of the mediastinum and soft tissue opposite, a systematized condensation image of the left lung associated with interstitial micronodules, and multiple mediastinal adenopathies (Fig.3).

Histological study of sternal biopsy showed areas of granulomatous inflammation with focal abscesses, and caseous necrosis (Fig.4). After immediate histological results, a complement with a debridement of the sternal lesion was done. Bacteriological examination using PCR-BK (GeneXpert) in the gastric tube and sternal biopsy revealed the presence of mycobacterium tuberculosis.

The evolution was marked by the appearance of intermittent back pain with no limitation of the vertebral joints and no functional impotence, and normal neurological examination. A CT scan of the cervico-dorso-lumbar spine revealed a layered lytic involvement of the cervical and mainly dorsal spine.

It was concluded that this was a multifocal form of tuberculosis, revealed by the initial sternal lesion. The patient was commenced on quadruple antitubercular treatment for 12 months: isoniazid, rifampicin, ethambutol hydrochloride and Zinamide. He has been clinically well and showing good signs of improvement, with the sternal swelling significantly decreasing in size then completely resolved (Fig.5).



A

B

Fig.1Anterior(A) and lateral (B) view of the sternal chestswelling(shownbyarrows)

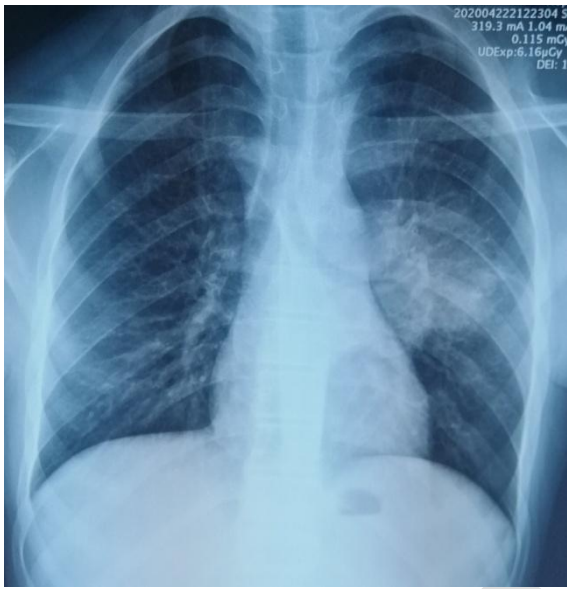
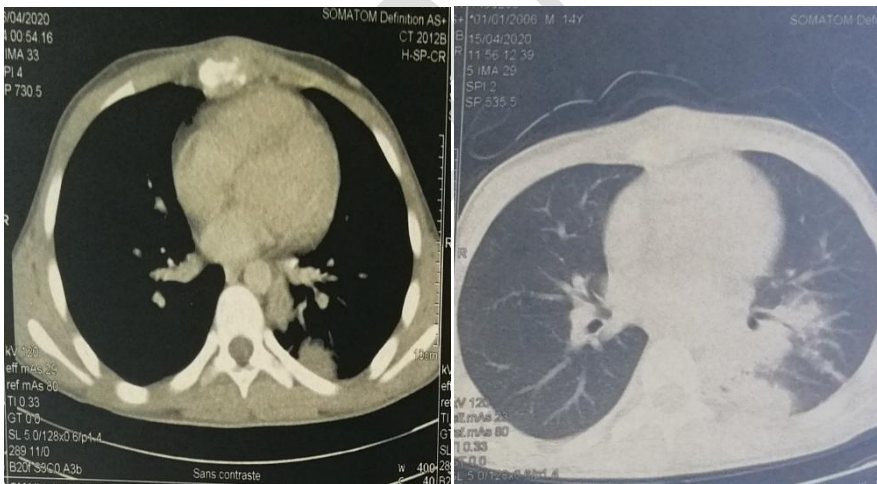


Fig.2. X-Ray chest : systematizedheterogeneousleft medio-thoracicopacitywithmediastinalenlargement



A

B

Fig.3.Computedtomography imagesdemonstrating the image of lyticpresterallesionwithinfiltration of the mediastinum and soft tissue opposite (A), and a systematized condensation image of the leftlungassociatedwithinterstitial micronodules (B).

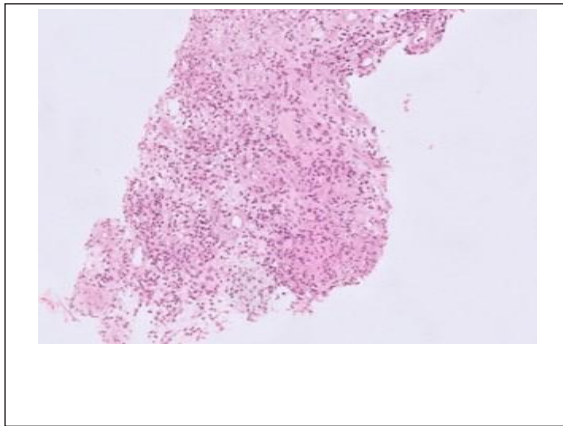


Fig.4. Histological study of sternal biopsy showed areas of granulomatous inflammation and caseous necrosis.

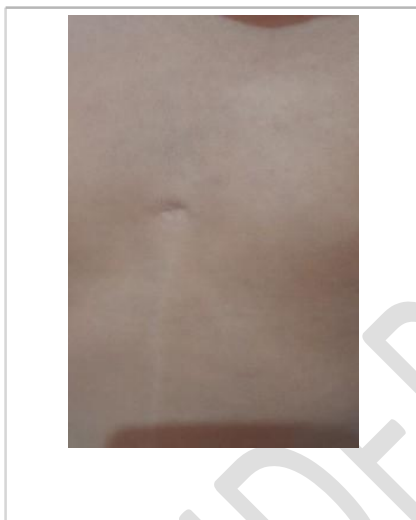


Fig.5. Post-treatment clinical image showing a sternal scar 6 months of treatment

Discussion :

Tuberculosis is an endemic disease of the undeveloping world, however more cases are now being reported from developed countries [1]. The increased rate in cases can be related to large-scale population migration and reactivation tuberculosis in the immigrant population.

In Morocco, a total of 29,327 cases have been notified and put on treatment in 2021, as part of the National Tuberculosis Control Program (PNLAT), and the young population, aged between 15 and 45, remains the most exposed. Furthermore, the scale of extra-pulmonary tuberculosis (48% of notified cases) and the emergence of multi- and ultra-resistant forms of tuberculosis represent a major public

health in our country [2][3]. The statistical data on the frequency of sternal tuberculosis are lacking, some cases only of adults have been reported in scientific publications.

Musculoskeletal tuberculosis represents 2–5% of all cases of tuberculosis and is usually seen in older children and adolescents. It primarily affects in 60-80% of cases the spine, hip or knee joint, and small joints of the hands and feet [3].

The involvement of the sternum is rare, it occurs in < 1% of all musculoskeletal tuberculosis. Sternal tuberculosis can affect children from all ages. Out of the 164 cases of sternal tubercular osteomyelitis reports till date, a 6 month- old- boy is the youngest patient reported in literature, but the majority of pediatric cases were older children or adolescents presenting a swelling or an ulcer over the sternum [4][5]. Some of these children had other sites of involvement as seen in our case. Therefore every patient admitted for sternal tuberculosis should be systematically evaluated for disease at other sites [6].

The contamination can result commonly from reactivation of the latent loci of mycobacterium, direct spread from hilar lymph nodes, hematogenous, or lymphatic dissemination from primary sites [6]. Pathogenesis mechanisms include phagocytosis of the tubercular bacilli by the alveolar macrophages and subsequent bacteremia which leads to dissemination of the mycobacteria at different sites including bone and joints. The infection of bone and joint occurs several years after tuberculosis infection. However, recently many publications reported shorter incubation periods as seen in our patient [7].

Tuberculosis should be considered as a differential diagnosis for a sternal swelling. Chest wall tuberculosis can mimic other non specific bacterial infections, malignancy, and lymphomas. The development of bone lymphoma is generally slow, and constitutional symptoms such as weight loss, night sweats and itching are usually more reported in tuberculosis cases [8][9].

The diagnostic should include radiology first (USG and MRI) followed by cytology or histology evidence. Chest radiography is not specific in detecting early bone lesions, periostitis, osteopenia, or fractures. CT scan and Magnetic resonance imaging (MRI) scan can detect abscess formation, bone marrow invasion and its extension to soft tissue mass, even better and previously with the MRI [10].

The diagnosis is confirmed on histological and bacteriological studies of material of aspiration or biopsy. Microbiologic confirmation by PCR-BK and TB culture is strongly recommended, it plays a key role in early diagnosis and also provides information on rifampicin sensitivity [11]. Debridement of the affected tissue and histopathological examination are the gold standard in diagnosing atypical presentations of sternal tuberculosis.

The management of sternal tuberculosis cases is based primarily on the medical treatment. The standard regime is 2HRZE and 10HRE [12]. Surgical drainage or debridement should be considered in case of non response of the abscess to medical management. Some reports state that the cure rate was approximately 95% with medical therapy alone, while others report that over 25% required concomitant surgical intervention [13]. A periodic follow up is necessary to assess response to treatment and drug resistance, and to monitor possible complications. The outcomes were universally good with medical therapy despite delayed diagnosis.

Conclusion :

Sternal tuberculosis is a rare entity, reported in older children, adolescents, and adults and is very uncommon in infants. High index of suspicion in the presence of lytic lesions, whether or not associated with soft-tissue collections, and detailed diagnostic work up are required for early diagnosis and management of infantile sternal tuberculous osteomyelitis.

Consent

As per international standard, parental written consent has been collected and preserved by the author(s).

Ethical Approval:

As per international standard or university standard guideline participant consent and ethical approval has been collected and preserved by the authors.

References :

- [1]. Vijay V, Vaishya R. Isolated C-C joint tuberculosis—a diagnostic dilemma. *Foot (Edinb)*. 2015;25:182–6.
- [2]. Bouytse K, Benamor J, Bourkadi J. Facteurs de risque et diagnostic de la tuberculose au Maroc. *Rev des Mal Respir Actual*. 2021;13(1):227.
- [3]. Aziz Ouarssani, Fouad Atoini, Fatima Ait Lhou , Mustapha Idrissi Rguibi. La tuberculose sternale: à propos de 2 cas. *Pan African Medical Journal*. 2012.
- [4]. Shah MM, Gupta G, Modi P, Baldev S, Prajapati. Infantile sternal tuberculosis: A rare condition. *Indian Pediatr Case Rep* 2021;1:170-2.
- [5]. Bains L, Lal P, Chand T, Gautam KK, Beg MY, Kumar P. Isolated primary cold abscess of the sternum: A case report. *J Med Case Rep* 2019;13:267.
- [6]. Kutty S, Bennett D, Devitt A, Dowling FE. Tuberculous osteomyelitis of the sternum in an infant: a case report and review of the literature. *Focus on Tuberculosis Research*. 2005:181.
- [7]. Smith I. Mycobacterium tuberculosis pathogenesis and molecular determinants of virulence. *Clin Microbiol Rev* 2003;16:463-96.
- [8]. Calabro E, Pastorino U. Primary sternal tuberculosis mimicking a lytic bone tumor lesion. *Monaldi Arch Chest Dis*. 2018;88:931.
- [9]. Joshi P, Bavdekar SB, Save SU. A swelling over sternum in a child: Reminder of an uncommon diagnosis. *Case Rep Pediatr* 2016;2016:3765786.
- [10]. Atasoy C, Oztekin PS, Ozdemir N, et al. CT and MRI in tuberculous sternal osteomyelitis: A case report. *Clin Imaging* 2002;26:112-5

[11].Wen H, Li P, Ma H, Lv G. Diagnostic accuracy of Xpert MTB/RIF assay for musculoskeletal tuberculosis: A meta-analysis. *Infect Drug Resist* 2017;10:299-305.

[12].Asif A, Dabral L. Sternal Tuberculosis: Case Series of Two Cases. *Journal of Orthopaedic Case Reports* 2021 November;11(11): 59-63.

[13].Rajan and Bizanti, Sternal swelling presenting as tuberculosis: a case report, *Journal of Medical Case Reports* (2021) 15:580.

UNDER PEER REVIEW