

## Case report

# A Giant Primary Hydatid Cyst Of Spleen– A Case Report

### Abstract

Hydatid cysts are caused by a tapeworm *Echinococcus granulosus*. It is endemic disease in cattle-rearing areas of south America, Africa, Middle east, South Europe, India, Australia and New Zealand. The life cycle of *Echinococcus* includes a definitive host dog and intermediate host is sheep, goats or swine. Humans are incidental hosts.

The most common site of disease is the liver 60-70%, followed by lungs 30%, spleen, kidney, pancreas, bones, brain and muscles are rarely affected. Spleen is the third most common organ involved in hydatid cyst disease. Berlot in 1790 was the first to describe splenic hydatid cyst as an autopsy finding. Hydatid cyst of spleen is a very rare clinical condition as even in the endemic region, the incidence reported is to be 0.5-4% of abdominal hydatid diseases. Primary splenic hydatid cyst is very rare and account for 2% of the patients.

The majority of treatment for a splenic hydatid cyst is surgery. To lower the risk of sepsis, patients should obtain vaccinations against pneumococcal, haemophilus influenzae, and meningococcal infections at least two weeks before and again after surgery. This is medical prophylaxis with albendazole.

Here in we report a rare case of huge splenic hydatid cyst successfully managed surgically. 20 years old female patient with the complaints of left hypochondriac pain and huge splenomegaly. There was history of pet dog handling and we performed total open splenectomy.

### Keywords

*Echinococcus granulosus*, Primary splenic hydatid cyst, Splenomegaly

### Introduction

“Hydatid disease is a zoonosis caused by larval stage of the cestode worm *Echinococcus granulosus* or dog’s tape worm. Most of the larvae are trapped in the liver (first leman’s filter) to form liver hydatid cysts and a small fraction of the released larvae to reach the lungs (second leman’s filter) forming pulmonary hydatid cysts and very small fraction of the released larvae bypass both filters and are distributed to different organs including spleen, kidney, pancreas, bones, brain, thyroid and mesentery” (1,2,3).

“The first clinical presentation of splenic hydatid cyst is usually an accidental discovered mass in the abdomen, mostly in left hypochondrium. Pain usually a dull dragging ache is often the first clinical sign or dyspnea due to pushing up of the left diaphragm. Spontaneous or traumatic rupture of splenic hydatid cyst is reported and life threatening complication like anaphylaxis and shock” (2,3,4,11).

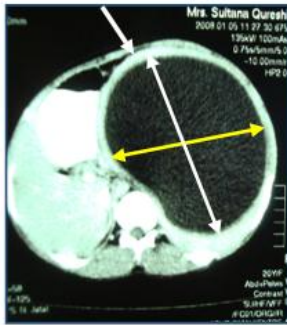### Case Presentation

A 20 years old female was admitted to our centre on 05/01/2008 with complaints of dull aching pain at left hypochondrium and huge lump in left upper quadrant abdomen extending up to umbilicus for two years. She had history of contact with pet dog for 5 years. On physical examination of patient, there was palpable intra-abdominal lump of size 15x10 cm, lump was non tender, firm and cystic with smooth surface, extending from left hypochondrium up to the umbilicus and it moves with deep inspiration. Routine laboratory tests were normal and her serological test for hydatid cyst were positive. CT abdomen showed a well-defined, thick wall intra-abdominal cystic lesion of size 20x20x18 cm in the spleen with a thin rim of splenic parenchyma was noted around the cyst. Cyst was unilocular containing hydatid sand.

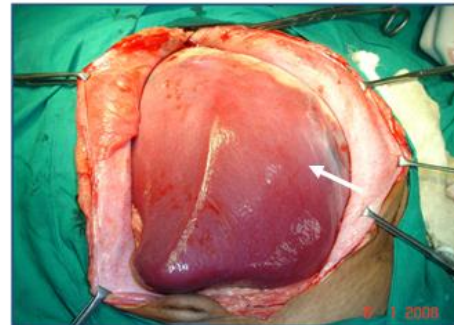
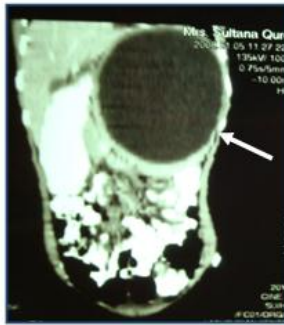
Preoperatively, vaccination against pneumococcus, haemophilus influenzae and meningococcus along with albendazole 400 mg twice day was given 2 weeks before the planned operation. Explorative laparotomy revealed a giant intra-abdominal cyst of size 20x20x18 cm occupying the entire splenic parenchyma and spleen was firmly adherent to left hemi-diaphragm. Huge cyst was compressing medially to stomach, left kidney pushing down and pancreas behind. Rest of the abdominal organs including liver were normal. Povidine iodine solution 10% was used a scolicidal agent and cotton sponges were soaked to prevent the recurrence. The splenic pedicle with vessels were secured first. The spleen was removed along with a massive splenic cyst. The cyst was removed concurrently with a complete splenectomy. There was no leaking of cyst contents during surgery. Little blood was lost. The abdominal incision was closed with sutures after povidine iodine was used to clean the peritoneal cavity. The recovery time went without incident. After surgery, albendazole treatment was continued for an additional two months. A year of patient monitoring revealed no recurrence.

**(Figures 1-8)**

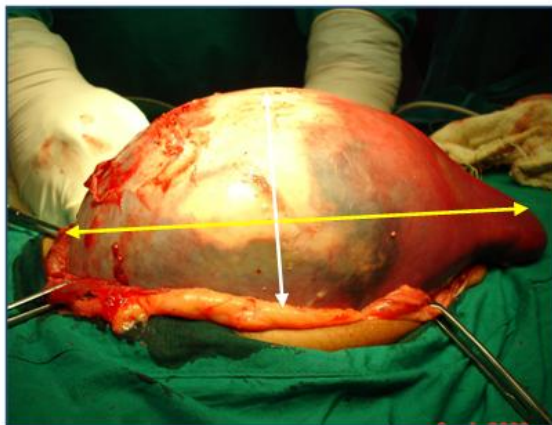
On gross examination specimen a huge splenic cyst of 20x20x18 cm in size and weight 3 kilogram. Histopathological examination showed classical laminated cyst wall (**Fig 7**) with scolices and hooklets, confirming echinococcus granulosus infection.



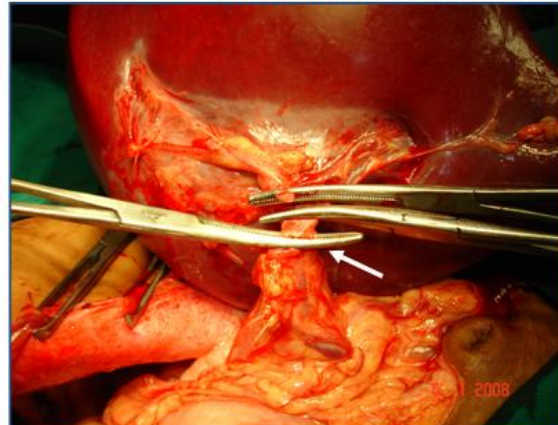
**Fig-1 CT Abdomen showing solitary cystic lesion in spleen of size 20x20x18 cm**



**Fig-2 Intra operative photographs showing huge splenomegaly**



**Fig-3 Intra operative photographs showing a huge splenic hydatid cyst of size 20x20x18 cm**



**Fig-4 Intra operative photographs showing a ligation of splenic artery and vein (Pedicle)**

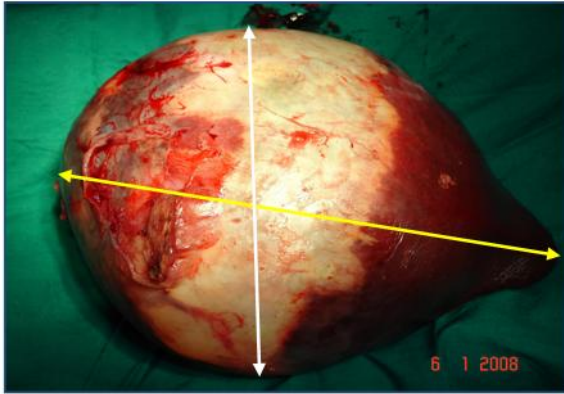


Fig-5 Photographs showing total splenectomy with splenic hydatid cyst of size 20x20x18 cm & weight 3 kilograms

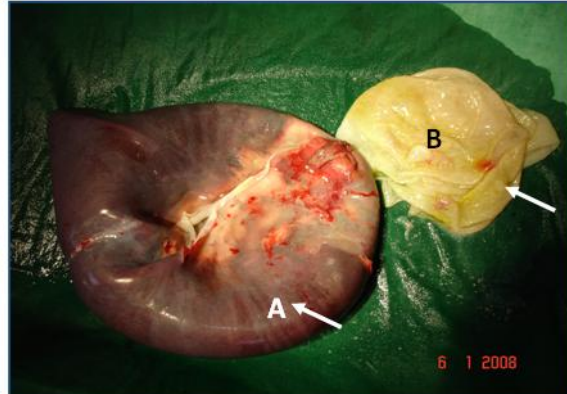


Fig-6 Photographs showing A- Total splenectomy specimen B- Hydatid endocyst.

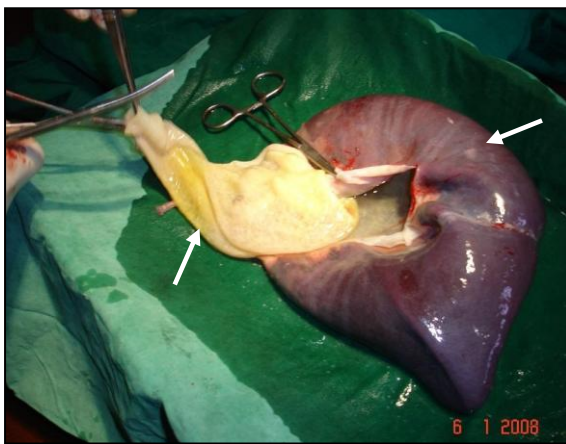

Fig-7 Gross specimen showing glistening white endocyst wall along with spleen

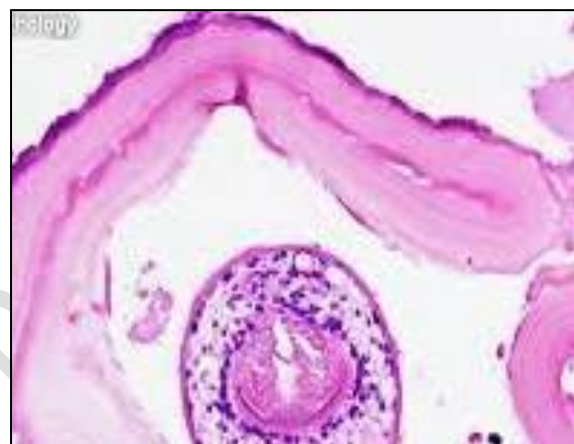

Fig-8 Showing classical laminated hyaline cyst wall with scolices

## Discussion

Patients of splenic hydatid cyst remains asymptomatic for 5-20 years before the diagnosis is made. Hydatid disease is generally incidentally detected up to 30% during radiological investigation. “The symptoms complaints produced by splenic hydatid cyst are mainly abdominal pain and palpable mass in the left upper quadrant. There can be dyspnea due to pushing up to the left diaphragm. Complication such as traumatic or spontaneous rupture of hydatid cyst may cause a life threatening complication of systemic anaphylactic shock have been reported” (2,4,5).

“Epidermoid cyst, Pseudocyst, haematoma, splenic abscess and cystic neoplasms are considered as differential diagnoses of primary splenic hydatidosis. Ultrasonography is the first line option for abdominal hydatidosis, its sensitivity for evaluating hydatid cyst is 90-95% and specificity is 93-100%. CT scan is more sensitive than abdominal ultrasound. Diagnosis of splenic hydatidosis can be successfully in more than 90% of all cases by USG and CT combined with immunological tests such as IHA, ELISA and Immunoelectrophoresis” (1, 2,3).

“Surgery is the mainstay of treatment for hydatid disease of the spleen. Total splenectomy for patients with large cysts located centrally or near the hilum is the ideal treatment. Laparoscopic splenectomy is not applicable to big sized cyst. Conservative surgery such as partial splenectomy is indicated in children’s and cysts localized to one pole of the spleen. Medial prophylaxis with albendazole should be given to patients perioperative as well as during the first six months after surgery to prevent to recurrence” (4,5,6).

## Conclusion

Even in endemic places, splenic hydatid cysts are a fairly uncommon clinical condition. The preferred course of treatment for big and central splenic hydatid cysts affecting the hilar region is total splenectomy. However, in cases of shallow cysts, cysts that are localized in one pole, and in youngsters, partial splenectomy is advised. To lower the likelihood of recurrences, perioperative immunization and albendazole medication should be advised.

## Ethical approval

As per international standard or university standard written ethical approval has been collected and preserved by the author(s).

## Consent

As per international standard or university standard, patient(s) written consent has been collected and preserved by the author(s).

## References

1. Merad Y, Derrar H, Zeggai A, Chadli M, Bemrah N, Habachi B. Primary splenic hydatid cyst an unexpected diagnosis: Case report. *Ann Med Surg (Lond)*. 2021 Apr 20;65:102293. doi: 10.1016/j.amsu.2021.102293. PMID: 33996047; PMCID: PMC8091878.
2. Singh, Sampurnaa, Kisee, Shreejaa; Amatya, Suprabhaa; Singh, Santoshb; Bista, Shiwania; Shrestha, Rajana; Thapa, Milan Kumar Chhantela. A case of giant primary splenic hydatid cyst: Case report. *Annals of Medicine & Surgery* 84(0); December 2022. | DOI: 10.1016/j.amsu.2022.104829
3. Ghabisha S, Ahmed F, Al-wageeh S, Al-shami E, Al-naggar K, Chowdhury U, Haider N, Al-yousofy F. Isolated Giant Primary Splenic Hydatid Cyst in a 10-Year-Old Boy: A Case Report. *Pediatric Health Med Ther*. 2021;12:55-59  
<https://doi.org/10.2147/PHMT.S295280>
4. Kishor Manandhar. Primary splenic hydatidosis. *Journal of Patan Academy of Health Sciences*. 2018 Dec;5(2):70-73.
5. Malik, A.A., ul Bari, S., Younis, M. et al. Primary splenic hydatidosis. *Indian J Gastroenterol* 30, 175–177 (2011). <https://doi.org/10.1007/s12664-011-0104-x>
6. Yotsov, Tsanko Ivelinov, Dyulgerova, Stela, and Draganova, Daniela, 2022, "Laparoscopic splenectomy for solitary splenic hydatid cyst: Case report" *Journal of Minimal Access Surgery* Vol. 0, No. 0, pp 0, 0972-9941
7. Belli S, Akbulut S, Erbay G, Koçer NE. Spontaneous giant splenic hydatid cyst rupture causing fatal anaphylactic shock: A case report and brief literature review. *Turk J Gastroenterol* 2014; 25: 88-91.
8. Dr. SAJAL GUPTA, Dr. PRABHU SHANKAR, Dr. AMIT GARG, Primary Hydatid Cyst of Spleen - A Rare Entity, *IOSR Journal of Dental and Medical Sciences (IOSR-JDMS)* e-ISSN: 2279-0853, p-ISSN: 2279-0861. Volume 21, Issue 2 Ser.6 (February. 2022)

9. MERAD Zakaria, Solitary Splenic Hydatid Cyst, Journal of Clinical and Diagnostic Pathology, Volume 1, Issue 4, 2021, Pages 1-4, ISSN 2689-5773, <https://doi.org/10.14302/issn.2689-5773.jcdp-21-3890>.
10. Bayramov, NuruYusifoglu, Mammadov, RuslanAydinoglu, and Gahramanova, Farah Afilqızı, 2021, Prophylactic Surgery pp 133, 978-3-030-66853-2
11. Singh S, Kisee S, Amatya S, Singh S, Bista S, Shrestha R, Thapa MK. A case of giant primary splenic hydatid cyst: Case report. Annals of Medicine and Surgery. 2022 Dec 1;84:104829.

UNDER PEER REVIEW