

# **Chronic total occlusion of coronary left main artery supplied by right collaterals under vascular endothelial growth factor inhibitor therapy**

## **Abstract**

We report a rare case of a patient who despite being under anti VEGF :Bevacizumab , developed a large coronary collateral circulation completely supplying the chronic total occlusion of left main coronary artery

Bevacizumab, a monoclonal antibody was the first potent angiogenicinhibitor , targeting vascular endothelial growth factor (VEGF)-A

Some of it's important cardiovascular adverse events include arterial and venous thrombotic events, coronary artery disease and heart failure resulting from inhibition of endothelial regeneration.

Our patient developed dyspnea after 1 year of receiving bevacizumab with a chronic total occlusion of the left main coronary artery with the particularity of developing extensive collaterals despite the anti VEGF treatment she received.

**Key words**-coronary artery disease, vascular endothelial growth, myocardial dysfunction, Bevacizumab

## Introduction :

The progression of solid tumors necessitates an adequate blood supply achieved through the development of new vessels. This process hinges on various factors, including humoral agents like vascular endothelial growth factor (VEGF). Beyond its role in tumor growth, VEGF holds significance in cardiovascular biology as it influences vascular tone modulation, safeguards endothelial cells, and promotes collateral circulation amid ischemic events [1]. Inhibitors of angiogenesis work by either selectively countering VEGF (via antibodies) or inhibiting its receptors (through tyrosine kinase inhibitors).

Hence, all angiogenesis inhibitors, such as bevacizumab, entail potential cardiovascular complications, encompassing hypertension, thromboembolism, and, in certain instances, even myocardial dysfunction. In this context, we present an extraordinary case: a patient who, despite receiving anti-VEGF treatment

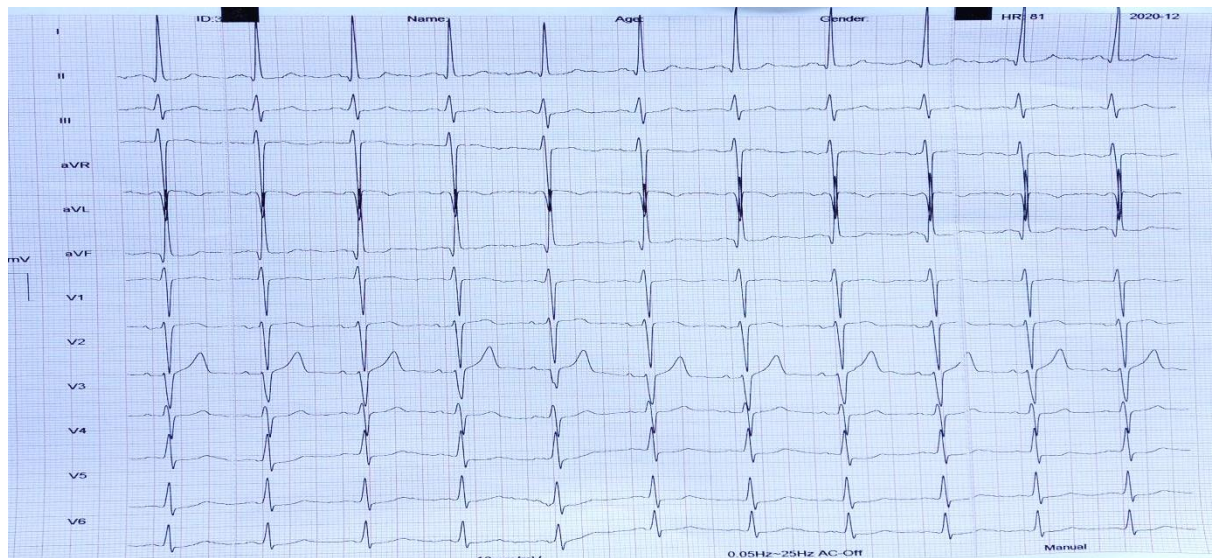in the form of bevacizumab, exhibited the development of an extensive coronary collateral network that entirely supplied a chronically occluded left main coronary artery.

### **Case presentation :**

We present a case involving a 54-year-old female patient with a medical history of diabetes mellitus managed through metformin. The patient had rectal adenocarcinoma that had metastasized to the liver. Initially, local symptoms and rectal bleeding were managed through radiation therapy. Subsequently, the patient was initiated on a chemotherapy regimen, initially receiving two courses of Capecitabine 1000mg/m<sup>2</sup> + oxaliplatin 130 mg/m<sup>2</sup>, followed by a total of eight courses of Capecitabine 1000mg/m<sup>2</sup> + Bevacizumab 7.5mg/kg over the course of a year.

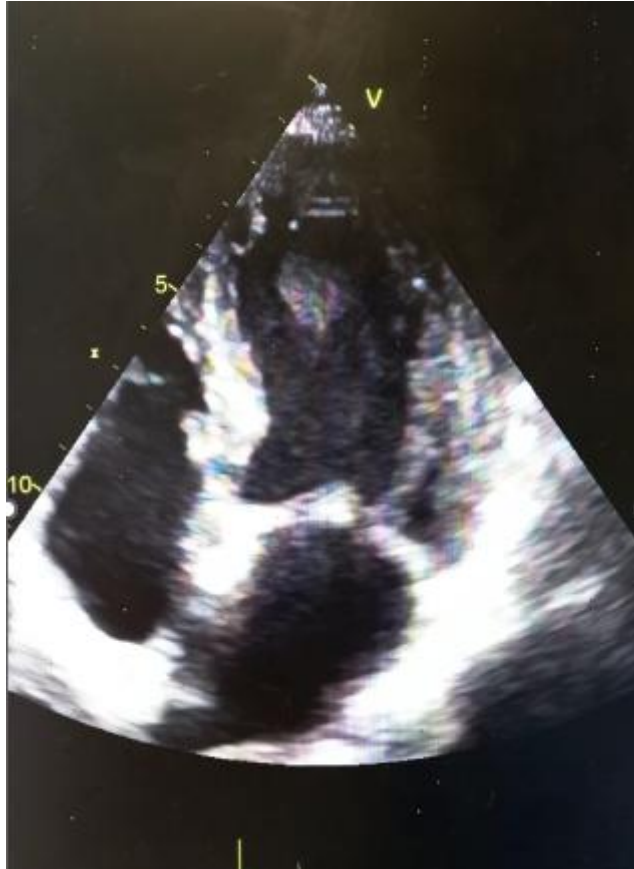Throughout the treatment duration, the patient underwent quarterly cardiac evaluations and transthoracic echocardiography in the cardio-oncology unit, with no previously noted abnormalities. However, during the most recent cardiac consultation, the patient reported experiencing new-onset progressive dyspnea and intermittent chest pain. Her vital signs were within normal ranges, including a respiratory rate of 20/min, oxygen saturation of 95% on ambient air, blood pressure of 110/73 mmHg, and a pulse rate of 85 bpm.

Physical examination did not reveal wheezing, jugular venous distension, or pedal edema. The electrocardiogram (EKG) tracing displayed sinus rhythm, a gradual progression of R wave in anterior leads, and no significant ST segment depression (Figure 1).



**Figure 1 :** EKG tracing displayed sinus rhythm, a slow progression of R wave in anterior leads along with 0.5 mm ST segment depression in apical and lateral leads

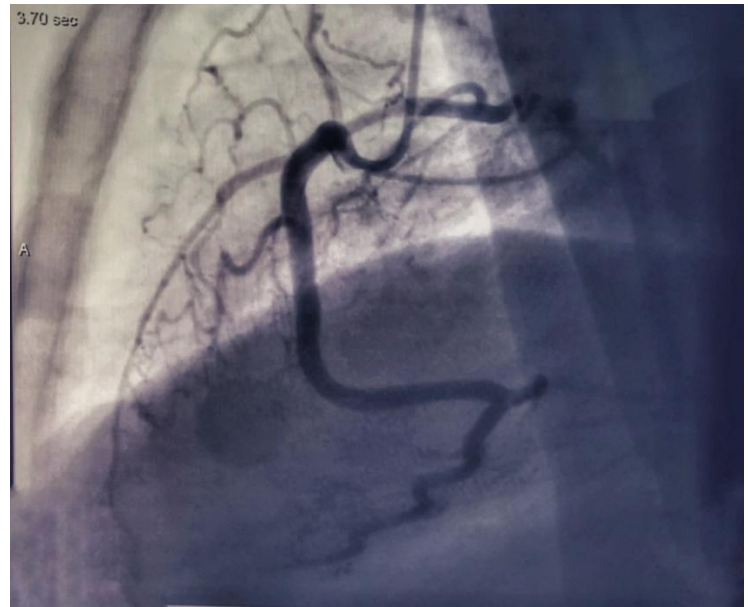
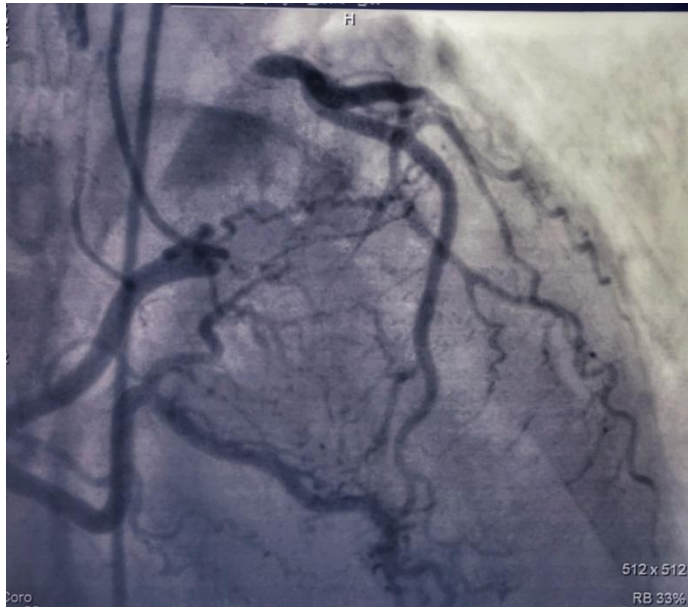Transthoracic echocardiography indicated a reduced left ventricular ejection fraction of 42%, down from 62% three months prior. This reduction was accompanied by impaired regional systolic contractility in the apical and anterior segments, along with significant intracavitary contrast (Figure 2).



**Figure 2 :** Transthoracic echocardiography showing a reduced left ventricular ejection fraction of 42% with impairment of regional systolic contractility interesting apical and anterior segments associated with an intense intracavitary contrast

Laboratory tests revealed a notably elevated brain natriuretic peptide (BNP) level of 1697 pg/ml (normal range: 0–100 pg/ml) and an initial troponin level of 0.05 ng/ml (normal range: < 0.04 ng/ml).

Confronted with this clinical scenario, a coronary angiography was performed, revealing a chronic occlusion of the left main coronary artery. This occlusion was characterized by complete refilling of the left coronary system through extensive collateral development from the right coronary artery (Figure 3).



**Figure 3:** Chronic total occlusion of the left main coronary artery with complete refilling of the left coronary system from the right coronary artery from extensive collateral development

A multidisciplinary team, including oncologists, cardiologists, and interventional cardiologists, discussed the patient's management. The decision was made to alter the chemotherapy regimen by discontinuing capecitabine and bevacizumab, while continuing with oxaliplatin alone. Additionally, the patient was placed on antiplatelet therapy and cardioprotective therapy involving Angiotensin-converting enzyme (ACE) inhibitors and beta-blockers.

To mitigate the risk of thromboembolism given the context of intense intracavitary contrast, a three-month anticoagulation regimen based on low molecular heparin was introduced.

Subsequent follow-ups at three and six months revealed symptom control and an improvement in dyspnea. There was a modest enhancement in the left ventricular ejection fraction (LVEF), which increased to 50%.

### **Discussion**

Bevacizumab, a monoclonal antibody and the pioneering potent angiogenic inhibitor, targets vascular endothelial growth factor (VEGF)-A. It has found extensive application in colorectal cancer, non-

squamous cell lung cancer, and metastatic renal cell carcinoma, playing a pivotal role in chemotherapy regimens aimed at enhancing survival [2]. Nonetheless, concerns have arisen regarding cardiovascular toxicities and the safety of its use, particularly among the elderly population.

One of the foremost cardiovascular side effects associated with bevacizumab is hypertension, which manifests shortly after treatment initiation and, in severe cases, may lead to decompensation. Effective control of blood pressure often necessitates the administration of antihypertensive medications (such as calcium antagonists and ACE inhibitors). In some instances, discontinuation of bevacizumab might be required [3].

Additional noteworthy cardiovascular adverse events linked to bevacizumab comprise arterial and venous thrombotic incidents, coronary artery disease, and heart failure. These consequences arise from the inhibition of endothelial regeneration. An analysis of five randomized trials involving 1,745 patients with metastatic colon cancer, lung cancer, and metastatic breast cancer revealed that coronary syndromes occurred in 1.5% of the bevacizumab group compared to 1% in the control group [4]. These events can manifest at any point, with a median occurrence time of roughly 3 months. Importantly, they do not correlate with the dose or cumulative dose of bevacizumab. These occurrences are believed to result from diminished endothelial cell regenerative capacity, exposure of subendothelial collagen, and activation of tissue factor [4].

Our patient experienced dyspnea one year after initiating bevacizumab treatment, with a chronic total occlusion of the left main coronary artery. Notably, despite receiving anti-VEGF treatment, the patient exhibited an unusual characteristic of extensive collateral development, leading to the dominance of the right coronary network.

However, whether VEGF inhibition impairs vascular adaptation in coronary ischemia remains uncertain [5], as does whether bevacizumab directly influences myocardial contractility. The intricate interaction of the VEGF family with the human body is marked by duality in its functions, often yielding contrasting outcomes in target tissues even when stimulated by the same factor. In practical terms, a certain degree of angiogenesis contributes to cardiac recovery from hypoxia, but an excess may destabilize atherosclerotic plaques [6].

As a result, there is currently no consensus advocating the use of antiplatelet agents or anticoagulants for prophylactic purposes due to the potential bleeding risks associated with bevacizumab [3].

Conclusion :

Certain anti-angiogenic therapies, including bevacizumab, have demonstrated adverse impacts on the cardiovascular system. Despite a substantial rise in the relative risk of cardiovascular side effects, the

resulting slight excess risk remains relatively minor compared to the inherent risks associated with the tumor progression itself.

Therefore, it becomes imperative to gauge and evaluate this risk, effectively balancing it against the anticipated benefits of these agents. This assessment underscores the importance of collaborative efforts between cardiologists and oncologists, fostering enhanced prevention, screening, and management strategies for such toxicities.

### **Consent**

As per international standard or university standard, patients' written consent has been collected and preserved by the author(s).

### **Ethical Approval:**

As per international standard or university standard guideline participant consent and ethical approval has been collected and preserved by the authors.

### **References:**

- 1 Meier P, Gloekler S, Zbinden R, Beckh S, de Marchi SF, Zbinden S, et al. Beneficial effect of recruitable collaterals: a 10-year follow-up study in patients with stable coronary artery disease undergoing quantitative collateral measurements. *Circulation*. 2007;116(9):975–83.
- 2 Ranpura V, Hapani S, Chuang J, et al. Risk of cardiac ischemia and arterial thromboembolic events with the angiogenesis inhibitor bevacizumab in cancer patients: a meta-analysis of randomized controlled trials. *ActaOncol* 2010;4:287–97.
- 3 Gordon MS, Cunningham D. Managing patients treated with bevacizumab combination therapy. *Oncology*. 2005;69(Suppl 3):25–33.
- 4 Scappaticci FA, Skillings JR, Holden SN, et al. Arterial thromboembolic events in patients with metastatic carcinoma treated with chemotherapy and bevacizumab. *J Natl Cancer Inst* 2007;99:1232–9.
- 5 Zhu X, Wu S, Dahut WL, Parikh CR. Risks of proteinuria and hypertension with bevacizumab, an antibody against vascular endothelial growth factor: systematic review and meta-analysis. *Am J Kidney Dis*. 2007;49(2):186–93.
- 6 Zhou, Yan et al. "The Role of the VEGF Family in Coronary Heart Disease." *Frontiers in cardiovascularmedicine* vol. 8 738325. 24 Aug. 2021, doi:10.3389/fcvm.2021.738325