

Case report

AN UNCOMMON PRESENTATION OF AXIAL TORSION WITH ISCHEMIC PERFORATION OF MECKEL'S DIVERTICULUM

ABSTRACT

Introduction

Meckel's diverticulum (MD) is the commonest congenital anomaly of the gastrointestinal tract due to incomplete obliteration of the vitellointestinal duct. Most of the patients were asymptomatic with only 4% of them presented with complications. Axial torsion leading to ischemic perforation of MD is a rare presentation with only few cases reported in the literature.

Case summary

A 25 year old man presented with two days acute severe abdominal pain with evidence of peritonism over the lower abdomen. He was posted for an urgent laparotomy with a preoperative diagnosis of perforated appendicitis. An emergency laparotomy was performed and there was axial torsion of the MD with purulent peritonitis. The MD had a narrow base with a length of 6cm and was attached anteriorly via a mesodiverticular band. A wedge resection with primary repair was performed with peritoneal lavage. Patient recovered well and was discharged home seven days after the surgery. The histopathological report of the specimen was consistent with ischemic perforation without evidence of malignancy.

Discussion

Axial torsion is a rare complication of MD with clinical presentation mimicking other common intra-abdominal pathology. The diagnosis is usually made intraoperatively as the current imaging modalities are still yet to be reliable in diagnosing such condition. Factors associated with higher risk of complications include patient with age of less than 50 years, presence of anatomic risk factors such as length of more than two cm, palpable abnormality and presence of fibrous band. Current recommendation suggests excision for all symptomatic MD and asymptomatic MD found during abdominal exploration with risk factors of developing complications. It is important to include complicated MD in our differential diagnosis for patient with such presentation in order to identify and manage accordingly.

Keyword: Meckel's diverticulum (MD), perforated MD, axial torsion of MD

INTRODUCTION

Meckel's diverticulum (MD) was described by a German Anatomist, Johann Friedrich Meckel in the early 19th century. (1) It is the commonest congenital anomaly of the gastrointestinal tract due to incomplete obliteration of the proximal portion of the vitellointestinal duct during the fifth to seventh week of fetal development. (2) Failure of obliteration of the whole tract will result in an umbilical fecal fistula while proximal ductal closure will lead to an umbilical sinus and distal closure will lead to Meckel's diverticulum. (3) The mesodiverticular band connecting to the umbilical ligament used to function as the developmental viteline arteries. (4) MD is usually found on the anti-mesenteric border of ileum, with 90% locating within 90cm of the ileocaecal valve. The "rule of two" classically used to describe the features of MD: 2% of the population with male to female ratio 2:1, locating two feet from the ileocaecal valve and can be 2 inches in length; and 2-4% of patients tend to develop complication and often occurs at two years of age. It is usually lined by two different types of mucosae which are the native intestinal mucosa and a heterotopic mucosa commonly gastric or pancreatic mucosa. (5,6)

Of all Meckel's diverticulum, majority are asymptomatic while only 4% present with complications such as intestinal obstruction (36.5%), intussusception (13.7%), inflammation (12.7%), perforation (7.3%), haemorrhage (11.8%) and tumour (3.2%). (8) Axial torsion with gangrenous Meckel's diverticulum is an uncommon complication with several cases reported in the past. We hereby present a case of strangulated Meckel's diverticulum with ischemic perforation secondary to axial torsion.

CASE SUMMARY

A 25-year-old Malay male, who was previously well with no past surgical history presented with central abdominal pain for 2 days associated with 4 episodes of vomiting and fever. On examination, he was septic and tachycardic, abdominal examination showed tenderness over lower abdominal region with guarding with intact hernial orifices were intact and normal male genitalia. Blood investigation showed leucocytosis of 21.5 with a CRP of 220. Abdominal and chest radiographs showed a gas filled pouch at the right upper part of the abdomen with no pneumoperitoneum.

We proceeded for a laparotomy and intraoperatively there was a long strangulated gangrenous narrow base Meckel's diverticulum at 40cm proximal to the ileocecal junction with ischemic perforation and purulent peritonitis. The Meckel's diverticulum was twisted on its base with a fibrous band connecting to the anterior abdominal wall. We performed a wedge resection of the Meckel's diverticulum and primary repair of the small bowel along with peritoneal lavage. Patient recovered well and was discharged home at day 7 post surgery. The histopathological report of the specimen was consistent with perforated ischemic bowel with no evidence of ectopic mucosa or malignancy.

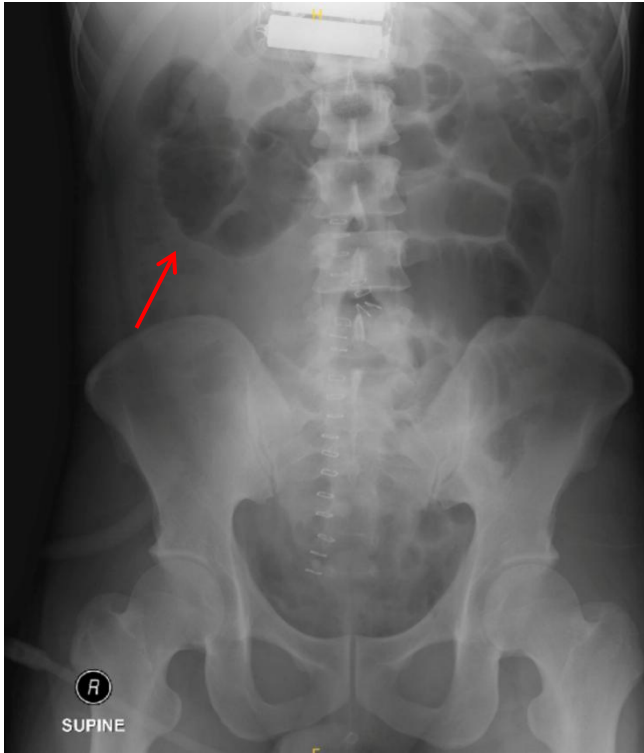


Image 1: Abdominal X-ray revealed a gas filled segment of bowel at the right upper part of abdomen. (Red arrow)

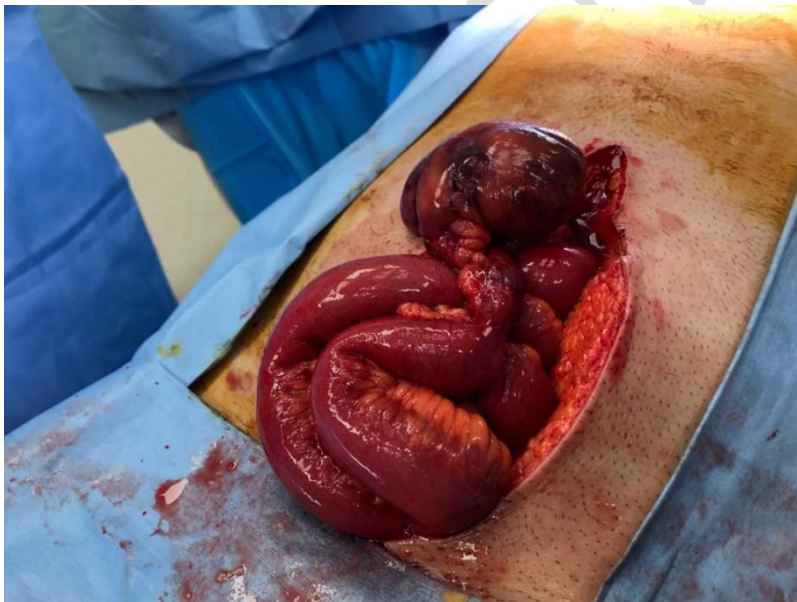

Image 2: Intraoperative finding of a strangulated Meckels diverticulum secondary to axial torsion on its base with purulent peritonitis

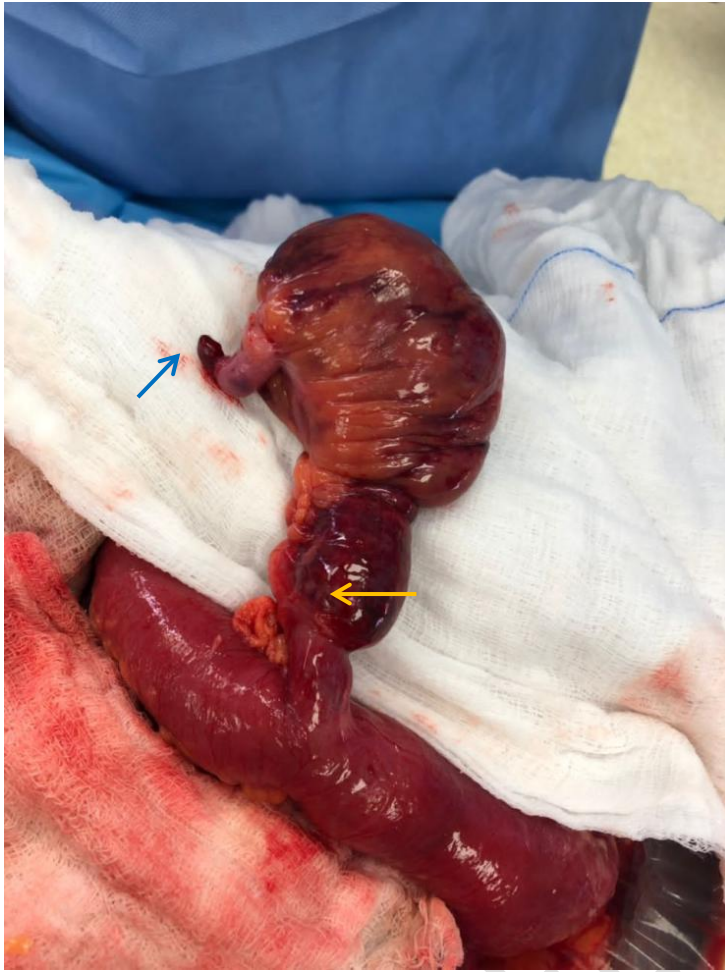

Image 3: Meckel's diverticulum with mesodiverticular band (blue arrow) and narrow base (yellow arrow)

DISCUSSION

This case demonstrated an unusual case of axial torsion of MD. Based on the available literature, there are several risk factors, primary neoplasm of MD with both malignant and benign histology is associated with increased risk. With a larger size of the MD, it will lead to potential complications such as intussusception with the tumour as a lead point, mechanical bowel obstruction, volvulus and axial torsion. However, it is rare with only less than 1% of the incidence. (9) The presence of fibrous vitelline band connecting to the anterior abdominal wall is also a risk factor for torsion of MD, especially with longer length of band and narrower base. (10)

The commonest presentation with such condition is always abdominal pain with preoperative diagnosis including appendicitis, small bowel obstruction, cholecystitis or diverticulitis. (11) In addition, the mobility and variation of MD has made radiological imaging less helpful in determining the diagnosis. Therefore, most of the time, patients who are symptomatic will be posted for surgical exploration. Abdominal radiographs are usually normal or may show ileus, pneumoperitoneum or less commonly a gas filled diverticula being mistaken as gall bladder or intussusception segment of bowel. (12) Our case demonstrated a gas filled pouch over the right side of the abdomen on abdominal radiograph. Abdominal ultrasonography is useful in excluding intussusception but with limitations for other complications of MD. Computed tomographic (CT) scans can be misleading as well with reported cases of torsted MD reported as cystic mass in the abdomen and pelvis. (13)

Based on previous cases reported, intraoperative findings include torsion, ischemia, haemorrhagic or perforation with purulent peritonitis. (14) The greater degree of torsion signifies a worse vascular compromise to the MD and leading to infarction and ischemic perforation with high morbidity which happened in our case. (10)

The management for symptomatic MD has been surgical resection and wedge resection is the commonly performed or alternatively resection of the MD segment of small bowel with primary anastomosis. (15) For asymptomatic MD discovered during abdominal exploration, current recommendation suggest excision of MD for those patients who are less than 50 year old and has anatomic risk factors such as length of more than 2cm, palpable abnormality, presence of fibrous bands as these are associated with higher risk of complication. (16), (17) In this case, our patient was a young gentleman who presented with an acute abdomen that required surgical intervention and his MD was more than 2cm with a narrow base and with presence of mesodiverticular band. All these are high risk features for complications of MD. Hence, we would recommend excision of MD for all of those with length of more than 2cm with narrow base and presence of mesodiverticular band if found on an abdominal exploration to avoid complications arising in the future.

CONCLUSION

This case report demonstrates a patient with axial torsion of MD leading to ischemic perforation. The current imaging modalities are not reliable to detect this uncommon condition and most diagnoses were made intraoperatively. The major risk factors for such complication includes large size of MD, longer length with narrow base and presence of

mesodiverticular band. It is important for clinicians to be vigilant about MD and its complications to prevent mismanagement.

REFERENCES

1. Meckel JF. Über die Divertikel am Darmkanal. *Arch Physiol* 1809;9:421–53.
2. Stallion A, Shuck JM. Meckel's diverticulum. 2001; Available at: <https://www.ncbi.nlm.nih.gov/books/NBK6918/>.
3. Moore GP, Burkle FM Jr: Isolated axial volvulus of a Meckel's diverticulum. *Am J Emerg Med* 1988, 6:137-142.
4. Malhotra S, Roth DA, Gouge TH, Hofstetter SR, Sidhu G, Newman E: Gangrene of Meckel's diverticulum secondary to axial torsion: a rare complication. *Am J Gastroenterol* 1998, 93:1373-1375.
5. Yahchouchy EK, Marano AF, Etienne JC, Fingerhut AL. Meckel's diverticulum. *J Am Coll Surg*. 2001 May;192(5):658-62. doi: 10.1016/s1072-7515(01)00817-1. PMID: 11333103.
6. Ueberrueck T, Meyer L, Koch A, Hinkel M, Kube R, Gastinger I. The significance of Meckel's diverticulum in appendicitis--a retrospective analysis of 233 cases. *World J Surg*. 2005 Apr;29(4):455-8. doi: 10.1007/s00268-004-7615-x. PMID: 15776296.
7. Elsayes KM, Menias CO, Harvin HJ, Francis IR. Imaging manifestations of Meckel's diverticulum. *AJR Am J Roentgenol*. 2007 Jul;189(1):81-8. doi: 10.2214/AJR.06.1257. PMID: 17579156.
8. Yamaguchi M, Takeuchi S, Awazu S. Meckel's diverticulum. Investigation of 600 patients in Japanese literature. *Am J Surg*. (1978) 136:247–9. doi: 10.1016/0002-9610(78)90238-6
9. Almagro UA, Erickson L Jr: Fibroma in Meckel's diverticulum: a case associated with axial and ileal volvulus. *Am J Gastroenterol* 1982, 77:477-480
10. Limas C, Seretis K, Soultanidis C, Anagnostoulis S: Axial torsion and gangrene of a giant Meckel's diverticulum. *J Gastrointest Liver Dis* 2006,15:67-68.
11. Kiyak G, Ergul E, Sarikaya SM, Kusdemir A: Axial torsion and gangrene of a giant Meckel's diverticulum mimicking acute appendicitis. *J Pak Med Assoc* 2009, 59:408-409.
12. Gallego-Herrero C, del Pozo-Garcia G, Marín-Rodríguez C, Ibarrola de Andrés C: Torsion of a Meckel's diverticulum: sonographic findings. *Pediatr Radiol* 1998, 28:599-601.
13. Farris S, Fernbach S: Axial torsion of Meckel's diverticulum presenting as a pelvic mass. *Pediatr Radiol* 2001, 31:886-888.
14. Eser M, Oncel M, Kurt N: Gangrene secondary to axial torsion in a patient with Meckel's diverticulum. *Int Surg* 2002, 87:104-106.
15. Prasad TR, Chui CH, Jacobsen AS: Laparoscopic resection of an axially torsted Meckel's diverticulum in a 13-year-old. *J Laparoendosc Adv Surg Tech A* 2006, 16:425-427.
16. Park JJ, Wolff BG, Tollefson MK, Walsh EE, Larson DR. Meckel diverticulum: the Mayo Clinic experience with 1476 patients (1950-2002). *Ann Surg*. 2005 Mar;241(3):529-33. doi: 10.1097/01.sla.0000154270.14308.5f. PMID: 15729078; PMCID: PMC1356994.

17. Mackey WC, Dineen P. A fifty year experience with Meckel's diverticulum. Surg Gynecol Obstet. 1983 Jan;156(1):56-64. PMID: 6600203.

UNDER PEER REVIEW