

## Review Article

### EPIDEMIOLOGY AND PUBLIC HEALTH SIGNIFICANCE OF HYDATIDOSIS - A REVIEW

---

#### ABSTRACT

*Echinococcus granulosus* is an important dog tape worm whose larval stage causes hydatidosis in animals and man. Food animals such as sheep, goat, cattle acts as its intermediate host. It is a major parasitic zoonosis having high economic loss and public health significance and high worldwide prevalence rate. There are different strains of *E. granulosus* from G1 to G10 which is distributed worldwide infecting various animals and humans. The tapeworm in dogs causes fewer ill effects but in food animals it affects liver, lungs and spleen which leads to condemnation of meat thereby affecting economic value of meat. In humans it causes severe disease mainly cystic echinococcosis and alveolar echinococcosis in addition to two forms of neotropical echinococcosis namely polycystic echinococcosis and unicystic echinococcosis. Diagnosis and treatment of hydatidosis in animals is practically difficult and uneconomical but more promising in human medicine due to advanced techniques. The role of stray dogs in the maintenance of the life cycle of parasite is important hence health education and public awareness are very essential in the control of echinococcosis.

*Keywords: Echinococcus granulosus, hydatid cyst, dogs, humans, public health*

#### 1. INTRODUCTION

Hydatidosis is a parasitic disease caused by larval stage of helminthic flatworms called *Echinococcus* spp. It is a zoonotic cosmopolitan parasitic disease with a significant economic loss directly by causing organ or carcass condemnation and indirectly by affecting human and animal health which increase in the cost for diagnosis, treatment and control of the disease [1]. Annually there are estimated more than 18,000 new cases worldwide of echinococcosis with 91% of those occurring in China [2] and more than 1 million people are affected with echinococcosis at any given time [3]. In 1855, Rudolf Virchow, the German pathologist, [4] recognized that alveolar echinococcosis was at the time known as colloid carcinoma of the liver, which was known for its tumor-like lesions in the liver, were actually caused by an *Echinococcus* species.

**Comment [m1]:** Insert a statement showing that it is a review paper, methodology of data collection, journals &---years covered

**Comment [m2]:** Indicate the gap of knowledge and objectives of the review

#### 2. PARASITE AND THE DISEASE

The most important species of Echinococcus is *Echinococcus granulosus* which belongs to Phylum: Platyhelminthes, Class: Eucestoda, Order: Taeniidea, Family: Taeniidae, Genus: Echinococcus, Species: *E. granulosus* [5] and found in the intestines of dogs and other canids. The metacestode or the larval stage of the tape worm is called hydatid cyst and found in the intermediate host (ungulates) such as sheep, cattle, goat, buffaloes, moose, camels etc. The cyst may be fertile or sterile. Accidental ingestion of *E. granulosus* eggs by man results in hydatidosis. The mature adult tapeworm measures about 3-9 mm long and consists of only 3 proglottids, a scolex with four suckers and an armed rostellum with 28-50 number of hooks [6]. There are basically four forms of echinococcosis as given in the figure 1.

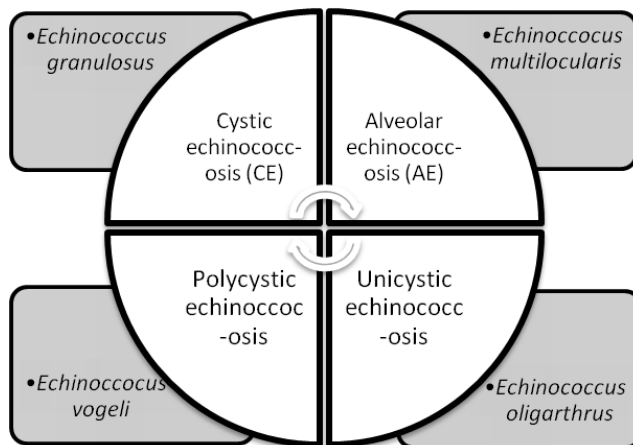


Figure 1 Forms of echinococcosis

CE and AE vary in their clinical manifestations, course of disease, and prognosis, to the extent that clinicians should look at these two parasitic infections as distinctly different entities. CE causes displacement and pressure atrophy, while AE expands by infiltrative growth [7].

### 2.1 *E. granulosus*- strains and distribution

There are various strains of *E. granulosus* found infecting humans and animals. The distinct genetic types (Table 1) of *E. granulosus* include two sheep strains (G1 and G2), two bovid strains (G3 and G5), a horse strain (G4), a camelid strain (G6), a pig strain (G7), and a cervid strain (G8). A ninth

genotype (G9) has been described in swine in Poland and a tenth strain (G10) in reindeer in Eurasia [8]. The most frequent strain associated with human CE appears to be the common sheep strain (G1).

UNDER PEER REVIEW

**Table 1: Worldwide occurrence of various strains of *E. granulosus* [9.10]**

Sl.No.	Continent/ Regions	Country/States	Strain of <i>E. granulosus</i>
1.	North America	-	G8, G1, G10
2.	South America	Peru, Chile, Argentina and Brazil	G1
3.	Australia	- Tasmania	G1 G2
4.	Western and Central Asia	Iran Turkey	G1 and G6 G1
5.	China	-	G1 and G6
6.	Africa	(Poorly researched)	G1 and G6
7.	Europe and the Mediterranean	Poland, Slovakia & Ukraine Spain	G6-G10 G1, G7 & G4

**Comment [m3]:** Reduce size of table & format as shown here

**Comment [m4]:** Better to insert references for each

### 3. PREVALENCE OF HYDATIDOSIS

There are various factors affecting prevalence/ incidence of hydatidosis which are responsible for occurrence as well as emergence of the disease. It includes the dogs harbouring, *E. granulosus* worms, access of dogs to infected offals, inadequate facilities for slaughter, improper disposal of infected viscera, practice of slaughtering livestock in households etc. These practices may result in feeding the dogs with slaughter wastes which are particularly important to maintain the parasite viability and so as results in emergence or reemergence.

#### 3.1. WORLDWIDE

WHO has designated AE as 1 of the 20 neglected tropical diseases and *E. multilocularis* as the food-borne parasite with the third largest global impact of 24 ranked parasites [11,12]. Echinococcosis is a cosmopolitan zoonosis. Both CE and AE are serious diseases, the latter especially so, with a high fatality rate and poor prognosis if managed inappropriately [13]. Many variables can affect hydatidosis such as regions, sex, age, and seasons. [14]. Temperate zones including several parts of the Mediterranean regions, central and Southern parts of Russia, some parts of America, Australia, North

and East Africa, China, and central Asia recorded the highest prevalence of hydatidosis in human and animal hosts [15].

Hydatidosis is currently considered an endemic zoonotic disease in the Mediterranean region [9]. Hydatidosis is endemic in all North African countries including Algeria Morocco, Tunisia, Libya, and Egypt [16] and also in sub-Saharan Africa including Mauritania, Tanzania, Sudan, Kenya, and Ethiopia [17]. The analysis of 134 isolates by Kamenetzky [18] from Argentina showed that hydatid cysts were produced by G1 (sheep strain) and G2 (Tasmanian sheep strain) genotypes in sheep; by G1, G2 and G5 (cattle strain) genotypes in cattle, only by G6 (camel strain) genotypes in goats and by G1 and G7 (pig strain) genotypes in pigs. Molecular analyses and sequencing revealed the prevalence of *Echinococcus* spp. as 14.13% (63/446) in faecal samples of stray dogs in Turkey and the common strains includes G1/G3, G4, G5, and G6/G7 [19].

### **3.2. INDIA**

Incidence of hydatidosis in buffaloes was found to be 30.61% in Andhra Pradesh [20] and 10% in animals slaughtered at Chennai, Tamil Nadu [21]. Naik [22] observed a higher infection rate in females than the male animals from necropsied sheep and goats during a period of one year. The prevalence rate of hydatidosis in Jammu was 19.8 % by Godara [23] where a total of 14.1 % goats had cysts in both the livers and lungs while 2.3 and 3.4 % goats had cysts in the livers or lungs, respectively. It was also found that 9.1 % goats had fertile cysts. The adult goats (>4 years) had a significantly higher prevalence rate as compared to the young goats (<2 years) and sex had no significant effect on the prevalence of hydatidosis in goats.

Hydatid cysts were found in 12.2% (n = 28) of sheep and 10.7% (n = 21) of goats in Kangra Valley of the north-western Himalayas. Pulmonary echinococcosis was more prevalent in slaughtered sheep and goats (sheep 56.36%; goats 62.90%) than hepatic echinococcosis (sheep 43.64%; goats 37.10%) [24]. A seven (2010-2017) year study by Vaidya [25] revealed that the prevalence of hydatidosis in cattle (3.00%) was highest followed by buffalo (2.05%), pig (1.28%), sheep (0.09%) and goat (0.01%), by PM examination.

### **4. VETERINARY PERSPECTIVES**

Abo-Aziza [14] studied, variable factors of hydatidosis infection in sheep, cattle, buffaloes, and camels slaughtered at Cairo and Giza abattoirs and found that prevalence of hydatidosis varies according to species, and it was significantly higher in camel (23.2%) followed by buffaloes (21.8%), then cattle (18.5%) and sheep (9.8%). The infection of hydatidosis in cattle was found to be 19.7% and 13.5% in sheep slaughtered at Addis Ababa abattoir in Ethiopia [26]. Concerning age variability, it was observed that the prevalence of hydatidosis was higher in adult sheep, cattle, and camel [1]. Hydatid cyst(s) was found in 1,290 (0.124 %) out of 1,037,872 slaughtered cattle, 320 (0.030 %) out of 1,051,648 slaughtered small ruminants, and 1610 (0.077 %) out of all the 2089520 slaughtered animals (cattle, shoats) in Turkey [27]. The overall prevalence of CE in all examined animals was 2.77% from 123 butcher's shops in Rawalpindi and Islamabad, Pakistan [28].

**Comment [m5]:** [26]

**Comment [m6]:** 2,089,520

## 5. HUMAN FRONTIERS

Human echinococcosis is a zoonotic disease (a disease that is transmitted to humans from animals). Humans are infected through ingestion of parasite eggs in contaminated food, water or soil, or after direct contact with animal hosts. The two most important forms, which are of medical and public health relevance in humans, are CE and AE. Among the major species, *Echinococcus multilocularis* is the most virulent species of the genus *Echinococcus*. It causes a highly lethal helminthic disease in humans. The disease may present as hepatic mass mimicking a malignant neoplasm [29]. A total of 155 patients with hydatid disease were identified by Mathur [30] in 6 years from 2010 to 2015 and found that there were 96 male (61.93%) and 59 female (38.06%) patients. Hydatid-specific IgG antibody was detected by enzyme-linked immunosorbent assay of 1,429 samples collected from different districts in the Kashmir region (North India) revealed 72 (5.03%) were seropositive to *E. granulosus* antigen [31].

**Comment [m7]:** Revise -----The enzyme-linked immunosorbent assay found that 72 (5.03%) of 1,429 samples from various districts of the Kashmir region (North India) tested positive for *E. granulosus*-specific IgG antibody [31].

## 6. PUBLIC HEALTH IMPORTANCE

Hydatidosis is a neglected public health problem in developing countries [32]. Animal handlers, veterinarians, dog owners are all at higher risk of infection since the eggs are shed with faeces in the environment and contamination of fruits [33], vegetables or water. Intake, also by direct contact with the fur of an animal containing eggs which will be transferred on hands to the mouth [32,34].

**Comment [m8]:** Animal handlers, veterinarians, and dog owners are all at a higher risk of infection since the eggs are shed in the environment and contaminate fruits [33].

**Comment [m9]:**

The analyzed dog faecal samples showed the prevalence of echinococcosis as 4.34% (19/438) by sedimentation method [25]. In a study by Rong [35], it was found that the dog was the most effective risk factor since 91% of the herdsman fed dogs, 65% of the sheep have close contact with domestic dogs and stray dogs, 47% of the domestic dogs may be in direct contact with stray dogs. Aziz and co workers, found that 97 (24.25%) out of 400 faecal samples of stray dogs examined, were positive for taeniid parasites in Iraq [1]. Hence, to estimate the occurrence of hydatidosis that infect various sheep, goat and other animals which are slaughtered in street (out of the proper place) becomes prime most important to curtail the transmission of the disease.

**Comment [m10]:** Revise

**Comment [m11]:** [36]

**Comment [m12]:** delete

**Comment [m13]:** revise

## 7. DIAGNOSIS

Echinococcosis in dogs can be diagnosed based on faecal examination. Detection of cysts in intermediate host is highly uneconomical and very often it is diagnosed during post mortem examination or meat inspection. Radiography is used for the detection of hydatid cysts in man. However, calcification is necessary for detecting cysts in other sites for deep-seated lesions in various organs. Radiographic visualization. Computed tomography, ultrasonography and magnetic resonance imaging are useful for diagnosis because of its widespread availability and usefulness for defining site, dimensions, number and vitality of cysts, the extent and condition of the avascular fluid-filled cysts [37].

**Comment [m14]:** .

**Comment [m15]:** R

**Comment [m16]:** revise

## 8. TREATMENT

Surgery was the only options for treatment of hydatid cysts in humans until 1980. However, after that chemotherapy with benzimidazole compounds was found to be effective for protoscolices [38]. More recently, treatment includes cyst puncture, injection of chemicals and re-aspiration, aspiration and percutaneous thermal ablation etc. have been introduced for management of CE. Though, it is more important form of treatment for lesions of liver, but for cysts in lungs, it is not recommended [39,40,41]. Albendazole therapy was found effective in 61.5% of inoperable lung hydatid patients and in surgically treated patients when given concomitantly pre- and post-operatively [42]. Treatment of animals is not economically feasible.

**Comment [m17]:** Until 1980, surgery was the only option for treating hydatid cysts in humans. However, treatment using benzimidazole compounds was later discovered to be efficacious for protoscolices.

**Comment [m18]:** Which treatment?

**Comment [m19]:** Reference

## 9. MANAGEMENT AND CONTROL

The epidemiology and control of hydatidosis is often considered to be a veterinary matter since the disease can be regulated by controlling parasites in animals [43]. However, collaboration between veterinarians and public health workers is essential for the successful control of hydatidosis.

Control of hydatidosis (Figure 2) can properly achieved by the support of dog-owners and this is possible through increasing health education, improving sanitation, and raising awareness of community regarding the disease [44]. Health education is a paramount controlling measure. A holistic control approach that targets humans, livestock, dogs and the environment (one health approach) will play a commendable role in disease epidemiology. This approach should also involve strategic use of anthelmintics in animals, standardized veterinary meat inspection in abattoirs, control of stray dogs to reduce environmental contamination and proper environmental sanitation.

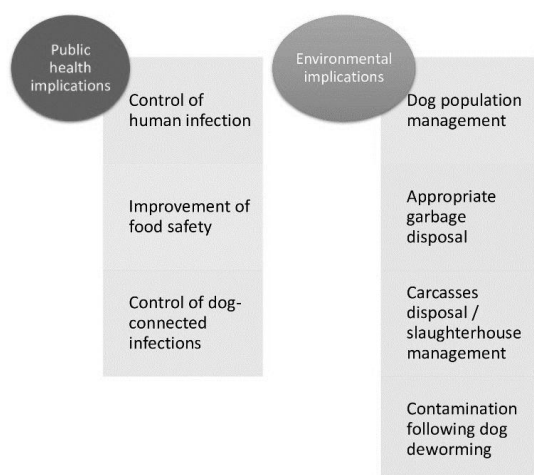


Figure 2: Preventive measures for control of hydatidosis

## 10. CONCLUSION

A rapid and sensitive method to diagnose parasitosis condition in dogs is crucial as the relationship between dogs, humans and sheep is very close. Mass screening of humans in highly endemic regions will also encourage early detection and treatment. Echinococcosis is often expensive and complicated to treat and may require extensive surgery and/or prolonged drug therapy. In the case of cystic echinococcosis preventive measures also include, deworming dogs which are the definitive hosts, slaughterhouse hygiene, and public education. Hence, public awareness about the

transmission and control of the disease and its public health significance needs to be disseminated in order to obtain better results. Collaboration between veterinarians and public health workers in the prevention and control of the disease is also mandatory.

## CONSENT

Not applicable

## ETHICAL APPROVAL

Not applicable

## REFERENCE

1. Budke CM, Deplazes P, Torgerson PR. Global socio-economic impact of CE. *Emerg Infect Dis.* 2006;12(2): 296- 303.
2. Torgerson PR, Keller K, Magnotta M, Ragland N. The global burden of alveolar echinococcosis. *Negl Trop Dis.* 2010 4:e 722.
3. Baumann S, Shi R, Liu W, Bao H, Schmidberger J, Kratzer W. et al. Worldwide literature on epidemiology of human alveolar echinococcosis: a systematic review of research published in the twenty-first century. *Infection*, 2019 47: 703-727.
4. Tappe D, Stich A, Frosch M. Emergence of Polycystic Neotropical Echinococcosis. *Emerg Infect Dis.* 2008; 14(2): 292-297.
5. Soulsby E.J.L. *Helminths, Arthropods and Protozoa of Domesticated Animals.* 7th Ed., East-West Press Private Limited, NewDelhi 1982
6. *Echinococcus granulosus.* University of Michigan. Accessed on 30.04.2023. Available: [https://animaldiversity.org/accounts/Echinococcus\\_granulosus](https://animaldiversity.org/accounts/Echinococcus_granulosus)
7. Stojakovic M, Junghass. Cystic and alveolar echinococcosis. *Handb. Clin. Neurol.* 2013; 114:327-334.
8. McManus DP, Thompson RC. Molecular epidemiology of cystic echinococcosis. *Parasitology*,2003; 127(S1), S37-S51

9. Grosso G, Gruttadauria S, Biondi A, Marventano S, Mistretta A. Worldwide epidemiology of liver hydatidosis including the Mediterranean area. *World J. Gastroenterol.* 2012; 18(13): 1425-1437
10. Romig T, Ebi D, Wassermann M. Taxonomy and molecular epidemiology of *Echinococcus granulosus sensulato*. *Vet. Parasitol.* 2015;213: 76–84.
11. World Health Organization (WHO). World health statistics: monitoring health for the SDGs, sustainable development goals. Geneva: WHO; 2018. Accessed on 04.05.2023 Available <https://www.who.int/publications/i/item/9789241565585>
12. Food and Agriculture Organization of the United Nations (FAO) Multicriteria-based ranking for risk management of food-borne parasites. Microbiological risk assessment series no 23. Rome: FAO/WHO; 2014 Accessed on 07.04.2023. Available <https://agris.fao.org/agris-search/search.do?recordID=AJ2018000220>
13. Zhang W, McManus DP. Recent advances in the immunology and diagnosis of echinococcosis. *FEMS Immunol. Med. Microbiol.* 2006; 47(1): 24-41.
14. Abo-Aziza FAM, Oda SS, Aboelsoued D, Farag TK, Almuzaini AM. Variabilities of hydatidosis in domestic animals slaughtered at Cairo and Giza abattoirs, Egypt. *Vet. World.* 2019; 12(7): 998-1007.
15. Sadjjadi SM. Present situation of echinococcosis in the Middle East and Arabic North Africa. *Parasitol. Int.* 2006; 55 (1): S197-S202.
16. Dakkak A. Echinococcosis/ hydatidosis: A severe threat in Mediterranean countries. *Vet. Parasitol.* 2010; 174(1-2): 2-11.
17. Romig T, Omer RA, Zeyhle E, Hüttner M, Dinkel A, Siefert L, et al. Echinococcosis in sub Saharan Africa: Emerging complexity. *Vet. Parasitol.* 2011; 181(1): 43-47.
18. Kamenetzky L, Gutierrez AM, Canova SG, Haag KL, Guarnera EA, Parra A, et al. Several strains of *Echinococcus granulosus* infect livestock and humans in Argentina. *Infection, Genetics and Evolution.* 2002; 2:129–136

19. Avcioglu H, Guven E, Balkaya I, Kirman R, Akyuz M, Bia MM, et al. The situation of echinococcosis in stray dogs in Turkey: the first finding of *Echinococcus multilocularis* and *Echinococcus ortleppi*. *Parasitology* 2021; 148(9):1092-1098.
20. Sreedevi C, Devi MA, Annapurna P, Devi VR. A rare case of splenic hydatidosis in a buffalo: patho-morphological study. *J. Parasit. Dis.* 2016; 40(1): 214-216.
21. Sangaran A, Lalitha J. Incidence of cystic echinococcosis in buffaloes slaughtered at Chennai. *J. Vet. Parasitol.* 2010; 24(1): 93–94.
22. Naik G, Bhandurje M, Sawale G, Kommu S, Ravikumar Y, Madhuri D, Chandravati T, Lakshman M. Occurrence of Hydatidosis in Small Ruminants. *Int. J. Livest. Res.* 2018; 8(3): 292-295.
23. Godara R, Katoch R, Yadav A. Hydatidosis in goats in Jammu, India. *J. Parasit. Dis.* 2014; 38(1): 73-76.
24. Moudgil AD, Moudgil P, Asrani RK, Agnihotri RK. Hydatidosis in slaughtered sheep and goats in India: prevalence, genotypic characterization and pathological studies. *J. Helminthol.* 2019; 94:1-5
25. Vaidya VM, Zende RJ, Paturkar AM, Gatne ML, Dighe DG, Waghmare RN, et al. Cystic echinococcosis in animals and humans of Maharashtra State, India. *Acta. Parasit.* 2018; 63, 232–243
26. Fikire Z, Tolosa T, Nigussie Z, Macias C, Kebede N. Prevalence and characterization of hydatidosis in animals slaughtered at Addis Ababa abattoir, Ethiopia. *Journal of Parasitology and Vector Biology* 2012; 4(1): 1-6.
27. Acioz M, Bozkaya F. The monetary losses associated with hydatidosis in slaughtered ruminants in Turkey. *Helminthologia.* 2012; 59(3): 246-252.
28. Khan A, Ahmed H, Simsek S, Afzal MS, Cao J. Spread of Cystic echinococcosis in Pakistan due to stray dogs and livestock slaughtering habits: Research priorities and Public Health Importance. *Front. Public Health.* 2020; 29 (7): 1-6.

29. Bansal N, Vij V, Rastogi M, Wadhawan M, Kumar A. A report on three patients with *Echinococcus multilocularis*: lessons learned. *Indian J. Gastroenterol.* 2018; 37: 353–358.
30. Mathur PN, Parihar S, Joshi, CP, Kumawat JL. Hydatid disease-still endemic in the southern region of state of Rajasthan: a clinical study carried out in tertiary care hospital. *Int. Surg. J.* 2016; 3:1802-1805.
31. Fomda BA, Khan A, Thokar MA, Malik AA, Fazili A, Dar RA, et al. Sero-Epidemiological Survey of Human Cystic Echinococcosis in Kashmir, North India. 2015 *PLoS ONE* 10(4): e0124813. <https://doi.org/10.1371/journal.pone.0124813>
32. Al-Khayat FAA. Prevalence and Public Health Importance of Hydatidosis in Sheep slaughtered by Unlicensed ways. *Biomed. Pharmacol J.* 2019 12(1): 399-402.
33. Hussein AH, Mohammed E. Evaluation of ultrasonography as a diagnostic tool for hepatic hydatid cysts in sheep. *Turk. J. Vet. Anim. Sci.* 2014; 38: 409-417
34. Moro P, Schantz PM. Echinococcosis: a review. *Int. J. Infect. Dis.* 2009; 13(2):125-133
35. Rong X, Fan M, Sun X, Wang Y, Zhu H. Impact of disposing stray dogs on risk assessment and control of Echinococcosis in Inner Mongolia. *Math. Biosci.* 2018; 299: 85-96.
36. Aziz HM, Hama AA, Salih MAH, Ditta A. Prevalence and molecular characterization of *Echinococcus granulosus sensulato* eggs among stray dogs in Sulaimani Province- Kurdistan, Iraq. *Vet. Sci.* 2022; 9(4): 151.
37. Bhatia JK, Ravikumar R, Naidu CS, Sethumadhavan T. Alveolar hydatid disease of the liver: a rare entity in India. *Med. J. Armed Forces India.* 2016; 72:S 126–129.
38. Khuroo MS, Wani NA, Javid G, Khan BA, Yattoo GN, Shah AH, et al. Percutaneous drainage compared with surgery for hepatic hydatid cysts. *N. Engl. J. Med.* 1997; 337: 881-887.
39. Moro P, Schantz PM. Echinococcosis: a review. *Int. J. Infect. Dis.* 2009; 13(2):125-133

40. Parikh F. Echinococcosis--cut to cure but what about control? J. Assoc. Physicians India. 2012; 60: 9-10.
41. Craig PS, McManus DP, Lightwolers MW, Chabalgoity JA, Garcia HH, Gavidia CM, et al. Prevention and control of cystic echinococcosis, Latent Infect. Dis. 2007; 7: 385- 394.
42. Ghoshal AG, Sarkar S, Saha K, Sarkar U, Kundu S, Chatterjee S, et al. Hydatid lung disease: an analysis of five years cumulative data from Kolkata. J. Assoc. Physicians India 2012; 60: 12-16.
43. Gessese AT. Review on Epidemiology and Public Health Significance of Hydatidosis. Vet. Med. Int. eCollection 2020
44. Andrabi A, Tak H, Rasool A. Hydatidosis: A Review. International Journal Of Scientific & Technology Research 2020; 9(03): 4664-4671.

UNDER PEER REVIEW