

# **Intestinal cystic pneumatosis secondary to antro-pyloric stenosis discovered during a suspicion of peritonitis by ulcerative perforation: a case report**

### **Abstract :**

Cystic intestinal pneumatosis is the presence of gas bubbles in the wall and the serosa of the digestive tract. It is a benign and rare pathology, of radiological diagnosis by abdominal CT given its great sensitivity and of favorable evolution by the spontaneous disappearance of the cysts and whose treatment would rather be abstention. We report the case of a 54-year-old man, chronic smoker and treated in 2019 for helicobacter pylori gastritis. He was hospitalized for vomiting associated with generalized abdominal pain with epigastric origin. The patient underwent an abdominal CT scan which found pneumo peritoneum, fairly abundant fluid intraperitoneal effusion and a stasis stomach. The patient was operated on and exploration revealed moderately abundant ascites, stasis of the stomach upstream of an antro-pyloric substenosing stricture and intestinal cystic pneumatosis at the level of the last ileal loops. A gastro-jejunal diversion on a loop mounted in omega trans and under mesocolic with hail and hail anastomosis at the foot of the year was performed. The postoperative follow-up was simple.

**Keys words:** cystic pneumatosis, antro-pyloric stenosis, diagnosis, treatment.

### **INTRODUCTION :**

Intestinal cystic pneumatosis is characterized by the presence of gaseous cysts or pneumocysts in the wall and the serosa of the digestive tract with a predilection for the hail and the colon.

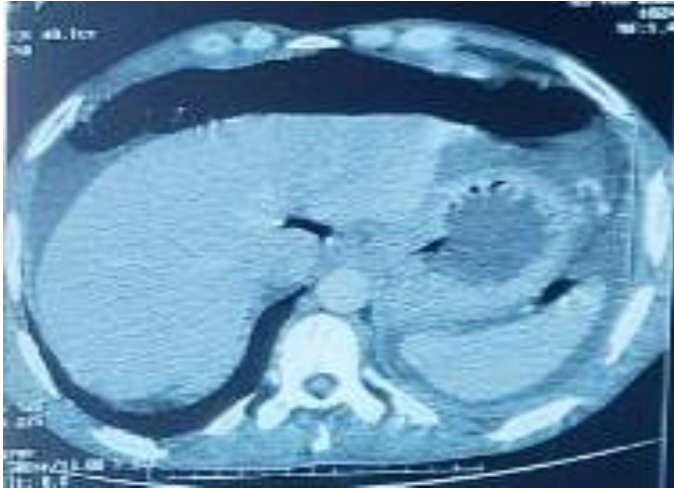
Primary pneumatosis preferentially affects the left colon in the form of cysts, while secondary pneumatosis can affect the entire digestive tract resulting in linear gas infiltration.

We report the case of an intestinal pneumatosis cystic associated with an antro-pyloric stenosis discovered fortuitously during an emergency pathology in order to evoke the diagnostic and therapeutic aspects of the disease.

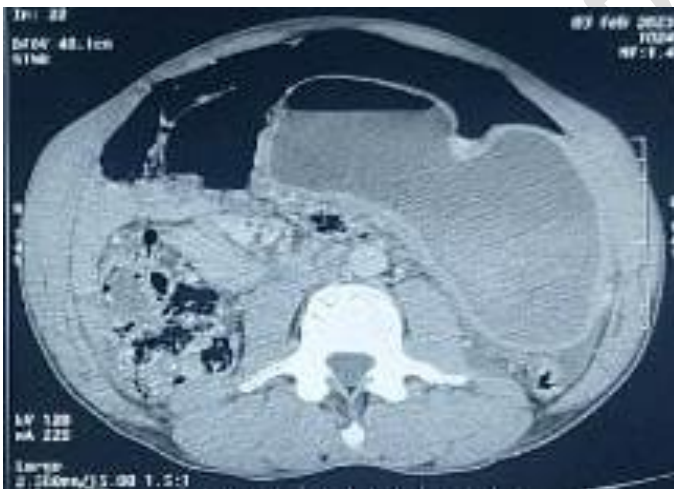
### **CASE PRESENTATION:**

54-year-old patient, chronic smoker at 20AP, treated in 2019 for Helicobacter pylori gastritis and who had presented four days before his admission with generalized abdominal pain from the epigastric point of departure, associated with food vomiting, without transit disorder or haemorrhage exteriorized digestive system, all evolving in a context of apyrexia and deterioration of his general condition. The clinical examination on admission found a

conscious patient, hemodynamically and respiratory stable, blood pressure: 12/06 mmhg, heart rate: 87 beats / min, respiratory rate: 18 C / min, with a distended tympanic and sensitive abdomen. , digital rectal examination was normal. The rest of the somatic examination was unremarkable. Abdominal CT had shown a moderate abundance of pneumoperitoneum located in the peri-hepatic and peri-splenic areas (figure 1) as well as a large amount of liquid peritoneal effusion with a stasis stomach (figure 2), all evoking peritonitis by perforation of a gastric ulcer.

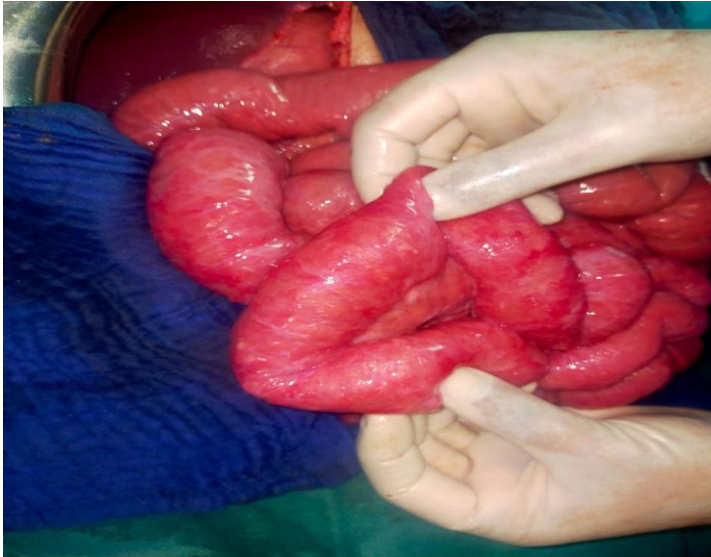


**Figure 1 :** Abdominal CT scan, axial section showing pneumoperitoneum

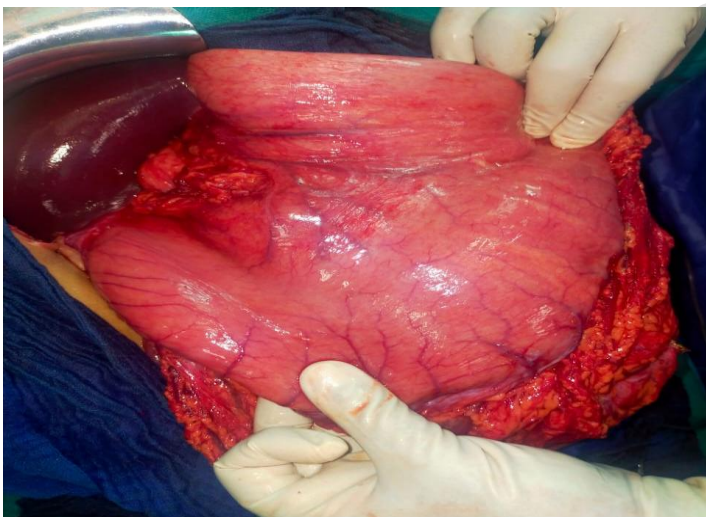


**Figure 2 :** Abdominal CT scan, axial section showing stasis stomach

The intervention was a gastro-jejunal diversion on a loop mounted in omega trans and under mesocolic, hail and bowel anastomosis at the foot of the loop and drainage under the left phrenic by Salem catheter. Surgical exploration revealed the presence of a medium-abundance effusion made of ascitic fluid: removed and evacuated, absence of false membranes and absence of collection, stasis stomach upstream of an antro-pyloric stenosing stricture (figure 4), aspect of intestinal cystic pneumatosis (figure 3) at the level of the last ileal loops. Immediate or late sequels were good. The patient is currently doing well.



**Figure 3 :** Intraoperative image showing intestinal pneumatosis cystica



**Figure 4 :** Intraoperative image showing stasis stomach

## DISCUSSION

Digestive pneumatosis remains a benign and rare pathology, discovered in 1754 by DUVERNOY during an autopsy (1). The age of onset of intestinal cystic pneumatosis is between 40 and 50 years (2) with a sex ratio of 1. The clinical picture of pneumatosis intestinalis remains rather asymptomatic or even paucisymptomatic and nonspecific (diarrhea, vomiting, localized or generalized abdominal pain as well as weight loss), the etiologies are diverse, the complications remain rare and depend on the size of the cysts such as volvulus, mechanical obstruction, acute intussusception or pneumoperitoneum (3) as in our case.

In 85% of cases, intestinal cystic pneumatosis is secondary to or associated with other gastrointestinal pathologies (inflammatory bowel disease, peptic ulcer (4), pyloric stenosis, abdominal trauma) or extra digestive (chronic obstructive pulmonary disease, heart disease , cystic fibrosis, lupus, polyarteritis nodosa); the primitive forms represent only 15% of the

reported cases. In our patient, pneumatosis cystica was related to pyloric stenosis (5). The mechanism of cystic pneumatosis is still currently unknown but there are several hypotheses proposed by Nelson in 1972: obstacle on the intestinal lumen, mucosal ulcerations and / or intrathoracic hyperpressure.

The abdomen without preparation can alone establish the diagnosis by looking for the Moreau-chilaiditi sign. It consists of the interposition of gaseous clearness between the right diaphragmatic dome and the liver without clinical syndrome of digestive perforation (6), but abdominal CT remains the examination of choice because of its great sensitivity (7), in our case the surgical indication was taken on the elements of the scanner. The evolution of pneumatosis cystica is often marked by the spontaneous disappearance of the cysts, which is why treatment should be abstention as long as it is asymptomatic (8), surgical treatment should be reserved for symptomatic forms responsible for severe malnutrition, occlusion or rectal bleeding. Medical treatment can be proposed based on antibiotics, hyperbaric oxygen therapy or diet, but the effects remain inconclusive.

## CONCLUSION

Pneumatosis intestinalis is a rare and mysterious condition that still remains an incidental diagnosis. It is the main cause of medical pneumoperitoneum. Within the framework of pathological associations, the most common digestive disorder is pyloric stenosis, which responds to the mechanical theory. surgical treatment is considered during complications but therapeutic abstention remains the best choice, given the spontaneously favorable evolution of this pathology.

## Références

- (1) DUVERNOY J.G. Anatomical observation of air trapped under the outer and inner skin of the intestines *Phys Med Abhandl Acad Wisseusch Petersb*, 1783 ; 2:182.
- (2) Pavic M, Debourdeau P, Ehre P, Billaud Y. Intestinal pneumatosis: right colonic cystic form with a linear appearance on CT scan. *Med Press*. 2002; 31(21): 973-5.
- (3) Chan Sui Ko, A., C. Brault, L. Medioni, S. Hakim, P. Duhaut, and J. Schmidt, 'A chance discovery of pneumoperitoneum: intestinal cystic pneumatosis', *La Revue de Médecine Interne*, 78th French Congress of Internal Medicine, Grenoble, December 12-14, 2018, 39 (2018).
- Miguil M.S, Iben Loualid Y., Yila A., Lammat H., Rabbani K., and Louzi A. ,CADI AYYAD UNIVERSITY VISCERAL SURGERY SERVICE', *International Journal of Advanced Research*, 10.11 (2022), 874–78.
- (5) El Matiallah, Mohammed Amine, Hicham El Bouhaddouti, Ouadii Mouaquit, El Bachir Benjelloun, Abdelmalek Ousadden, and Khalid Ait Taleb, 'Intestinal Cystic Pneumatosis Revealed by Gastro-Jejunal Anastomosis Stenosis: About a Case ', *The Pan African Medical Journal*, 15 (2013), 125.
- (6) Intestinal Cystic Pneumatosis Secondary to Peptic Ulcer: About Three Cases' <<https://www.panafrican-med-journal.com/content/article/20/150/full/>> [accessed 30 May 2023 ]

(7) Soyer, P., S. Martin-Grivaud, M. Boudiaf, P. Malzy, F. Duchat, L. Hamzi, and others, 'Linear or cystic: an iconographic review of CT aspects of pneumatosis intestinalis of the 'adult', *Journal of Radiology*, 89.12 (2008), 1907–20

(8) Foessel, L., V. Faucher, M. Lujic, J. Charton, M.-Y. Jeung, and C. Roy, 'Overview of pneumatosis intestinalis', *Feuillets de Radiologie*, 55.2 (2015).

UNDER PEER REVIEW