

Original Research Article

Does tight mitral stenosis protect the left ventricle? : Strain Vs Simpson Biplan : an echographic study of 50 cases

Abstract

Introduction : mitral stenosis is one of the most frequent valve diseases in Morocco. mitral stenosis had been considered for several years as a protective left ventricular valve disease. however, many studies have disapproved of this theory. the advent of different imaging techniques has made it possible to make a drastic contribution to these different studies. through our work we have tried to confirm this theory while reviewing the literature on this subject.

Materials and Methods : This retrospective study included 50 patients who had been admitted for symptomatic mitral stenosis in Mohamed V Military Teaching Hospital in Rabat, Morocco, from January 2015 to June 2021. MORE than 100 patients have been reviewed but only 50 cases were exploitable concerning the longitudinal strain. patients with ischemic heart disease or associated hypertensive heart disease or other valvular disease were excluded. All of the patients had a clinical examination, EKG, transthoracic echocardiography. Only the Patients who had a severe and symptomatic mitral stenosis with no other significant valve disease were include in this study.

Results: during our study, we analyzed 50 echocardiograms of patients with severe mitral stenosis, 15 men (30%) and 35 women (70%). we had an average 2D global Strain of $-15\% \pm 4$ in women and $-15\% \pm 3$ in men. An average LVEF value of $55\% \pm 7$ in women and $54\% \pm 8$ in men, in our study we found that 28 patients had concordant results between the Strain2D and the LVEF retained by Simpson biplane. on the other hand, out of the 50 patients included in the study, 22 patients or 44% had an altered Strain while they presented a normal LVEF ($> 50\%$)

Conclusion : mitral stenosis has been considered for years as LV protective valvular disease. but the advent of new imaging techniques has proven otherwise. several etiologies of this LV dysfunction have been studied but the conclusion is the same: it is necessary to multiply the imaging modalities, in particular the 2D STRAIN, to have a better study of the LV function and the achievement of the different walls during a tight mitral stenosis.

Keywords : Mitral stenosis, STRAIN

Introduction : mitral stenosis is one of the most frequent valve diseases in Morocco. although it has become a rare entity in developed countries, mitral stenosis remains a problem frequently encountered in developing countries given the persistence of streptococcal infections and the lack of access to health care.

mitral stenosis had been considered for several years as a protective left ventricular valve disease. however, many studies have disapproved of this theory. the advent of different imaging techniques has made it possible to make a drastic contribution to these different studies.

through this work we tried to verify the degree of protection of the left ventricle by mitral stenosis using longitudinal strain as a study method while comparing the results obtained with the results of ejection fractions with a systemic review of the literature on this subject

Material and methods

This retrospective study included 50 patients who had been admitted for symptomatic mitral stenosis in Mohamed V Military Teaching Hospital in Rabat, Morocco, from January 2015 to June 2021. All of the patients had a clinical examination, EKG, transthoracic echocardiography. Only the Patients who had a severe and symptomatic mitral stenosis with no other significant valve disease were include in this study. patients with weak to mild mitral stenosis or other valve disease and atrial fibrillation were excluded from the study

The study of the function of the left ventricle was carried out through the study of the strain following the acquisition of 3 loops in apical view, 4 chambers, 3 chambers and 2 chambers. After having selected these 3 loops, we defined the base and the tip for each between them. The software offers automatic recognition of the endocardium, that we approve or that we can modify which allowed us to have a Representation in bull's eyes which is the overlay of each of the walls, analyzed from the base to the point, with any anomalies of shortening of the longitudinal fibers.

In addition to the strain, the study of the ejection fraction by simpson bi-plane method was used on a 4-chambers apical view which allowed us to obtain a comparative value of reference with the data obtained by the strain.

Statistical study

For the analytical study, the software Jamovi version 1.6.8 was used. Quantitative variables were expressed as mean plus or minus standard deviation. The qualitative variables were expressed in number and percentage.

Results

During our study, we analyzed 50 echocardiograms of patients with severe mitral stenosis. we had 13 male and 37 female patients. an average age of 53 +/- 3.32% of the patients had diabetes, 18% dyslipidemia, 100% of the patients presented with dyspnea and 38% presented with palpitations. we had an average surface area of 1.1cm². an average of longitudinal strain of - 14.91% with a maximum value of strain of - 23% and a minimum value of -5% with a standard deviation of 5.51%.

With regard to the left ventricular function, we had an average of 54% with a maximum value of 63% and a minimum value of 34% with a standard deviation of 8%

In our study we found that 28 patients had concordant results between the Strain2D and the LVEF retained by simpson biplane. on the other hand, out of the 50 patients included in the study, 22 patients or 44% had an altered Strain while they presented a normal LVEF (> 50%).

AGE	53 ± 3
GENDER	37F/13M
DM(%)	32%
Dyslipidemia	18%
Dyspnea	100%
Palpitations	38%

Table 1: Epidemiological and clinical characteristics of the population

	Mean
SGL	-14.91%± 5%
LVEF	54% ± 8%

Table 2: Average longitudinal global strain and ejection fraction of the population

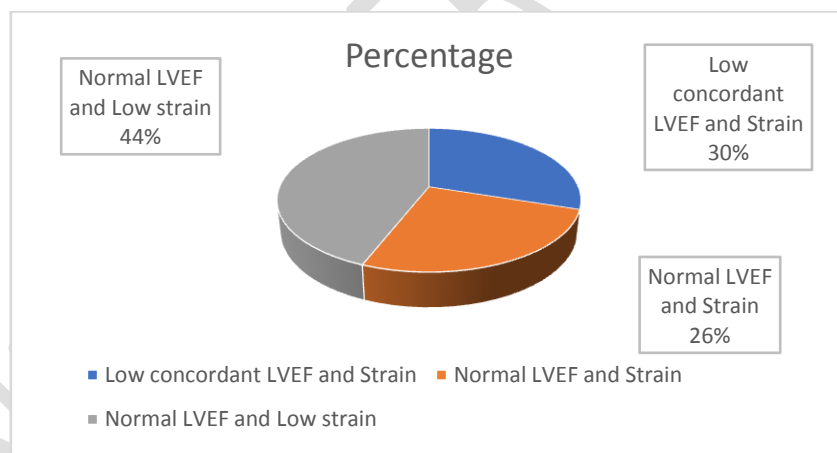


Figure 1: Percentage of concordance of the results between the ejection fraction and the value of the global longitudinal strain

Discussion

The mitral annulus separates the left atrium from the left ventricle (LV). It has a complex saddle shape that is divided into anterior and posterior portions. The anterior annulus spans the left and right fibrous trigones and is anatomically coupled to the aortic annulus. (1)

Two-thirds of the world's population live in developing countries with a high prevalence of rheumatic fever or rheumatic heart disease (eg, 6 per 1000 schoolchildren in India vs 0.5 per 1000 in developed countries), resulting in a large population with mitral stenosis. In a survey of rheumatic fever in India, the mean age of presentation was 15.1 years (SD 4.4), and two-thirds of the participants had signs of mitral stenosis, of whom half had limiting symptoms.(2)

Aetiology of mitral stenosis is mostly rheumatic or degenerative. Rheumatic fever is the most common cause of mitral stenosis worldwide. Its prevalence has greatly decreased in industrialized countries, but it remains a significant healthcare problem in developing countries and affects young patients(3).

The main features are leaflet thickening, nodularity, and commissural fusion, all of which result in narrowing of the valve to the shape of a fish mouth. The leaflets might be calcified. Chordal fusion and shortening adds a further resistance to blood flow. Continued inflammation, injury, and repair affect the effectiveness of treatment, and treatments are tailored to target these features of disease.(4)

Mitral stenosis creates a diastolic dam which is responsible for the formation of a diastolic gradient between the left ventricle and the left atrium (for a mitral stenosis of 1 cm², the corresponding average gradient is approximately 10 mmHg for cardiac output normal). The pressure will therefore rise in the left atrium while the end-diastolic pressure of the left ventricle remains unchanged: which explains the protection of the LV by the MS(5)

Strain and strain rate is a tool for precise quantification of myocardial function and contractility. STRAIN is a measure of myocardial fiber shortening. STRAIN rate measures the strain velocity. These two methods are complementary for evaluating LV function. Strain and SR measurements can be obtained from tissue Doppler acquisitions. Like all Doppler-based techniques, the main limitation of strain and SR derived from TDI is the angle dependence of the ultrasound beam hence the arrival of 2D strain (or 2D speckle tracking).

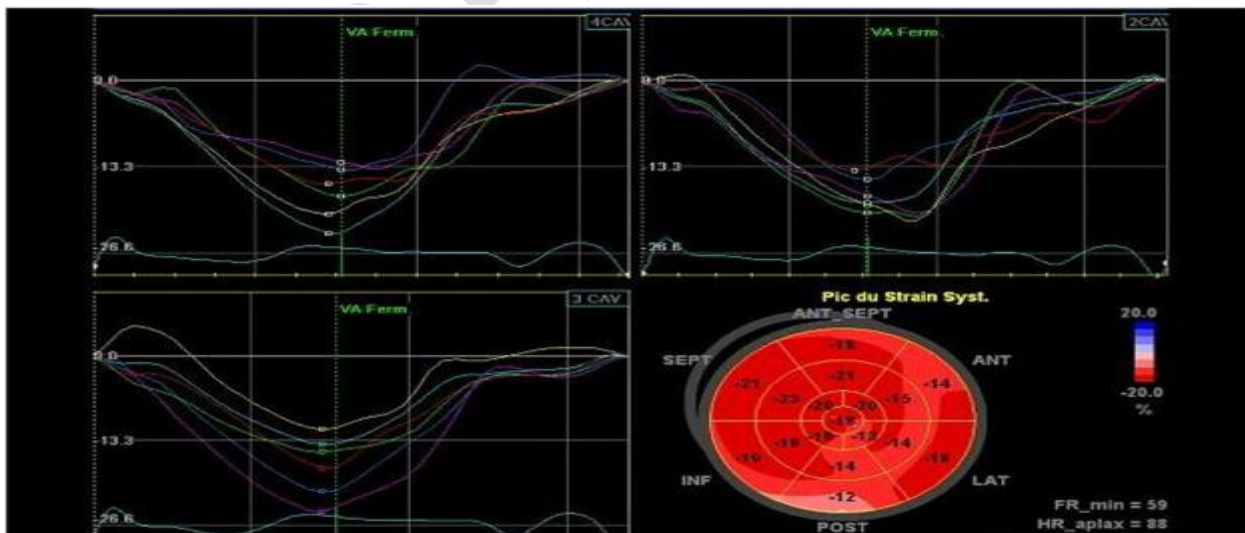


Figure2: example of a strain study of the left ventricle(6)

Several mechanisms have been discussed to explain the alteration of the functioning of the LV during mitral stenosis such as Integration of the valve and the apparatus under the mitral valve with the structures of the LV, Valvular thickening and fibrosis of the chordae which is responsible for tethering of the adjacent myocardium and immobilizing the inferolateral wall(7).

The second hypothesis is rheumatic carditis which was studied by dr lee et al by an old anatomopathological study carried out in 15 patients by myocardial biopsy. All patients—regardless of LV contractile function and degree of mitral stenosis—had varying degrees of ultrastructural alterations(8) . another hypothesis is that the fibrosis and shortening of the subvalvular apparatus in rheumatic MR, on the one hand, and the parietal stress linked to the myocardial factor, on the other hand, will lead to spherical remodeling of the LV, would prevent the formation of an optimal vortex, which could contribute to the development of LV dysfunction. other hypotheses such as paradoxical septal movement associated with right overload and rhythmic cardiomyopathy secondary to AF have been implicated in the pathophysiology of LV dysfunction in MS.(7)

The evaluation of LV function has long been neglected. In the late 1970s Several studies have shown left ventricle damage and dysfunction during tight MR.

An American study was carried out on Twenty consecutive patients with symptomatic, pure, rheumatic MS were studied and compared with an equal number of age- and sex-matched normal control subjects. Preload (LV end-diastolic volume index) was increased in patients with MS. End-systolic stress was significantly elevated in the patient population compared with the control subjects. Fractional fiber shortening and LV ejection fraction were significantly lower in patients with MS. The end-systolic stress to volume index ratio and systolic pressure to end-systolic volume ratio were significantly lower in patients with MS. which confirms reduced LV ejection performance has been documented in patients with isolated rheumatic MS(9)

An indian study concluded that MS patients as a group have reduced ejection performance and reduced preload. There reduction in ejection performance is due to increased after load without adequate Frank-Starling compensation. LV muscle function, however, is normal in most MS patients .(10)

A Turkish study made by Ziya Simşek and al consisted of 32 patients with isolated mitral stenosis and mitral valve area = 2.0 cm² (Group 1) and 25 healthy control subjects (Group 2). In addition to standard echocardiographic methods, TDI and SE/SRE were performed to assess LV functions in all participants. Systolic myocardial velocity (Sm) were significantly lower in Group 1 than in Group 2. also, early diastolic myocardial velocity (Em) were significantly lower in Group 1 than in Group 2 as no significant difference in late diastolic myocardial velocity (Am) between two groups. Peak systolic strain and strain rate of septal wall in Group 1 were significantly lower than Group 2. Besides, peak systolic strain and strain rate of lateral wall in Group 1 were significantly lower than in Group 2, suggesting underlying myocardial involvement (11)

Another turkish study done by emin bilen and al done on Seventy-two patients with isolated MS (mild, moderate and severe) and 31 healthy control subjects showed that Patients with MS had significantly lower LV longitudinal strain and Sr measurements than the control group. In addition, there were no significant differences in MS subgroups with respect to LV strain and Strain rate measurements.(12)

An Egyptian study carried out in 2019 made on a population of 40 patients with established diagnosis of MS subdivided in to 31 patients with moderate MS and 9 patients with mild MS and 20 healthy individuals as a control for cases. Patients with MS had significantly decreased longitudinal LV systolic Strain and Strain rate in comparison with control group despite no significant differences in LV EF%, LVESD and LVEDD were determined between the 3 groups.(13)

Our results are consistent with the various studies carried out over the years, showing that despite MS is considered a protective pathology of the LV, nevertheless, the study with the strain and the

strain rate shows an alteration in the function of the LV while maintaining a preserved ejection fraction. some studies have objectified that this damage is more concentrated on the lateral wall (11), others have speculated that even the circumferential strain of the LV remains altered in the case of tight MS, but the common point between these different studies is that the strain is a very interesting parameter for the diagnosis of early LV function impairment in MS.

Authors	Patients	Age	severity of MS	percutaneous mitral dilation	TEE	Comparison of LV MR/control function Correlation of LV function and indices hemodynamic
Özdemir et al. 2002 [7]	46	41+/-11	light to severe	NO	2D,TDI	S' at the lateral mitral annulus [cm/s]: 8.1 ± 1.7 vs. 10.2 ± 1.6; p < 0.001 Correlation of S' with SM
Doğan et al. 2006 [8]	30	45+/-9	light to moderate	NO	TDI	Systolic peak at the lateral ring: 10 ± 5 vs 25 ± 6% strain p < 0.001
Özdemir et al. 2010 [10]	60	41+/-5	light to moderate	NO	2D,2Dstrain	Reduced Regional SGL Strain: -17 ± 3.3 ± 2.5%; p = 0.001
Bilen et al. 2011	72	40.9+/-8	light to severe	NO	2D,2Dstrain	SGL: -16.8 ± 1.54 vs -19.6 ± 2%; p < 0.001 No correlation of LGS with SM
Sengupta et al. 2014	57	28+/-6.4	severe	YES	TSI,2D strain	Before PMD: SGL: -14.6 ± 3.3 vs -20.1 ± 2.3; p < 0.001 SGL correlated with mitral gradient After PMD: SGL: -17.8 ± 3.5 vs -20.1 ± 2.3; p<0.01

Table3: Main ultrasound studies of LV function in MS (7)

The emergence of strain and strain rate prompted several teams to propose this technique as a predictive marker of the severity and evolution of this pathology such as the team of Demet Menekşe and al who proposed to use 2D - speckle tracking for RM monitoring: a threshold in absolute value of SGL < 16.8% (sensitivity: 81%; specificity: 96%; p < 0.001) would predict faster progression of mitral stenosis. The authors suggest that LV dysfunction could be related to the relatively advanced age of patients with more significant myocardial alterations.(14)

Conclusion : mitral stenosis has been considered for years as LV protective valvular disease. but the advent of new imaging techniques has proven otherwise. several etiologies of this LV dysfunction have been studied but the conclusion is the same: it is necessary to multiply the imaging modalities,

in particular the 2D STRAIN, to have a better study of the LV function and the achievement of the different walls during a tight mitral stenosis.

References

1. Abramowitz Y, Jilaihawi H, Chakravarty T, Mack MJ, Makkar RR. Mitral Annulus Calcification. *J Am Coll Cardiol.* 2015;66(17):1934-41.
2. Chandrashekhar Y, Westaby S, Narula J. Mitral stenosis. *Lancet.* 2009;374(9697):1271-83.
3. Vahanian A, Beyersdorf F, Praz F, Milojevic M, Baldus S, Bauersachs J, et al. 2021 ESC/EACTS Guidelines for the management of valvular heart disease: Developed by the Task Force for the management of valvular heart disease of the European Society of Cardiology (ESC) and the European Association for Cardio-Thoracic Surgery (EACTS). *European Heart Journal.* 2021.
4. Krasuski RA, Bush A, Kay JE, Mayes CE, Jr., Wang A, Fleming J, et al. C-reactive protein elevation independently influences the procedural success of percutaneous balloon mitral valve commissurotomy. *Am Heart J.* 2003;146(6):1099-104.
5. Moore RA, Flores S, Cooper DS. Critical care of patients with paediatric valvar cardiac disease. *Cardiol Young.* 2014 Dec;24(6):1071-6. doi: 10.1017/S1047951114002169. PMID: 25647381.
6. Luconi N, Risse J, Busato T, Galland J, Mandry D, Voilliot D, Mohamed S, Zuily S, Wahl D. Myocarditis in a young man with adult onset Still's disease successfully treated with IL-1 blocker. *Int J Cardiol.* 2015;189:220-2. doi: 10.1016/j.ijcard.2015.04.071. Epub 2015 Apr 11. PMID: 25897909.
7. Soufiani, Aida. (2017). Fonction systolique dans le rétrécissement valvulaire mitral.
8. Lee YS, Lee CP. Ultrastructural pathological study of left ventricular myocardium in patients with isolated rheumatic mitral stenosis with normal or abnormal left ventricular function. *Jpn Heart J.* 1990 Jul;31(4):435-48. doi: 10.1536/ihj.31.435. PMID: 2232163.
9. Mohan JC, Khalilullah M, Arora R. Left ventricular intrinsic contractility in pure rheumatic mitral stenosis. *Am J Cardiol.* 1989 Jul 15;64(3):240-2. doi: 10.1016/0002-9149(89)90469-4. PMID: 2741834.
10. Gash AK, Carabello BA, Cepin D, Spann JF. Left ventricular ejection performance and systolic muscle function in patients with mitral stenosis. *Circulation.* 1983 Jan;67(1):148-54. doi: 10.1161/01.cir.67.1.148. PMID: 6847794.
11. Simşek Z, Karakelleoğlu S, Gündoğdu F, Aksakal E, Sevimli S, Arslan S, Gürlertop Y, Senocak H. Evaluation of left ventricular function with strain/strain rate imaging in patients with rheumatic mitral stenosis. *Anadolu Kardiyol Derg.* 2010 Aug;10(4):328-33. doi: 10.5152/akd.2010.091. PMID: 20693128.
12. Bilen E, Kurt M, Tanboga IH, Kaya A, Isik T, Ekinci M, Can MM, Karakas MF, Oduncu V, Bayram E, Aksakal E, Sevimli S. Severity of mitral stenosis and left ventricular mechanics: a speckle tracking study. *Cardiology.* 2011;119(2):108-15. doi: 10.1159/000330404. Epub 2011 Sep 9. PMID: 21912124.
13. ElShafey, W. , Farid, W. and El Maksoud, S. (2019) Role of Two Dimension Strain and Strain Rate Echocardiography in Assessment of Rheumatic Mitral Valve Stenosis. *World Journal of Cardiovascular Diseases*, 9, 759-771.
14. Gerede DM, Ongun A, Tulunay Kaya C, Acibuca A, Özyüncü N, Erol Ç. Use of strain and strain rate echocardiographic imaging to predict the progression of mitral stenosis: a 5-year follow-up study

the progression of mitral stenosis: a 5-year follow-up study. *Anatol J Cardiol.* 2016 Oct;16(10):772-777. doi: 10.14744/AnatolJCardiol.2015.6590. Epub 2016 Feb 4. PMID: 27182618; PMCID: PMC5324938.

UNDER PEER REVIEW