

Minireview Article

Comparative evaluation of Buccal fat pad and Nasolabial flap for the surgical management of Oral Submucous Fibrosis

Abstract

Oral submucous fibrosis is a crippling fibrotic disorder prevalent in South East Asia, mostly in India. Nasolabial flap proved itself to be extremely vascular and thus a safe flap to use. This can be attributed to extensive vascular anastomosis involving the facial, transverse facial and infraorbital arteries. Buccal fat pad functions well as a pedicled graft in the surgical management of oral submucous fibrosis. The bulk of the Buccal fat pad occupies the buccal space and rests on the periosteum that covers the posterior buccal aspect of the maxilla. Hence, we are doing a systemic review to compare the two most widely used flaps, Nasolabial flap and Buccal fat pad for the coverage of intraoral defects after release of fibrous bands in oral submucous fibrosis.

INTRODUCTION

Oral submucous fibrosis is a crippling fibrotic disorder prevalent in South East Asia, mostly in India. Incidence of oral submucous fibrosis in India is 0.2-0.5% of population. Commonly seen in age group between 20 and 40 years. The condition of oro-pharyngeal oral submucous fibrosis of oral cavity was prevalent even in the days of Shushruta (600 B.C) who stated in his book "Shushruta Samhita" a condition called 'Vidari' in his classification of diseases of mouth and throat. The features of which suit the symptomatology of oral submucous fibrosis. First described among five East African women of Indian origin under the term 'Atrophic idiopathic' (tropical) Mucosa Oris by Schwartz in 1952¹. Joshi in 1953 is credited to be the first person who described it and gave the present term "Oral submucous fibrosis". In the year 1954 Su.P from Taiwan described similar conditions which he called "Idiopathic scleroderma of mouth". The most important risk factor for Oral submucous fibrosis is the chewing of betel quid or areca nut. Other factors such as genetic and immunologic have been observed. Clinical features include burning sensation, blanching of oral mucosa, fibrotic bands restricting mouth opening, dry mouth, inability to whistle, blow and difficulty in swallowing². The common sites involved are the Buccal mucosa, faucial pillars, soft palate, lips and hard palate.²

Comment [H1]: Author is advised to go through the manuscript guidelines and format it accordingly.

Comment [H2]: NEED TO MODIFY BY EMPHASING IN THE CONVENTIONAL AND ADVANCED SURGICAL GRAFT PLACEMENT WITH ITS ADVANTAGES OVER EACH OTHER.

According to Khanna and Andrade classification system of oral submucous fibrosis which is based on mean interincisal opening:³

STAGE 1 : early oral submucous fibrosis without trismus (MIO >35 mm) STAGE 2 : mild to moderate disease (MIO 26-35 mm)

STAGE 3 : Moderate to severe disease (MIO 15 – 25 mm) STAGE 4 a : severe disease (MIO 15-25 mm)

STAGE 4 b : extremely severe malignant/ premalignant lesions noted intraorally

Biopsy report characteristically shows atrophic oral epithelium, loss of rete pegs, epithelial atypia. Hyalinization of collagen membranes are also noticed. Fibroblasts are decreased and blood vessels obliterated⁴.

Various treatment modalities have been tried for management of oral submucous fibrosis:

1. Restriction of habits / Behavioral therapy
2. Medicinal therapy
3. Surgical therapy
4. Oral Physiotherapy

Grade 1 and Grade 2 patients can be managed conservatively by various procedures like intralesional hyaluronidase injections , placental extracts , chymotrypsin , interferon gamma , turmeric, pentoxifylline , antioxidants like lycopene⁵

Grade 3 and Grade 4 patients with limited mouth opening less than 25 mm have to be treated by surgical correction

Excision of the fibrotic bands is done under general anesthesia and the defect coverage is done using various types of flaps like Nasolabial flap, Buccal pad of fat, Radial Forearm flap, Superficial Temporal fascia flap, palatal island flap, tongue flap, Platysma myocutaneous flap, collagen membrane, split thickness skin grafts etc¹

The two most commonly used flaps are Nasolabial flap and Buccal Fat pad flap both having its advantages and disadvantages.

Nasolabial flaps

Nasolabial flap proved itself to be extremely vascular and thus a safe flap to use. This can be attributed to extensive vascular anastomosis involving the facial, transverse facial and infraorbital arteries. A 5 cm wide spindle-shaped flap is raised superior to the Nasolabial fold. The flap is raised in a subcutaneous fat plane and then rotated 90 degrees, pedicled to facial artery such that the skin faces the raw excised area of the buccal mucosa. Suturing the margins of the mucosa to the flap closes the defect in the mucosa, and the donor site is closed in layers. One stage reconstruction can be safely completed by de-epithelization and transbuccal tunneling (when indicated for intraoral use). It is a safe minor procedure done under general anesthesia with which good results can be achieved in small to moderately sized defects in oral and maxillofacial region.

.Interincisal mouth opening achieved with Nasolabial flap is satisfactory . It is a good choice for immediate reconstruction of anterior oral and maxillofacial defects following resection.The main disadvantages of Nasolabial flap are intraoral hair growth and extraoral scarring. If the defect is large a second surgery is needed to close the buccal tunnel. Risk of orocutaneousfistula, hematoma , infection and hypertrophic scarring particularly , if the donor site is closed under tension The extraoral scar formed in the nasolabial fold can be hidden in the Nasolabial crease⁶.

Buccal fat pad

Buccal fat pad functions well as a pedicled graft in the surgical management of oral submucous fibrosis. The bulk of the Buccal fat pad occupies the buccal space and rest on the periosteum that covers the posterior buccal aspect of the maxilla .The buccal fat pad has a rich blood supply through the small branches of the facial artery, the internal maxillary artery and the superficial temporal artery and vein by an abundant network of buccal anastomosis, Defects measuring up to 3 multiplied by 5 cm can be covered with Buccal fat pad without compromising the blood supply. The buccal extension and the main body of the buccal fat pad are in close proximity to the buccal defect and may be approached through the same incision. The healing is usually uneventful. Interincisal opening achieved is also satisfactory No particular disadvantages are seen with Buccal Fat Pad. When compared with Nasolabial flap interincisal

opening achieved intraoperatively and postoperatively is slightly better with Nasolabial flap. Limited coverage is one of the disadvantages of Buccal fat pad⁷.

Hence, we are doing a systemic review to compare the two most widely used flaps, Nasolabial flap and Buccal fat pad for the coverage of intraoral defects after release of fibrous bands in oral submucous fibrosis.

UNDER PEER REVIEW

REVIEW OF LITERATURE

1. **Rajesh Kshirsagar et al (2008)**, conducted a study on 6 medically fit patients with a chief complaint of restricted mouth opening and interincisal opening of less than 15 mm were chosen for this study. All third molars were extracted. Release of fibrous bands followed by bilateral intra-oral coronoidectomy was done as if interincisal opening was less than 35 mm was achieved intraoperatively. Bilateral Nasolabial flaps were raised in the supramuscular plane and transferred intraorally through the transbuccal tunnel. After release of fibrous bands a mean forced intraoperative mouth opening of 21.7 mm was achieved. Mean mouth opening of 39.6 mm was achieved at 6 months, with a mean increase of 26.8 mm. Two of the cases required coronoidectomy since the intraoperative mouth opening achieved was less than 35 mm. There was no incidence of infection in the transferred flap and the recipient site in all cases. Complications due to vascularity (blue flap or white flap) were not encountered, except for slight ecchymosis at the flap tips and suture margins, which subsided after 7-10 days post operatively. In this series of Nasolabial flaps, flap loss either partial or complete flap loss was not encountered. Other complications like flap necrosis, damage to parotid duct, ectropion were not observed. No major blood vessel damage in the operative region was encountered. Based on this study it was concluded that the nasolabial flap is a versatile flap, which can be successfully used in the

Comment [H3]: Modify and formatting required according to manuscript guidelines
Add latest literature
Present ROL is giving an impression of copy and paste from the original thesis/short study synopsis file only.

reconstruction of defects created after the release of fibrotic bands. The flap is a good solution for the functional problems but the inevitable scar created a drawback and may require a revision.

2. **R.M. Borle et al (2008)**, conducted a study on 47 patients using extended Nasolabial flaps in the management of oral submucous fibrosis. They had an interincisal opening of less than 25 mm and were treated by bilateral release of fibrous bands, coronoidectomy or coronoidotomy, and extended grafting with Nasolabial flap . Their interincisal opening improved significantly from a mean of 14mm (range 3-23)to a mean of 41mm (range 23-55) .Four patients had unsatisfactory mouth opening due to poor compliance . The transposed flaps were covered with mucosa by the end of 2 years, and the growth of hair was significantly reduced. Subjectively, 41 of the 47 patients reported a reduction in the burning sensation. There were minor complications such as partial flap necrosis particularly at the tips in 4 patients, distortion of the commissure in 1 patient, perforation of soft palate in 1 patient, postoperative infection in 1 patient. Hence, it was concluded from this study that Nasolabial flap was effective in the management of patients with oral submucous fibrosis , the main disadvantage being extraoral scars.

3. **Divya Melhotra (2009)**, conducted a study on 100 patients of oral submucous fibrosis which were divided into four groups 25 patients each .

Group 1 had buccal fat pad , group 2 had tongue flap , group 3 had Nasolabial flap , group 4 had split skin graft for correction of mucosal defect .Mean preoperative mouth opening was 14.82 mm and ranged between 4.00 and 25.00 mm . Excision of fibrous bands were done . Mean postoperative mouth opening at 1 month in group 1 was 36.36mm in group 1 , 35.36 mm in group 2, 35.64 mm in group 3 and 35.64 mm in group 4 Flap loss and Infection was not seen in any of the groups Intraoral hair growth was observed in the Nasolabial group .Number of patients were not observed who had intraoral hair growth . Relapse was not reported . Physiotherapy was done with wooden tongue depressors from the fifth postoperative day to 6 months . Followup ranged from 2 to 5 years , median 2.6 years . Hence , it was concluded that buccal fat pad rotation is superior to other procedures . because it offers ease of surgery , , can be performed under local anesthesia as a day care procedure , shows little postoperative morbidity , and has good patient acceptance , and there appear to be no contraindication of use.

4. **Surej kumar L. K (2010)**, conducted a case report on a 38 year old patient using buccal fat pad reconstruction for oral submucous fibrosis . The interincisal distance at the time of presentation was 14 mm . The mouth was then forced open with a mouth gag and an interincisal opening of 23 mm was recorded . Release of fibrous bands and bilateral coronoidectomy was done Post operative period was uneventful . Mouth opening exercises started on the third day . A

passive mouth opening of 35 mm and a forceful mouth opening of 40 mm has been maintained. Hence, it was concluded that buccal fat pad is a logical, reliable and convenient technique for the treatment of oral submucous fibrosis.

5. **Mohit Agarwal et al (2011)**, conducted a study on 27 randomly selected patients with histologically confirmed oral submucous fibrosis. Extended Nasolabial flaps were used to reconstruct the intraoral defect after bilateral release of bilateral fibrous bands and extended grafting with a Nasolabial flap. The interincisal opening improved significantly from a mean of 11 mm (range 3-19 mm) to a mean of 39 mm (range 23-48 mm) at the end of 6 months and persisted without relapse for 1 year of follow-up. Two patients had unsatisfactory mouth opening because of poor compliance. Subjectively, 23 of the 27 patients reported a reduction in the burning sensation. There were some minor complications: partial flap necrosis in 2 cases, postoperative infection in 1 case, perforation of soft palate in 1 case. There were some disadvantages in some patients like unsightly extraoral scars, and intraoral growth of hair in men, but growth of hair decreased with time and no patient required scar revision.

6. **Chandrasekhar R. Bande (2012)**, conducted a comparative study on 20 patients comparing Extended Nasolabial flap and Platysma myocutaneous flap for reconstruction of intraoral defects after release of oral submucous fibrosis. In the nasolabial group the mean preoperative interincisal mouth opening was

12mm (range 3-14 mm) , and in the platysma group it was 11(3-13 mm) The interincisal opening improved to 47 mm in the Nasolabial group and 48 mm in the platysma group .There were some minor complications like immediate subluxation seen in 2 patients of the Nasolabial flap group and 2 patients in the platysma group . Distortion of commissure in 1 patient off Nasolabial group and no patient of platysma group encountered distortion of commissure . Perforation of soft palate was observed in 2 patients of Nasolabial flap and 1 patient of the platysma group . Partial necrosis of flap was seen in 1 patient of Nasolabial flap and 1 patient of platysma flap group . Hence, it was concluded from the current study that platysma muscle flap is recommended rather than extended Nasolabial flap for reconstruction of intraoral defects after release of oral submucous fibrosis , as facial aesthetics are not compromised , and the risks of broadening of the commissure and a pinched appearance of the lips are avoided. As the incision is some way from the face , the scars are hidden underneath collars, and the patient compliance was good.

7. **K. Saravanan et al (2012)**, conducted a study on 8 cases with proven oral submucous fibrosis where buccal fat pad was used to cover the intraoral defects in oral submucous fibrosis . The range of preoperative mouth opening was 3-18 mm (mean 14 mm) . Release of fibrous bands followed by cornoidectomy was done . Intraoperative mouth opening was ranged from 25 -38 mm . The patient's were discharged 5-7 days after the operation . The range of the mouth opening

at this time was 25 – 36 mm . The pedicled grafts took up unevenly and epithelialized in 3-4 weeks. One patient failed to exercise several times daily and finally experienced a significant relapse . The buccal fat pad by virtue of its anatomic position and excellent blood supply , the ease with which it can be accessed and mobilized , without any donor site morbidity , proved to be logical, convenient and reliable interpositional material . Hence, it was concluded that considering the favourable results of this study with the advantages offered , buccal fat pad seems to be an appropriate interpositional graft in the surgical management of oral submucous fibrosis .

8. **Anshul Rai (2012)**, conducted a comparative study of 20 patients with restricted mouth opening of less than 20 mm divided into two groups. In group 1 Nasolabial flap is used. In group 2 Buccal fat pad was used . Release of fibrous bands followed by bilateral coronoidectomy or coronoidotomy was done. A soft temporomandibular joint trainer was placed in the oral cavity for 10 days postoperatively to prevent occlusal trauma induced dehiscence of the flap . The oral physiotherapy was started after 48 hours with the help of wooden spatulas for 1 week followed by Hister's jaw exerciser to prevent contracture and relapse . The patient was instructed and motivated to do physiotherapy themselves for up to 1 year . In the present study, the average mouth opening after 20 months follow up was 41 mm when treated with buccal fat pad and 42 mm when treated with Nasolabial flap . In group 1 , 3 cases of subluxation was seen and in group

2 1 case of subluxation was seen . Distortion of commissure was observed in 2 patients of group 1 and no patient of group 2. Perforation of soft palate was seen in 1 patient in group 1 and 1 patient I group 2. Partial flap necrosis was seen in 2 patients of group 1 and 1 patient 1 patient of group 2 Postoperative infection was seen in no patient of the two groups. Hence, it was concluded that the use of Buccal fat pad as compared to the Nasolabial flap for reconstruction of the intraoral defects after release of fibrous bands in patients with oral submucous fibrosis. Buccal fat pad provides excellent functional and aesthetic results. Limitation of this study was that to know the long term results , studies with large samole size and long term follow up has to be done.

9. **M.C Kothari (2012)**, conducted a study to evaluate coronoidectomy , masticatory myotomy and buccal fat pad graft in management of advanced oral submucous fibrosis. 10 patients with clinically and histologically confirmed advanced oral submucous fibrosis underwent surgery. Results showed a mean interincisal opening of 14.7 mm. preoperatively and 32.5 mm at 12 months postoperatively . Relapse was encountered in one patient who did not cooperate with the postoperative exercise regime . From the third postoperative day , patients began mouth opening exercises using wooden sticks , an acrylic cone , Heister jaw opener or Shekhar's appliance four times a day for half an hour . All the patients were prescribed a nutrientsupplement such as vitamin A 50,000 IU in the form of chewable tablets once daily , Vitamin B complex tablets 200 mg

twice a day , vitamin c 500 mg once daily with topical triamcinolone acetonide 0.1% applied to the mucosal surface at bedtime for a minimum of 6 months postoperatively . Out of 10 patients, 9 were very co operative , but 1 patient restarted the habit and showed postoperative relapse with severe scarring followed by fibrosis after 3 months and 5 mm interincisal opening . Hence, it was concluded that in long term , advanced oral submucous fibrosis (stage 3 and stage 4) oral submucous fibrosis associated fibrous bands , coronoidectomy and masticator muscle myotomy followed by buccal fat pad grafting is a promising procedure as it helps the patient maintain the postoperative rehabilitation protocol and thereby provides long term relapse free results.

10. **Rohit Sharma (2012)**, conducted a study of 28 cases of clinically and histologically confirmed cases of oral submucous fibrosis where Buccal fat pad is used for the treatment of intraoral defects after release of fibrous bands of oralsubmucous fibrosis. Group 1 consisted of 15 patients with clinical stage 3 oral submucous fibrosis. Group 2 had 13 cases of oral submucous fibrosis with clinical stage 4. The mean preoperative mouth opening was 19.6 mm in group 1 and 12.92mm in group 2 .Postoperatively, all patients received postoperative antibiotics and nasogastric feeding for 1 week. Mouth opening exercises were started after 36 hours. This intensive exercise was carried out daily for at least 3 months and with reduced frequency for as long as 1 year. There was no evidence of graft failure , but recurrence of trismus and no remission of painful

ulceration , burning sensation , and intolerance to spices were found in 2 of 28 cases in group 2 .Compared with group 1 , the time taken for epithelialization of Buccal fat pad was greater in group 2 . Hence, it was concluded from the current study that Buccal fat pad functions well as a pedicled graft in the surgical management of oral submucous fibrosis.

11. **Preeti Tiwari (2013)**, conducted a review paper on what is the optimal reconstruction option for oral submucous fibrosis. This study highlighted the drawback of buccal fat pad in closing the anteriormost portion of the defect and the nasolabial flap in terms of intraoral hair growth and an extraoral scar. Patil et al compared extended Nasolabial flap versus Buccal Fat pad in their prospective pilot study. Although nasolabial flap provided the bulk for closure, it had several disadvantages as compared to Buccal fat pad. The pilot study by Rai et al favoured buccal fat pad over Nasolabial flap owing to fewer complications in the former group. Both the groups had certain similar complications like subluxation of the TMJ and fish mouth deformity, however, the nasolabial flap had significant aesthetic challenges. The study also highlighted that atrophy of the buccal fat pad leading to reduction in mouth opening can be controlled by aggressive physiotherapy, which is a limitation of Buccal fat pad. Hence, it was concluded that definitive conclusions cannot be drawn as there are number of limitations of the studies included. However a general consensus has been towards favouring buccal fat pad over Nasolabial

flap. The platysma myocutaneous flap owing to its excellent tissue bulk and fewer complications can be considered as an alternative when dealing with defects which are challenging to reconstruct with buccal fat pad.

12. **Pravin Lambade et al (2015)** conducted a prospective study of 20 patients of oral submucous fibrosis .In this study Nasolabial flap was used to reconstruct the fibrotomy defect in surgical management of oral submucous fibrosis . Patients selected for surgical procedure were having mouth opening less than 16mm . The surgical protocol was consisting of bilateral fibrotomy, temporal myotomy and coronoidectomy or coronoidotomy followed by reconstruction of fibrotomy defect with bilateral extended Nasolabial flap . Intraoperative mouth opening achieved was 32-44 mm with a mean of 44.5 mm . Post operative followup after 2 years was 38 mm with a range of 20-44 mm . Patients were advised vigorous mouth opening exercise from the seventh day of post surgery and prescribed multivitamin , iron supplements , and antioxidants . Intraoral hair growth was observed in posterior retromolar region where flap is part of the chin region below oral commissure . Extraoral scar was prominent in earlier days of postsurgery , it became insignificant and well hidden in the Nasolabial fold by the end of 2 years.In this study, it was concluded that random pattern Nasolabial flap is a very good option for intraoral reconstruction of fibrotomy defect in surgical treatment of oral submucous fibrosis with excellent functional and cosmetic results with minimal complications.

13. **Y.Kholakiya (2015)**, conducted a retrospective study on 18 patients with grade 4 oral submucous fibrosis by Nasolabial flap . Postoperatively , patients were administration 400 mg pentoxifylline thrice daily for 3 months Mean preoperative mouth opening of 8.11 ± 3.38 mm was observed .Using blunt dissection , all fibrous bands excised . After achieving an intra-operative mouth opening of at least 35 mm was observed, third molars were extracted and coronoidectomy was performed through the same incision . An intraoperative mouth opening of more than 35 mm was achieved in all cases. There was no case of partial/complete flap failure, infection or suture dehiscence. In the immediate postoperative period , 3 patients developed ecchymosis over the neck, which subsided spontaneously after two weeks . Pentoxifylline was well tolerated by all patient . Two patients developed headache after the administration of pentoxifylline . No allergic reactions were noted with the drug. Five patients complained of intraoral hair growth , however the density of hair decreased after 6 months and the remaining hair was removed by depilation. No hypertrophic scar or keloid formation was seen .After a follow- up period of 21.67 ± 6.87 months, mean mouth opening was 37.67 ± 3.74 mm Success rate was 100% with no case of recurrence. There was no incidence of relapse or rebound fibrosis. Hence, it was concluded from this case series that the use of oral pentoxifylline as an adjunct along with surgical reconstruction in

oral submucous fibrosis improves mouth opening, reduces burning sensation and relapse

14. **S.M Balaji (2016)**, conducted a retrospective analysis of 42 patients who underwent surgical management of oral submucous fibrosis with mouth opening less than 20 mm. Under nasoendotracheal intubation fibrous bands in the buccal mucosa were excised. Forcible mouth opening was achieved using mouth gags, and a satisfactory voluntary mouth opening was achieved. Mean mouth opening of 33.05mm with the range of 30-38 mm was achieved at the end of 2 year follow up. There was no incidence of infection in the transferred flap and the recipient site in all cases except one case with malignant transformation. Postoperatively, patients were prescribed nutritional and antioxidant supplements along with mouth opening exercises for at least 6 months. So, from the current study it was concluded that Nasolabial flap is a versatile flap, which can be successfully used in the reconstruction of fibrotic bands in oral submucous fibrosis.

15. **Faisal Idrees (2016)**, conducted a study of 11 randomly selected patients with histologically confirmed oral submucous fibrosis. They all had an interincisal opening of less than 25mm. After bilateral release of fibrous bands, coronoidectomy or coronoidotomy was done and extended grafting with a Nasolabial flap was done. Mouth opening exercises were started after a latent

period of 10 days, Interincisal opening was measured daily after 48 hours, from the 4th day upto the 10th day and then monthly up to 6 months . In all 11 patients, the range of the preoperative mouth opening was 0-18 mm . During the surgical procedure , the increase in intraoperative mouth opening ranged from 30 to 42 mm and improvement of 28.07 mm was achieved .There was no incidence of infection in the transferred flap and the recipient site in all but one case which could be attributed to the 7 day antibiotic regimen , regular intraoral irrigation of the flap, and thorough cleaning and dressing of donor wound. Complications due to vascularity were not encountered , except for slight ecchymosis at the flap tips and the suture margins ,which subsided after 2-3 days postoperatively . Intraoral hair growth was evident in eight out of 11 patients. Regular trimming of intraoral hair was carried out till the hair growth reduced in all patients. So it was concluded from this study that Nasolabial flap is a versatile flap , which can be successfully used in the reconstruction of defects created after release of fibrous bands . The interincisal opening achieved was maintained with minimal relapse till last follow up. It is cosmetically acceptable as the line of closure of donor site lies along the nasolabial crease .Although the extraoral scars were perceptible in all cases, they were readily accepted by the patients. So it was concluded from this study that bilateral single-staged Nasolabial flap is a viable and reliable option that has stood the test of time for reconstruction of intraoral defects in oral submucous fibrosis.

16. **Pravin Lambade (2016)**, conducted a prospective study on 20 patients using buccal fat pad in the surgical management of oral submucous fibrosis. The preoperative interincisal opening was less than 16 mm . Surgical procedure included fibrotomy, all third molar extractions , and coronoidectomy or coronoidotomy followed by reconstruction of fibrotomy defect with buccal pad of fat. Postoperatively , patients were prescribed nutritional and antioxidant supplements along with vigorous mouth opening exercise for 6 months. In this study , satisfactory mouth opening was achieved after 2 years of follow up with good mucolization of flap. Patient's occlusal function and tolerance to hot and spicy food was improved significantly. Limitations observed were its insufficient volume which cannot be extended beyond premolar or canine region . So, it is mostly advised when fibrous bands are present in posterior retromolar area and posterior buccal mucosa . Second , it is a very fragile tissue , which needs to be handled with care to prevent dehiscence and necrosis. Another drawback is frequent impingement on the graft tissue while mastication , so either needed periodic removal of excess tissue or holding the graft tissue in position with retentive sutures or supporting membranes. Hence, it was concluded that Buccal fat pad can be used effectively in the surgical management of oral submucous fibrosis with good functional and esthetic outcome , with only drawback of supple lobulated fat , which requires delicate handling and its limitation to reach anteriorly beyond the canine region .

17. **Sandeep B. Patil et al (2016)**, conducted a study on 8 patients divided into two groups of 4 namely group 1 and group 2. Mean preoperative mouth opening in group 1 was 8.5 mm and in group 2 was 11.75 mm . The mean increase in group 1 after one year of postoperative period was 21.50 mm and in group 2 was 24.75 mm After release of fibrous bands all patients underwent bilateral coronoidectomy Inter-incisal mouth opening of 40-45 mm was achieved for all patients . Intraoperative complications like damage to facial vessels, parotid duct and branches of facial nerve were not encountered in any of the 4 patients included in this study . None of the flaps showed either bluish discoloration due to venous congestion or whitish discoloration due to poor arterial blood supply in the postoperative phase and no infection was encountered in any of our cases . Intraoral hair growth was observed in 2 male patients from fifth postoperative day which was managed by regular trimming. Complications such as flap loss, flap avulsion, obstructive sialoadenopathy or wound dehiscence were not encountered with Nasolabial flap. The donor site healed uneventfully and flaps adapted to oral mucosa in all cases. In this case series, one 65 year old female patient of the Nasolabial flap group did not co-operate for vigorous postoperative exercise therapy and the condition relapsed in 3 months. With Buccal fat pad graft it was observed minimum donor site morbidity, rich vascular supply , ease of surgery which can be performed under local anaesthesia on an outpatient basis , improvement in physiologic functions of cheek after surgery , good patient acceptance , and minimal donor postoperative morbidity

while disadvantages being anterior reach of the graft are limited and limited use for larger defects. In this present study, buccal fat pad graft proved to give better results as the interposition material as it has good patient acceptance, rapid epithelization, minimal donor site morbidity and minimal intraoperative and postoperative complications.

18. **Gaurav Singh (2017)**, conducted a comparative prospective study on collagen membrane over buccal fat pad versus Buccal fat pad in management of oral submucous fibrosis. The study comprised of 40 patients of oral submucous fibrosis of group 4a (Khanna and Andrade) Patients were randomly divided into 2 groups. (20 patients in each group). Group 1 patient were treated with buccal fat pad only, whereas collagen membrane was used as a covering over harvested buccal fat pad in group 2. The mean preoperative mouth opening achieved was 13.55mm in group 1 and 13.06 mm in group 2. Release of fibrous bands and coronoidectomy was done. The mouth was then forced open with Heister jaw opener to an acceptable range of more than 35 mm. Prophylactic extraction of all erupted third molars was done. The mean postoperative mouth opening after 1 year was 35.48 mm in group 1 and 36.51 in group 2. In group 1, complete relapse was seen in 2 patients after 1 year follow up, they developed refrosis and trismus. Infection was evident in 4 patients of 20 group 1 cases. The wound dehiscence was noted in two patients after 1 week follow up which was subsequently managed conservatively. The time taken for complete

epithelialization of buccal fat pad was 2-3 weeks . Pain score was 2 on VAS after 1 week follow up. Average time taken to complete the surgical procedure in group 2 patient was 2hr 30 min. Infection was evident in four cases of group 1 , whereas none of the group 2 patients developed infection in post operative phase . After 1 week follow up , pain score was 4 in group 1 and 2 in group 2. Hence, it was concluded that collagen membrane is easily available , easy to use , economical , good tolerance of collagen by oral tissue and good adaptability over harvested Buccal fat pad . Though surgical time increases on application of collagen membrane , it is acceptable as pain score, physical trauma, food lodgement and consequent infection at surgical site are reduced . It provides sufficient protection and helps in maintain structural integrity of Buccal fat pad during healing phase.

19. **Rajesh Kshirsagar et al (2017)**, conducted a study on 32 patients evaluating the complications in the use of bilaterally inferiorly based Naosolabial flaps for advanced oral submucous fibrosis. 32 cases diagnosed with advanced oral submucous fibrosis were included in the study with interincisal opening less than 15 mm . After release of fibrous bands, coronoidectomy , bilateral reconstruction of fibrous bands of the intraoral defects with bilateral inferiorly based Naolabial flap . After release of fibrous bands and coronoidectomy , a mean unforced mouth opening of 26 mm was achieved . Mean mouth opening of 41 mm was achieved at 6 months, with a

mean increase of 29 mm. Out of the 32 patients 2 patients had partial flap necrosis , in which excision of the necrotic portion was done , both of these patients had undergone radiation for carcinoma of tongue . Intraoral hair growth was seen in two patients . An unacceptable extraoral scar at the donor site was seen in 8 patients i.e. 16 donor sites . Loss of nasomaxillary crease was seen in 6 patients . Orocutaneous fistulae occurred in two patients which were corrected surgically . Pincushioning effect around the Nasolabial fold was present in 6 patients . No surgical correction was performed of this complaint . Hence , it was concluded from this study that Nasolabial flap is a simple and viable treatment option for advanced oral submucous fibrosis in patients with interincisal opening less than 15mm . Complications commonly associated with Nasolabial flap include insignificant improvement in interincisal opening (13) partial necrosis , intraoral hair growth , and unacceptable extraoral scar . However the benefits far outweigh the risk of these complications . Moreover, the complications are minor in nature and can be corrected by local measures.

20. **Deepak Agarwal (2017)**, conducted a comparative clinical evaluation of the buccal fat pad and extended Nasolabial flap in the reconstruction of the surgical defect in oral submucous fibrosis patients . Total 32 patients were selected for the study . 21 patients underwent closure for the surgical defect using Buccal fatpad (group 1) and 11 patients underwent closure of the surgical defect using a Nasolabial flap .The preoperative mouth opening was no less than 25 mm . at 3

months follow up mean mouth opening increased to 32.41 mm in group 2 compared with 30.47 in group 1. Excision of fibrous bands and Bilateral coronoidectomy was done. No flap loss was observed in any of these cases. Wound dehiscence was observed in 2 patients of the Nasolabial flap group. Intraoral hair growth was also observed in the Nasolabial group though the number of patients was not mentioned. Follow up was done for a period of 6 months. Hence, it was concluded that Nasolabial flaps are a good option for the coverage of surgically treated defects in oral submucous fibrosis with the buccalfat pad.

21. **Sujeeth Kumar Shetty (2018)**, conducted a prospective study of 10 patients for covering intraoral defects with Nasolabial flap for the management of oral submucous fibrosis. Out of the 10 subjects, 7 subjects had defects in the buccal mucosa, one subject had defect in the anterior floor of the mouth, 1 subject had a defect in the maxillary alveolar mucosa, and 1 subject had a defect in the upper lip. After excision of the fibrous bands, Nasolabial flap was used to reconstruct the defect. Out of the 10 subjects treated under this study, nine subjects with 17 flaps showed excellent uptake and viability of flap with complete closure of the defect in the long term follow up. One unilateral flap had a necrosis of the flap leading to complete flap loss. Intraoral hair growth in 1 flap and bulky appearance in 4 flaps were noted. Scarring reduced from moderate to mild in 8 subjects, whereas it reduced from severe to moderate in 2.

subjects . Thus from this study it was concluded that Nasolabial flap proved itself to be extremely vascular and thus a safe flap to use.

22. **Muhammad Umar Qayyum (2018)**, conducted a study on 11 patients using Nasolabial and Extended Nasolabial flaps for reconstruction of intraoral defects in oral submucous fibrosis. Stage 3 or stage 4a maximum interincisal opening were selected to be operated. The preoperative mouth opening ranged from 5 to 16 mm. Release of fibrous bands and inferiorly based Nasolabial flap was used to cover the intraoral defect. At 6 months the mouth opening ranged from 29 to 39 mm. Some of the complications encountered were poor scar, wisdom tooth traumatising the flap, decreased mouth opening due to non-compliance and too much bulk. All of these were managed satisfactorily. So, it was concluded from the present study that the Nasolabial flap is a very reliable flap to restore the functions of oral cavity. Important adjuvant measures are habit cessation, lifestyle changes and aggressive physical therapy.

23. **Kamal Kanthan (2019)**, conducted a case report and review of literature on Recurrent oral submucous fibrosis with nil mouth opening .Bilateral Nasolabial flap was used to reconstruct the introral defect. A 66 year old male patient reported with progressive inability to open his mouth for past three months. His past medical history revealed surgery for oral submucous fibrosis followed by reconstruction with skin graft five years ago .An MRI scan for cheek and neck

revealed fibrosis of cheek mucosa with no other significant lesions suggestive of malignancy .Surgical release of fibrous bands , bilateral coronoidectomy , extraction of non-restorable teeth and reconstruction with bilateral inferiorly based nasolabial flap was done. Oral Physiotherapy was initiated 48 hours post surgery using Heister's mouth gag and the patient was motivated to actively continue the same to maintain the achieved mouth opening .The flap division was done 21 days later and orocutaneous tunnel was closed . The patient maintained interincisal distance of 28 mm after five years with no further recurrence or deterioration in mouth opening. From this case report it was concluded that the random pattern of nasolabial flaps could be considered a good option for recurrent cases of oral submucous fibrosis requiring a second surgery and reconstruction of the fibrotomy buccal mucosal defects.

UNDER PEER REVIEW

METHODOLOGY

An elaborate data base search using engines (Google Scholar, Pubmed, Ebsco Host, Medline, Cochrane Library and Embase) was done to collect articles pertaining to Surgical Management of Oral submucous fibrosis using Nasolabialflap and Buccal fat pad to reconstruct the intraoral defects post-fibrotomy. The study selection was restricted to articles published in English and from the year 1950 until July 2021. The boolean terms used for the search were oral submucous fibrosis, fibrotomy defect, fibrous bands, OSMF, buccal pad of fat, bichat's flap, bichat's fat pad, nasolabial flap, extended nasolabial flap and banana flap.

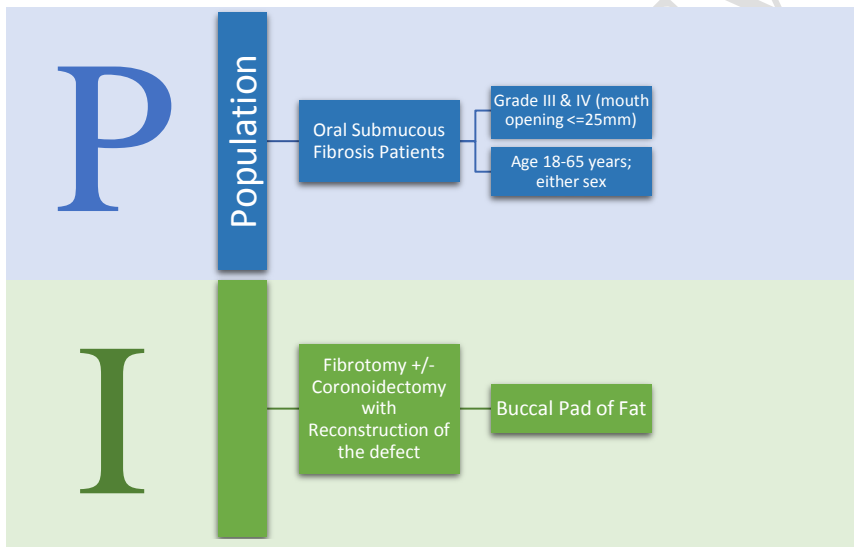
("Oral Submucous Fibrosis"[Mesh] OR "oral"[All Fields] AND "submucous"[All Fields] AND "fibrosis"[All Fields] OR "oral"[All Fields] AND "submucous"[All Fields] AND "fibroses"[All Fields] OR "fibrous bands"[All Fields] AND ("Surgical Flaps"[Mesh] OR "surgical flaps"[All Fields] OR "surgical"[All Fields] AND "flaps"[All Fields] OR "Fibrotomy"[All Fields] OR "fibrous"[All Fields] AND "bands"[All Fields] AND "excision"[All Fields] OR "fibrous bands excision"[All Fields]) AND ("buccal fat"[All Fields] OR "buccal pad"[All Fields] OR "buccal"[All Fields] AND "pad"[All Fields] AND "fat"[All Fields] OR "bichat"[All Fields] AND "fat"[All Fields]) OR

("nasolabial flap"[All Fields] OR "nasolabial"[All Fields] AND "flap"[All Fields] OR "extended nasolabial flap"[All Fields] OR "banana flap").

The type studies included were systematic review, randomized control trials and original research. The review was done in accordance with Preferred Reporting Items for systematic Reviews and Meta-Analysis (PRISMA) statement guidelines after a detailed PICO analysis.

PICO Analysis:

What is a better option for reconstruction post-fibrotomy in oral submucous fibrosis patients: buccal pad of fat or nasolabial flap?



C

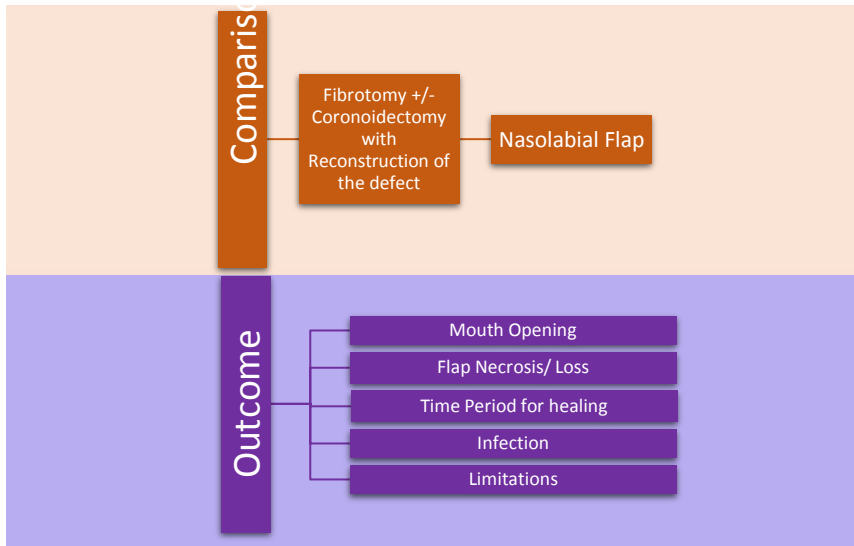


Fig 1.

Steps in Surgical management of Oral Submucous fibrosis:

1. Incision for Fibrotomy

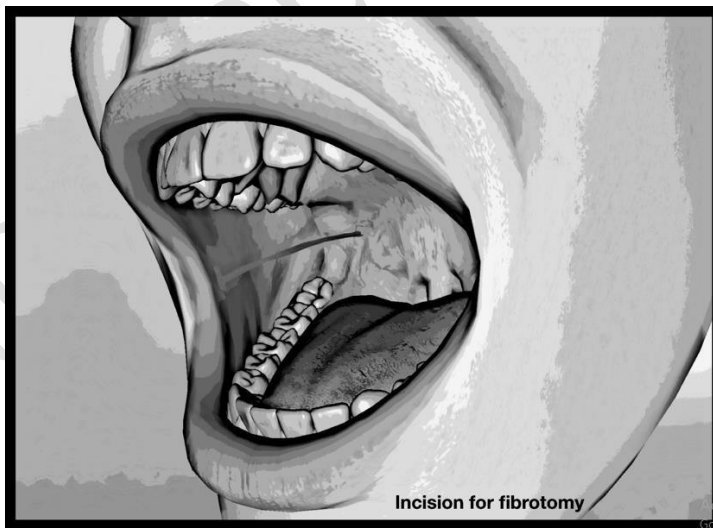


Fig 2. Incision for Fibrotomy

1. Excision of Fibrotic bands

UNDER PEER REVIEW

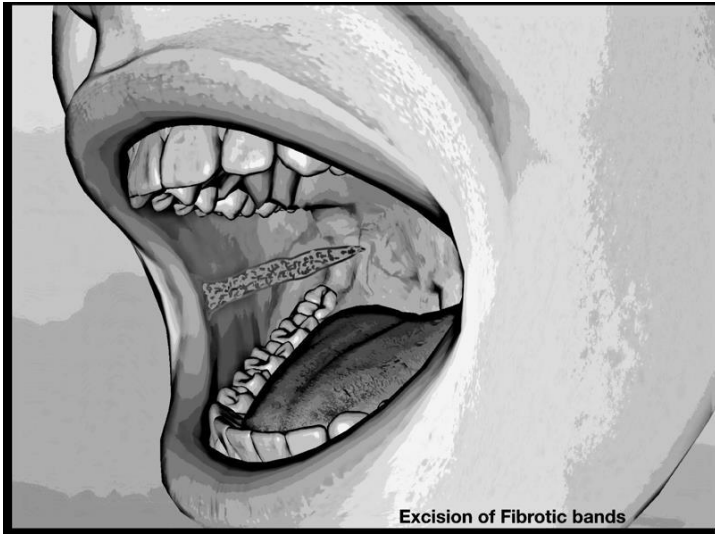


Fig 3. Excision of Fibrotic bands

2. Coronoidectomy

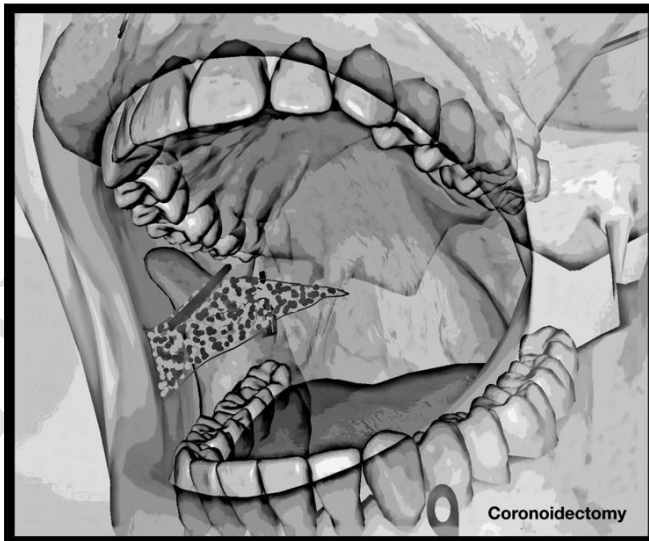


Fig 4. Coronoidectomy

1. Option 1: Buccal Fat Pad harvest

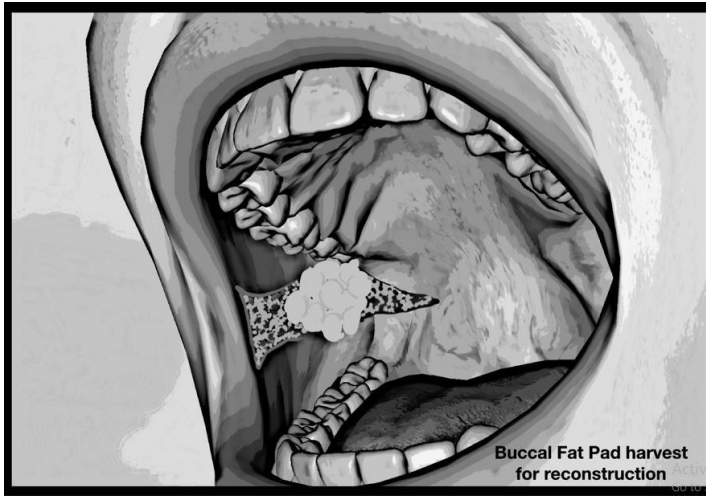


Fig 5. Buccal Fat Pad harvest

Option 2: Nasolabial Flap harvest

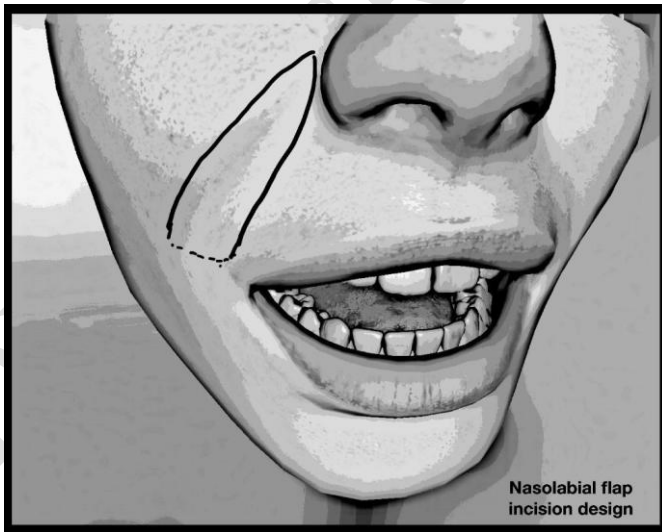


Fig 6. Nasolabial Flap harvest

2. Flap Inset

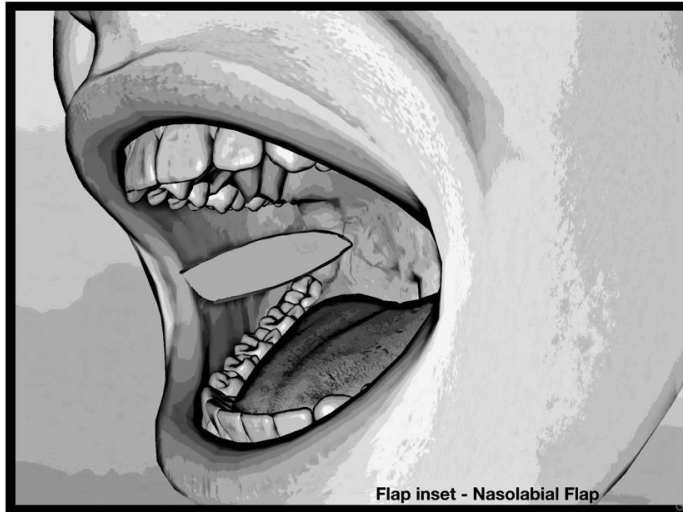


Fig 7. Flap Inset

The following were the inclusion and exclusion criteria for the same

INCLUSION CRITERIA

1. Comparative human trials (randomized/ non-randomized) for treatment options for oral submucous fibrosis using buccal pad fat or nasolabial flap.
2. Studies comparing the two treatment options for reconstruction of fibrotomy defects.
3. Studies based on data with patients having mouth opening less than or equal to 25mm or less, and falling under Grade 3 or Grade 4 oral submucous fibrosis (Khanna and Andrade classification 1995)

4. Studies comprising data from patients between the age of 18 to 65 years.

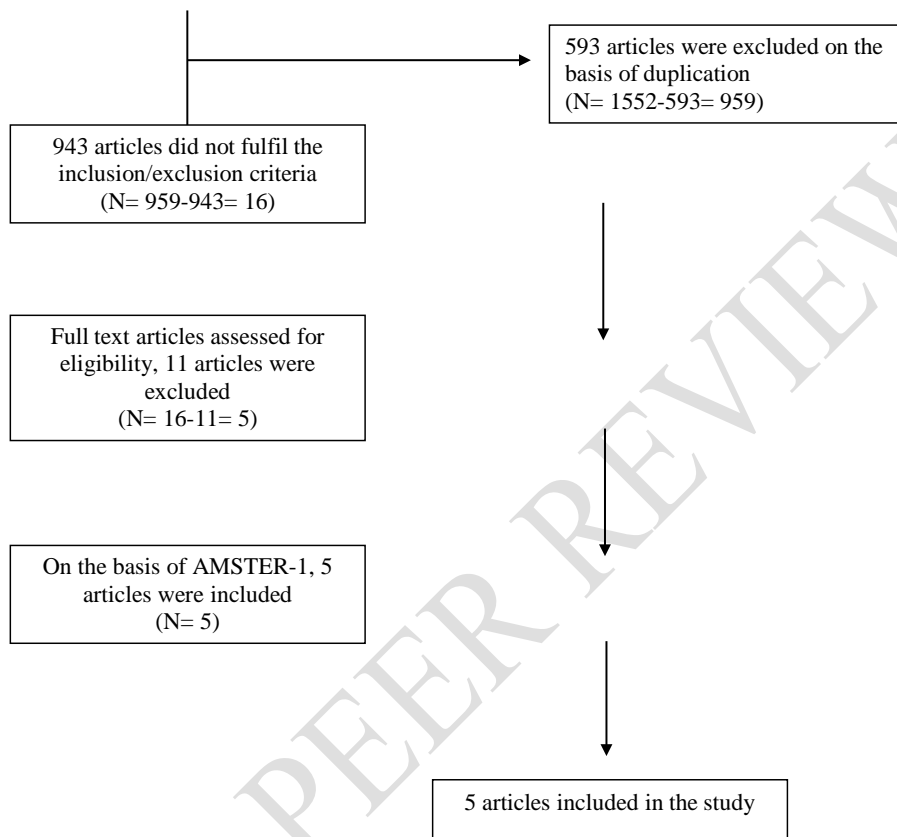
EXCLUSION CRITERIA

1. Non-comparative studies for treatment of oral submucous fibrosis using buccal fat pad or nasolabial flap.
2. Case reports / case series.
3. Studies where treatment was done using other reconstructive options like skin graft, collagen membrane, platysma myocutaneous flap, temporal fascia, etc.
4. Studies where the cause of trismus was not oral submucous fibrosis.
5. Studies on patients with history of radiotherapy for cancer in the past one year.
6. Grade 1 and Grade 2 oral submucous fibrosis

PRISMA CHART

Chart 1. Prisma Chart

Records identified via database searching: Pubmed= 68 Google Scholar= 1480 Cochrane= 4 Total= 1552
--



After the initial selection, careful reviewing of the full text was done to extract information on the following criteria

1. Infection: Pus discharge, exudate formation are the signs of infection.
2. Flap loss: Gaping of flap, wound dehiscence can result in flap loss
3. Relapse: Relapse is seen in patient who either started the previous habit or patients who failed to continue the mouth opening exercises
4. Interincisal opening: On an average Interincisal mouth opening of 40 – 45 mm is achieved with Nasolabial flap. Interincisal opening of 40 mm is also achieved postoperatively with nasolabial flap
5. Physiotherapy: Proper postoperative mouth opening exercises can lead to good postoperative mouth opening. Physiotherapy is done with Heister's jaw opener from the second postoperative day in most studies. Failure to do proper mouth opening exercise can lead to decreased mouth opening
6. Follow up: Follow up in most studies has been done for a period of 2 years. The quality, quantity and risk of bias of various study was evaluated by using AMSTAR-2, scale after which data collection was done.

Table 1. Literature review

AMSTER 1

Name of article	Author	Inclusions of pico	Review method and significant deviation	Rerason for selection of study design	Comprehensive literature search	Study selection in duplication
A comparative clinical evaluation of the buccal fat pad and extended	Deepak Agarwal et al	Yes	PartialYes	No	Yes	No
Retrospective comparison of surgical treatment modalities in 100 patients with Oral submucous fibrosis	Divya malhotra et al	Yes	No	No	Yes	No
Surgical interventions in oral submucous fibrosis: A systematic analysis of the literature	Venkatesh V Kamath et al	Yes	No	No	Yes	No
Comparison of extnted nasolabial flap vs buccal fat pad graft in the management of oral submucous fibrosis - A comparative clinical evaluation of the buccal fat pad and extended: A prospectiv	Sandeep B patil	Yes	No	No	Yes	No

e pilot study						
What is the optimal reconstructive option in oral submucous fibrosis ? A systemic review and meta analysis of buccal fat pad vs conventional nasobial and extended nesobial flap vs platysma vs myocutaneous flap	Rabindranath Bera et al	Yes	No	No	Yes	No

AMSTER 1 contd.

Name of article	Author	Exclusion criteria and its justification	Detailed description of Pico in study	Exclusion of risk of bias	Source of functioning	Stat Analysis done if meta analysis is included
A comparative clinical evaluation of the buccal fat pad and extended	Deepak Agarwal et al	No	Yes	Yes	No	No
Retrospective comparison of surgical treatment modalities in 100 patients with Oral submucous fibrosis	Divya malhotra et al	No	Yes		No	No
Surgical interventions in oral submucous fibrosis: A systematic analysis of the literature	Venkatesh V Kamath et al	No	Yes		No	No
Comparison of extended nasolabial flap vs buccal fat pad graft in the management of oral submucous fibrosis - A comparative clinical evaluation of the buccal fat pad and extended: A prospective pilot study	Sandeep B patil	No	Yes	Yes	No	No

<p>What is the optimal reconstructive option in oral submucous fibrosis ? A systemic review and meta analysis of buccal fat pad vs conventional nasobial and extended nesobial flap vs platysma vs myocutaneous flap</p>	<p>Rabindranath Bera et al</p>	<p>No</p>	<p>Yes</p>		<p>No</p>	<p>Yes</p>
--	--------------------------------	-----------	------------	--	-----------	------------

UNDER PEER REVIEW

AMSTER 1 contd.

Name of article	Author	Impact of ROB if meta analysis is performed	Effect of ROB in data interpretation	Explanation for heterogeneity	Investigation on publication bias on quantitative synthesis and its impact on result	report on conflict of interest including finding
A comparative clinical evaluation of the buccal fat pad and extended	Deepak Agarwal et al				Yes	No
Retrospective comparison of surgical treatment modalities in 100 patients with Oral submucous fibrosis	Divya malhotra et al			Yes		No
Surgical interventions in oral submucous fibrosis: A systematic analysis of the literature	Venkatesh V Kamath et al		No	No	No	No
Comparison of extended nasolabial flap vs buccal fat pad graft in the management of oral submucous fibrosis - A comparative clinical evaluation of the buccal fat pad and extended: A prospective pilot study	Sandeep B patil			No	No	No

<p>What is the optimal reconstructive option in oral submucous fibrosis ? A systemic review and meta analysis of buccal fat pad vs conventional nasobial and extended nesobial flap vs platysma vs myocutaneous flap</p>	<p>Rabindranath Bera et al</p>	<p>No</p>			<p>No</p>	<p>No</p>
--	--------------------------------	-----------	--	--	-----------	-----------

UNDER PEER REVIEW

RESULT

A systematic review of the literature search revealed five relevant articles according to the inclusion and exclusion criteria; comparing the effectiveness of Buccal Fat Pad, and Nasolabial flap as reconstructive options in OSMF. These studies were used for data extraction and meta-analysis.

Study Characteristics

Within the five included studies, one was retrospective study; two were prospective comparative studies and one systematic review. All the articles were from peer reviewed indexed sources. All the studies originated from the Indian subcontinent. Study by Patil et al.^[1] and Agrawal et al.^[2] compared the buccal pad of fat with extended nasolabial flap. Rathindra Nath Bera^[3] performed systematic review on Buccal Pad of Fat Versus Conventional Nasolabial and Extended Nasolabial Flap Versus Platysma Myocutaneous Flap and Venkatesh Kamath^[4] performed Systematic analysis to compare Buccal fat pad, Nasolabial flap, collagen membrane, palatal island flap, temporalis fascia flap, radial forearm flap and tongue flap. The predictor variable for all the studies was a reduced mouth opening, > 15 mm and who were histologically confirmed cases of OSMF. All studies determined the effect of treatment variables by assessing the results after following patients post-operatively for various time periods, up to 6 months (Agrawal et al.^[2]), 2-5 years (Mehrotra et

al.^[5]), 6months-3 years (Bera et al.^[3]), 1 year (Patil et al.^[1]), and 36-66 months (Kamath et al.^[4]).

Results of the Individual Studies

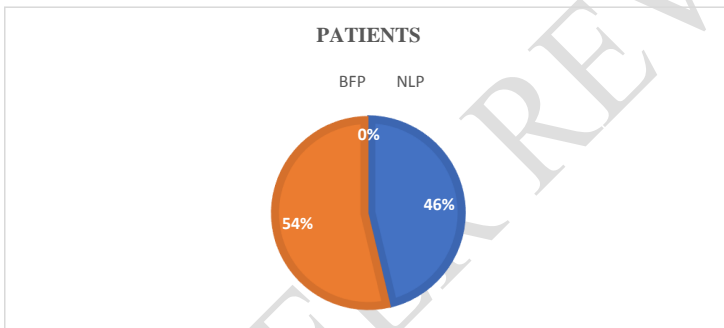
All the five studies used both Buccal pad of fat and Nasolabial flap for surgical management of OSMF. In the study by Agrawal et al.^[2], total patients were 32 (BFP- 21, NLF-11) and achieved a mouth opening of 29.7 ± 3.5 mm (BFP), 33 ± 5.8 mm (NLF). He found flap necrosis in 1 patient who underwent NLF and infection in 2 patients with BFP without any relapse. In the study by Mehrotra et al.^[5], total patients were 50 (BFP-25, NLF-25) and achieved mouth opening of 34.3mm(BFP), 35.4mm (NLF). There was no relapse and post-operative physiotherapy was done using wooden tongue depressor. Bera et al.^[3] included a total of 80 patients (BFP- 35, NLF- 45) in his study with a mean post-operative mouth opening of 28.07mm (BFP) and 32mm (NLF). Patil et al.^[1] compared the Extended Nasolabial flap and Buccal fat pad with a total of 8 patients (BFP-4, NLF-4) and achieved mouth opening of 21.5mm(BFP), 24.75mm(NLF). He found relapse in 2 patients (BFP-1, NLF-1) and post-operative physiotherapy was done using ice-cream sticks. Kamath et al.^[4] included a total of 314 patients (BFP-139, NLF-175) in his study with a mean post-operative mouth opening of 35.5mm(BFP) and 34.4mm(NLF).

Quality of the Studies

Quality assessment of the included clinical trials, retrospective and prospective cohort studies was executed according to AMSTER-1. All the five studies were of moderate quality.

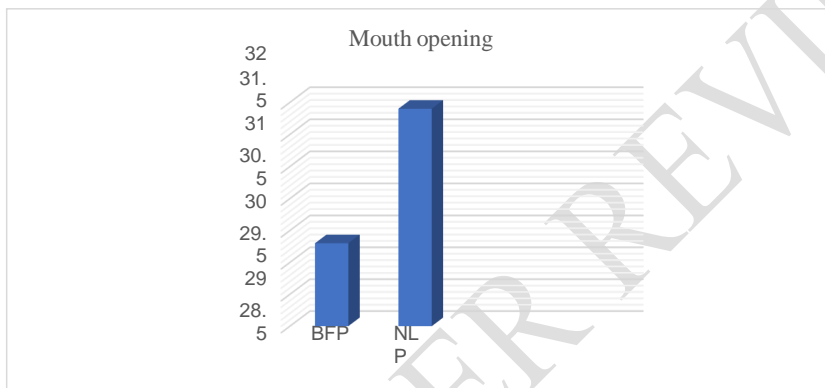
Synthesis of Results

As measured in all the five studies, the total number of patients were 484 (BFP- 224, NLP-260) (Graph 1). The mean post-operative mouth opening achieved after using BFP was 29.8mm and using NLF was 31.9mm with an average follow up of 26.4 months (Graph 2). Flap necrosis was found in 1 patient in the NLF group and 2 patients had post-operative infection in the BFP group. Most preferred method of doing post-operative physiotherapy was using ice cream sticks. Two patients reported with relapse (1 in BFP, 1 in NLF). The main limitation of most of the studies were short sample size and follow up period.



Graph-1 Total patients in each group





Graph-2: Mean post-operative mouth opening

MASTER CHART

1	Author	Mouth Opening	Flap Necrosis/ Loss	Follow up	Infection	Limitation	Physiotherapy	Relapse	Total cases
2	Deepak Agarwal	29.7± 3.5mm (BFP), 33 ± 5.8mm (NLF)	1 out of 11 (NLF)	6 months	2 out of 21 (BFP)	Short sample size and follow up		None	21-BFP, 11-NLF=32
3	Divya Mehrotra	34.3mm (BFP), 35.4mm (NLF)		2-5 years			With wooden tongue depressor	None	25-BFP, 25-NLF=50
4	Rathindra Nath Bera	28.07mm(BFP), 32mm (NLF)		6months-3 years		Limited studies			BFP-35, NLF-45=80
5	Sandeep B Patil	21.50mm(BFP), 24.75mm(NLF)		1 year			Mouth prop, ice cream sticks	1-BFP, 1-NLF	4-BFP,4-NLF=8
6	Venkatesh V Kamath	35.5mm(BFP), 34.4mm(NLF)		2-36 months, 6-36 months					139(BFP), 175(NLF)=314
7	Average/Mean	29.8-BFP, 31.9-NLF	1	26.4 months	2-BFP	Short sample size and follow up	ice cream sticks	1-BFP, 1-NLF	BFP- 224, NLF-260, TOTAL=484

Chart 2.

DISCUSSION

Oral submucous fibrosis is a chronic, progressive, precancerous condition of oral mucosa, oropharynx and rarely larynx, commonly seen in the Indian subcontinent. Epidemiological data show that the number of cases has increased rapidly in India from an estimated 250,000 cases in 1980 to 2 million cases in 1993. Various treatment modalities have been described. Medicinal management can be done for grade 1 and grade 2 cases of oral submucous fibrosis (Khanna and Andrade classification). For more severe cases release of fibrous bands is done. Coronoidectomy is done in patients when intraoperative mouth opening achieved is not satisfactory. Various types of intraoral and extraoral flaps have been used to cover the intraoral defect created after release of fibrous bands of oral submucous fibrosis. Most commonly used intraoral flaps are buccal fat pad, tongue flap, greater palatine artery flap whereas extraoral flaps are Nasolabial flap, platysma myocutaneous flap, radial forearm flap, temporoparietal fascia flap. Split thickness skin graft and certain alloplastic materials like collagen membrane can also be used to cover the intraoral defect. The two most widely used flap for the surgical management of oral submucous fibrosis are the Nasolabial flap and the Buccal fat pad. Hence, in this systemic

review we compared Nasolabial flap and Buccal fat pad in surgical management of oral submucous fibrosis. Parameters included in this review are interincisal mouth opening, intraoral hair growth, flap loss, extraoral scarring, relapse, physiotherapy and follow up.

Interincisal mouth opening: In the comparative study by Bande et al.⁷ the mean preoperative interincisal mouth opening in nasolabial group was 12mm (range 3-14 mm), and in the platysma group was 11mm (range 3-13 mm). Post-operatively the interincisal opening improved to 47 mm in the Nasolabial group and 48 mm in the platysma group. Kholakiya et al⁸ utilized the Nasolabial flap in his study with a mean preoperative mouth opening of 8.11 ± 3.38 mm and achieved a post-operative opening of 35 mm. Saravanan¹ et al employed buccal fat pad with a preoperative mouth opening of 3-18 mm (mean 14 mm) and achieved a post-operative mouth opening of 38 mm. In our study the mean postoperative mouth opening is 29.8 mm with buccal fat pad and 31.9 mm with Nasolabial flap.

Intraoral hair growth: Lambade et al⁴ treated oral submucous fibrosis using Nasolabial flap and observed intraoral hair growth in posterior retromolar region. Idrees et al²⁴ conducted a study with a Nasolabial flap. Intraoral hair growth was evident and regular trimming of intraoral hair was carried out till

the hair growth reduced in all patients. In our study 8 cases of Nasolabial flap had intraoral hair growth.

Flap loss: Shetty²⁸ et al utilised Nasolabial flap in 10 subjects. Nine subjects with 17 flaps showed excellent uptake and viability of flap with complete closure of the defect in the long term follow up. One unilateral flap had a necrosis of the flap leading to complete flap loss. In our study 1 of 11 cases had flap loss in the Nasolabial flap group.

Extraoral scar: Kshirsagar et al²³ conducted a study using the inferiorly based nasolabial flap which led to an unacceptable extraoral scar at the donor site. Lambade et al⁴ observed an extraoral scar, which was prominent in initial days of post-surgery, it became insignificant and well hidden in the nasolabial fold by the end of 2 years. In our study, we observed extraoral scar in 2 cases of Nasolabial flap

Physiotherapy: Kanthan et al¹⁴ initiated oral physiotherapy 48 hours post- surgery using Heister's mouth gag. Melhotra et al¹⁵ employed wooden tongue depressors for post-surgery physiotherapy. In our study we observed ice cream sticks as the most preferred method for oral physiotherapy.

Follow up: Singh et al¹⁵ compared collagen membrane over buccal fat pad versus Buccal fat pad in management of oral submucous fibrosis with follow up ranged of 2 to 5 years. Mehrotra et al followed up patients for 2-55 years after the surgical treatment of oral submucous fibrosis. Kamath et al had a mean follow up of 6-36 months in his study. In our study mean duration of follow up observed is 26.4 months.

Limitation of the study was short sample size and limited follow up.

UNDER PEER REVIEW

CONCLUSION

In this systematic review, we are reviewing two types of flaps Nasolabial flap and buccal fat pad graft as an interpositional graft material for covering intraoral defects after release of fibrous bands in oral submucous fibrosis. Certain criteria are checked using the two types of flaps like infection, wound dehiscence, flap loss, type of procedure followed, physiotherapy, follow up, relapse. In studies it has been observed that using Nasolabial flap gives good postoperative mouth opening but certain postoperative complications has been reported with Nasolabial flap like intraoral hair growth, extraoral scar formation, wound dehiscence, postoperative infection. Aesthetic concerns are present using Nasolabial flap. Patient satisfaction level is less after using Nasolabial flap to cover the intraoral defects. After using buccal fat pad graft to cover intraoral defects postoperative complications are reported to be minimal. Postoperatively, physiotherapy is an important factor for maintaining the postoperative mouth opening. It has been observed that patients not following proper mouth opening exercises failed to maintain the intraoperative mouth opening achieved during surgery. Relapse occurred in such patients.

REFERENCES

1. Saravanan K, Narayanan V. The use of buccal fat pad in the treatment of oral submucous fibrosis: a newer method. *International journal of dentistry*. 2012 May 15;2012
2. Kothari MC, Hallur N, Sikkerimath B, Gudi S, Kothari CR. Coronoideotomy, masticatory myotomy and buccal fat pad graft in management of advanced oral submucous fibrosis. *International journal of oral and maxillofacial surgery*. 2012 Nov 1;41(11):1416-21.
3. Singh G, Mishra M, Gaur A, Srivastava A, Shukla B, Das G. Collagen membrane over buccal fat pad versus buccal fat pad in management of oral submucous fibrosis: A comparative prospective study. *Journal of maxillofacial and oral surgery*. 2018 Dec;17(4) 482:17
4. Lambade P, Meshram V, Thorat P, Dawane P, Thorat A, Rajkhokar D. Efficacy of nasolabial flap in reconstruction of fibrotomy defect in surgical management of oral submucous fibrosis: a prospective study. *Oral and maxillofacial surgery*. 2016 Mar 1;20(1):45-50..
5. Mehrotra D, Pradhan R, Gupta S. Retrospective comparison of surgical treatment modalities in 100 patients with oral submucous fibrosis. *Oral Surgery, Oral Medicine, Oral Pathology, Oral Radiology, and Endodontology*. 2009 Mar 1;107(3):e1-

Comment [H4]: Add and cite latest references.

6. Rai A, Datarkar A, Rai M. Is buccal fat pad a better option than nasolabial flap for reconstruction of intraoral defects after surgical release of fibrous bands in patients with oral submucous fibrosis? A pilot study: a protocol for the management of oral submucous fibrosis. *Journal of Cranio-Maxillofacial Surgery*. 2014 Jul 1;42(5):e111-6.
7. Lee JT, Cheng LF, Chen PR, Wang CH, Hsu H, Chien SH, Wei FC. Bipaddled radial forearm flap for the reconstruction of bilateral buccal defects in oral submucous fibrosis. *International journal of oral and maxillofacial surgery*. 2007 Jul 1;36(7):615-9
8. Huang JJ, Wallace C, Lin JY, Tsao CK, Kao HK, Huang WC, Cheng MH, Wei FC. Two small flaps from one anterolateral thigh donor site for bilateral buccal mucosa reconstruction after release of submucous fibrosis and/or contracture. *Journal of plastic, reconstructive & aesthetic surgery*. 2010 Mar 1;63(3):440-5.
9. Angadi PV, Rao S. Management of oral submucous fibrosis: an overview. *Oral and maxillofacial surgery*. 2010 Sep;14(3):133-42.
10. Agarwal R, Kaushal A, Singh RK, Upadhyay Y. Management of oral submucous fibrosis by different surgical approaches: report of three cases. *Case Reports*. 2013 Jan 2;2013:bcr2012007871.
11. Bande C, Dawane P, Gupta MK, Gawande M, Rode V. Immediate versus delayed aggressive physical therapy following buccal fat pad

interposition in oral submucous fibrosis—a prospective study in Central India. *Oral and maxillofacial surgery*. 2016 Dec;20(4):397-403.

12. Tiwari P, Bera RN, Chauhan N. What is the Optimal Reconstructive Option for Oral Submucous Fibrosis? A Systematic Review and Meta- analysis of Buccal Pad of Fat Versus Conventional Nasolabial and Extended Nasolabial Flap Versus Platysma Myocutaneous Flap. *Journal of Maxillofacial and Oral Surgery*. 2020 May 5:1-8.
13. Agrawal D, Pathak R, Newaskar V, Idrees F, Waskle R. A comparative clinical evaluation of the buccal fat pad and extended nasolabial flap in the reconstruction of the surgical defect in oral submucous fibrosis patients. *Journal of Oral and Maxillofacial Surgery*. 2018 Mar 1;76(3):67
14. Sharma R, Thapliyal GK, Sinha R, Menon PS. Use of buccal fat pad for treatment of oral submucous fibrosis. *Journal of oral and maxillofacial surgery*. 2012 Jan 1;70(1):228-32.
15. Patil SB, Durairaj D, Kumar GS, Karthikeyan D, Pradeep D. Comparison of extended nasolabial flap versus buccal fat pad graft in the surgical management of oral submucous fibrosis: A prospective pilot study. *Journal of maxillofacial and oral surgery*. 2017 Sep;16(3):312-21.
16. Thukral H, Chowdhury SK, Nagori SA. Surgical management of oral submucous fibrosis using buccal fat pad: a retrospective study of 30 cases. *Oral and maxillofacial surgery*. 2018 Dec;22(4):403-

17. Lambade P, Dawane P, Thorat A. Efficacy of buccal fat pad in the surgical management of oral submucous fibrosis: a prospective study. *Oral and maxillofacial surgery*. 2016 Jun 1;20(2):167-70.
18. Surej KL, Kuriem NM, Sakkir N. Buccal fat pad reconstruction for oral submucous fibrosis. *National journal of maxillofacial surgery*. 2010 Jul;1(2):164.
19. Kamath VV. Surgical interventions in oral submucous fibrosis: a systematic analysis of the literature. *Journal of maxillofacial and oral surgery*. 2015 Sep;14(3):521-31.
20. Balaji SM. Versatility of nasolabial flaps for the management of severe trismus in oral submucous fibrosis. *Indian Journal of Dental Research*. 2016 Sep 1;27(5):492.
21. Mukherjee S, Dandagi S. Versatility of buccal pad fat and temporoparietal fascia flap in surgical management of oral submucous fibrosis. *Annals of maxillofacial surgery*. 2019 Jul;9(2):444.
22. Kshirsagar R, Mohite A, Gupta S, Patankar A, Sane V, Raut P. Complications in the use of bilateral inferiorly based nasolabial flaps for advanced oral submucous fibrosis. *National journal of maxillofacial surgery*. 2016 Jul;7(2):115.

23. Idrees F, Patel P, Newaskar V, Agrawal D. Surgical defect coverage in oral submucous fibrosis patients with single-stage extended nasolabial flap. *Oral and maxillofacial surgery*. 2016 Dec;20(4):411-5.
24. Kshirsagar R, Chugh A, Rai A. Bilateral inferiorly based nasolabial flaps for the management of advanced oral submucous fibrosis. *Journal of maxillofacial and oral surgery*. 2010 Mar 1;9(1):22-6.
25. Borle RM, Nimonkar PV, Rajan R. Extended nasolabial flaps in the management of oral submucous fibrosis. *British Journal of Oral and Maxillofacial Surgery*. 2009 Jul 1;47(5):382-5.
26. Pandey A, Sharma NK, Dhiman NK, Jaiswara C, Tiwari P, Singh AK, Verma V, Singh S. Comparative evaluation of buccal pad of fat with and without bovine collagen membrane in the management of oral submucous fibrosis: A prospective clinical study. *National Journal of Maxillofacial Surgery*. 2020 Jan;11(1):57.
27. Shetty SK, Sarkar S. The Versatility of Nasolabial Flaps in Maxillofacial Surgery. *Journal of maxillofacial and oral surgery*. 2019 Dec;18(4):589-9
28. Qayyum MU, Janjua OS, Haq EU, Zahra R. Nasolabial and extended nasolabial flaps for reconstruction in oral submucous fibrosis. *Journal of the Korean Association of Oral and Maxillofacial Surgeons*. 2018 Aug 1;44(4):191-7.