

Techniques for the safety use of high-frequency ultrasound-guided for facial procedures: A Technical Note

ABSTRACT

Background: The knowledge of facial anatomy and its correlation with ultrasonography is crucial for several professionals in clinical practice. Therefore, understanding facial anatomical structures through dynamic ultrasonography images is essential for the clinical practice of guided aesthetic facial procedures. The purpose of this study is to demystify and provide a clear understanding of high-frequency guided ultrasound in facial aesthetic procedures, using visual aids and analogies to simplify the learning process.

Study design: The authors present a technical note outlining a protocol for the safe use of high-frequency ultrasound-guided facial procedures.

Discussion: Proper training is necessary for the use of high-frequency ultrasound in facial procedures to enhance the quality of treatments and achieve more positive outcomes. This technology allows real-time monitoring of the muscular and vascular anatomy while applying injectable products on the face, helping to prevent complications such as vascular occlusions. However, guided aesthetic procedures often face challenges due to operators' lack of experience and knowledge of correct protocols. To address this, we provide a step-by-step approach to performing ultrasound-guided procedures more efficiently. The pedagogical approach used in this manuscript, utilising a flight plan analogy, provides a clear and concise understanding of the practical application of ultrasound (US) in facial aesthetics, making the learning process simple and effective.

Keywords: Aesthetics, Ultrasound-guided, Facial aesthetics, Safety

1. INTRODUCTION

Historically, the pioneering research into the utilisation of ultrasound in the healthcare field for medical diagnostic purposes was conducted by Karl Theodore Dussik in 1942 [1].

Since then, the fundamental principles of ultrasound have been based on generating ultrasonic waves produced by a transducer, which transmits the waves to the target area for evaluation [2]. The transducer then receives sound echoes reflected from these structures, producing **anatomical** images, including soft tissues, vessels, collections, **tumors**, and other structures [3].

This understanding of the physical principles has led to the development of other innovative ultrasound modalities, such as contrast-enhanced ultrasound, Doppler for studying blood flow, elastography for the non-invasive determination of tissue elasticity, and real-time guidance in interventional procedures [4].

As a result, medicine has greatly benefited from the increased use of ultrasound in clinical practice across various specialties, including its application in both diagnostic and therapeutic processes [5]. A good example is using ultrasound-guided invasive procedures in dermatological and aesthetic treatments [6,7].

The face contains numerous anatomical variations and anastomoses within its various layers and compartments [8-12]. The use of high-frequency Doppler ultrasound during injectable procedures is likely to minimise the occurrence of vascular complications. Ultrasound imaging can confirm the aesthetic materials' accurate positioning within the targeted facial layers. In cases where complications have already arisen, ultrasound can diagnose the most likely underlying cause and guide the appropriate treatment [13-15].

2. STUDY DESIGN:

Technical note for the safety use of high-frequency ultrasound guidance for facial procedures.

There are some factors that must be considered to make a correct diagnosis using guided ultrasound, such as the device: 23MHz, ultrasound transducer, ultrasound sterile gel*, the use of an injection simulator for practising, syringe, and cannula 22G.

*It is worth noting that invasive procedures pose a risk of infection due to introducing foreign objects into the body. The sterile gel acts as a barrier between the instrument and the body, minimising the transmission of microorganisms that may cause infections.

There are some general considerations when choosing a portable ultrasound machine for facial aesthetic procedures:

Image quality: Look for an ultrasound machine that produces high-quality images of the facial area to help guide your procedures accurately.

Portability: Consider a lightweight, compact ultrasound machine that can easily move around the clinic or office.

User-friendliness: Choose an ultrasound machine that is easy to use and has intuitive controls to reduce the learning curve.

Versatility: Look for an ultrasound machine that has different probes or attachments that can be used for a variety of facial aesthetic procedures, such as skin rejuvenation, facial contouring, or wrinkle reduction.

Price: Consider the cost of the ultrasound machine and whether it fits within your budget.

3. PROCEDURE

3.1 Making learning simple

To help simplify the learning process, a novel and pedagogical approach will be presented to illustrate the technique of ultrasound-guided procedures. Using a flight plan analogy, this method provides a clear and concise understanding of the practical application of ultrasound in facial aesthetics.

The probe is akin to a radar or GPS system, while the needle serves as the airplane. To ensure a safe and successful procedure (similar to a safe flight), it is crucial to have a well-defined plan in place (basic preparation), initiate the procedure with confidence (needle introduction), navigate any obstacles that may arise (identify and map vessels through Doppler technology), make any necessary adjustments during the procedure (when the view of the needle is lost), and ultimately achieve a successful outcome (see Figure 1).

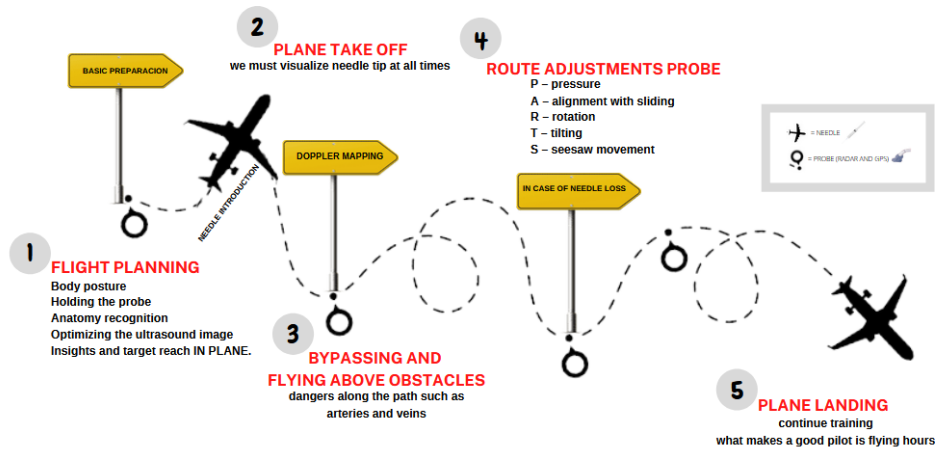


Fig.1. Essential Steps for a Successful Ultrasound-Guided Procedure Flight Plan (Kindly provided by Dr Vivian Almeida Castilho).

3.2 Body posture and holding the probe

Hand-eye coordination can pose a significant challenge for inexperienced practitioners. However, proper ergonomics can greatly aid in improving performance and minimising the risk of error.

Keeping the elbows close to the body is recommended to ensure optimal hand-eye coordination and reduce the likelihood of needle misalignment during the procedure. The probe should be firmly gripped between the thumb and the second and third fingers (Figure 2). Additionally, it is advisable to rest the hand on the patient for stability and use the fourth and fifth fingers for additional support. These simple measures can greatly improve the accuracy and precision of the method

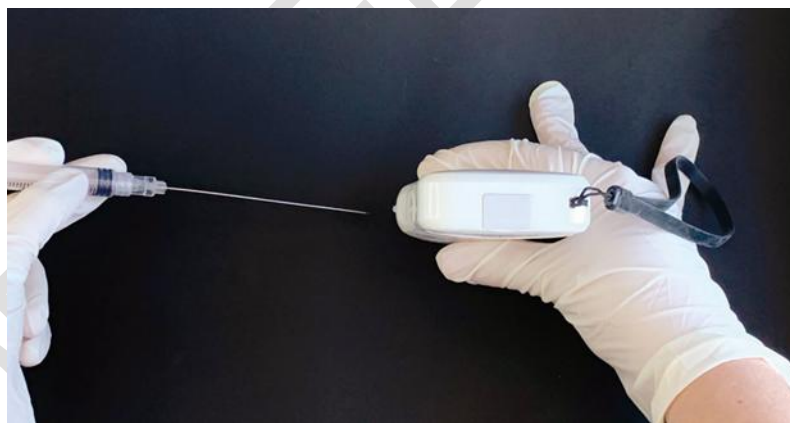


Fig. 2. Anatomy recognition (Kindly provided by Publisher Napoleon Quintessence).

The first step in ensuring a successful ultrasound-guided procedure is to accurately identify the anatomical layers in the targeted region where the injection will be performed. This information can be obtained through Doppler technology, which allows for a clear mapping of the area of interest and the identification of the path of vessels and their exact location within the anatomical planes. Figure 3 provides a visual representation of the different layers of the face, allowing for a clear understanding of the anatomy and the importance of proper needle placement [2,16,17].

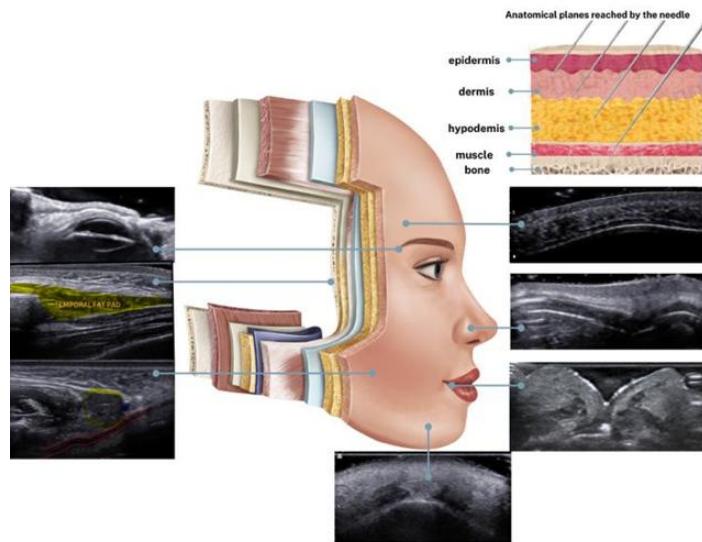


Fig. 3. Optimising the ultrasound image (Kindly provided by Publisher Napoleon Quintessence).

3.3 Check the basic machine parameters

- Frequency (must be high, greater than at least 15 Mhz)
- Depth (center the area of interest on the screen)
- Gain (adjust to your visual preference)
- Focus (center the focus on the level of your interest area)

Determine your approach: in-plane (the US beam is longitudinal to the needle) or out-of-plane (the US beam is transverse to the needle). In-plane is the preferred option as it allows for easier visualisation of the entire needle and its tip in real-time, as illustrated in Figure 5 [2].

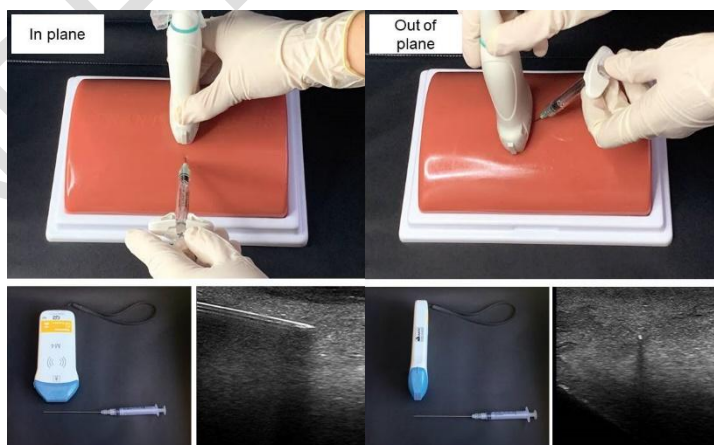


Fig. 5. In-plane (Longitudinal plane) or out-of-plane ultrasound technique (Transverse plane) (Kindly provided by Publisher Napoleon Quintessence).

3.4 Reach your target using the In-plane approach (Longitudinal)

Ensure you have selected the appropriate needle diameter and length to suit the probe diameter and length. To further ensure accuracy, you may choose to measure the distance from the target to the probe's limit, as illustrated in the figure below (Figure 6). This will give you a better understanding of the needle's reach and will confirm that you have the necessary tools for completing the procedure [2,16,17].

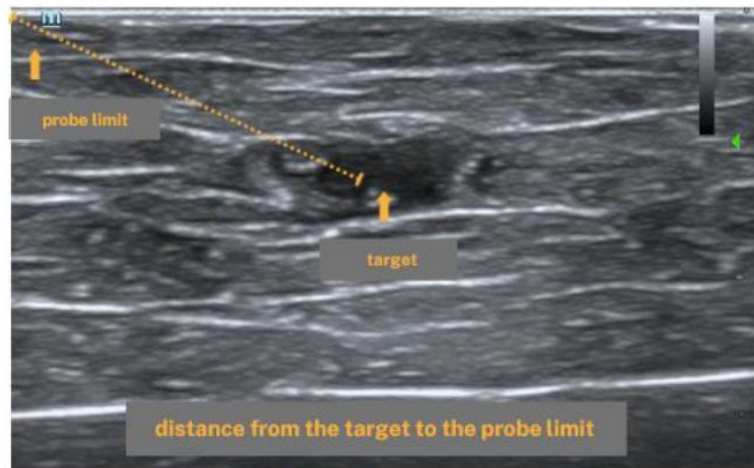


Fig. 6. Distance from the target to the probe limit(Kindly provided by Dr Vivian Almeida Castilho).

3.5 Consideration of target depth and angle (Figure 7)

Position the target in the centre of the screen for optimal visualisation.

Always insert the needle parallel to the ultrasound beam for optimal visualisation of the needle.

For shallow targets (typically less than 2 cm in depth), use a low insertion angle, approaching as close to parallel with the probe as possible.

For deeper targets, increase the insertion angle; the deeper the target, the harder it becomes to visualise the needle due to the physics of the US beam.

Refer to the accompanying figure for visual aids and further clarification [1,16,17].

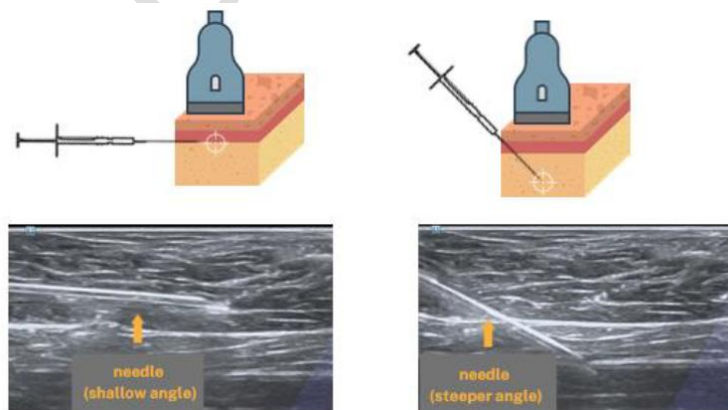


Fig. 7. Shallow angle and the steeper angle of the needle site of skin insertion (Kindly provided by Publisher Napoleon Quintessence).

Gently lower your gaze to the probe and skin. Carefully insert the needle into the centre of the probe, aligning it precisely with the beam, as shown in Figure 8.

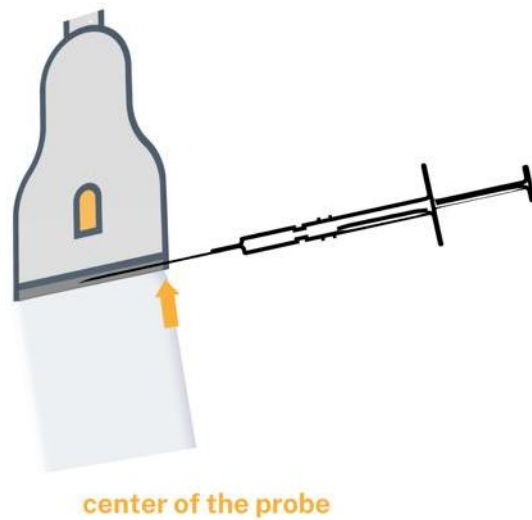


Fig. 8.Site of skin insertion (Kindly provided by Dr Vivian Almeida Castilho).

3.6 Plane Take-off

As the needle is inserted, it is crucial to monitor its tip for efficacy and safety constantly. During the injection process, the operator should focus on the screen rather than their hands.

To ensure accuracy, be cautious not to misinterpret the needle's positioning. If the needle appears to be oblique to the beam, it may actually be part of the needle shaft (Figure 9).

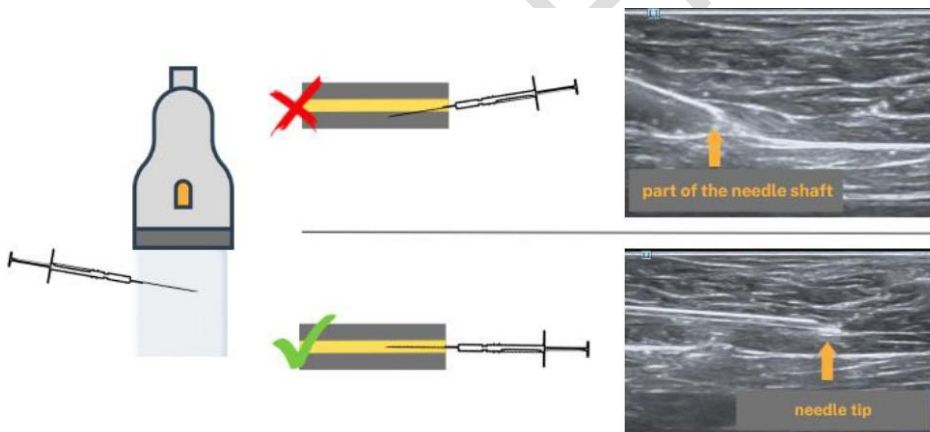


Fig. 9.Monitoring the tip for both efficacy and safety purposes (Kindly provided by Dr Vivian Almeida Castilho).

Ensure that the needle bevel faces upwards (towards the epidermis), as this direction creates a useful diagnostic artefact known as the "double echo". This double echo indicates that the needle tip is being viewed, not its shaft, as shown in Figure 10.

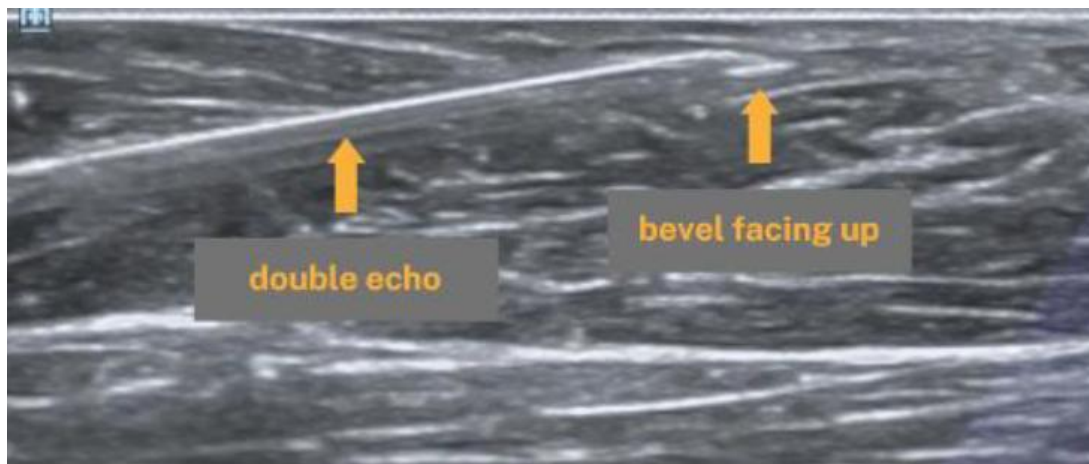


Fig. 10. Needle bevel facing upwards. Avoiding and negotiating obstacles (Kindly provided by Dr Vivian Almeida Castilho).

Be mindful of potential hazards along the injection path, such as arteries and veins. Turning on the Colour Doppler before starting the injection can assist in bypassing vessels or avoiding unwanted intravascular injection, as demonstrated in Figure 11.

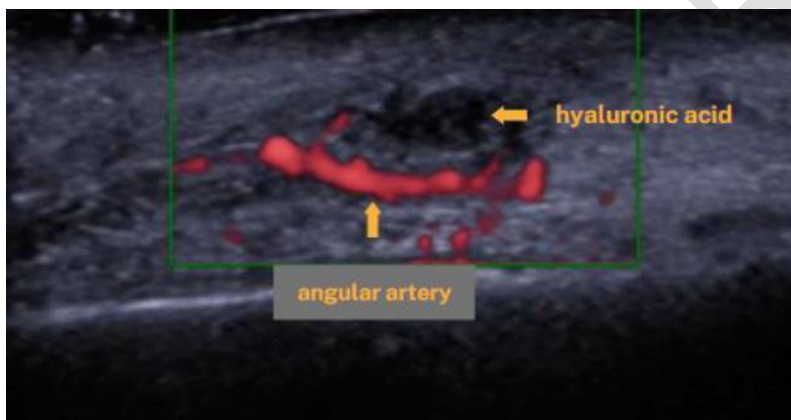


Fig. 11. Potential hazards along the injection path (Kindly provided by Dr Vivian Almeida Castilho).

3.7 Route Adjustment

During the injection process, there may be times when adjustments need to be made. It is important to remember that the needle tip location is constantly changing. If you lose needle-beam alignment, use the following four probe movements, remembered by the acronym PARTS:

P - Pressure: apply very light pressure (to avoid compressing veins and even arteries in the face).

A - Alignment with sliding: This is the primary movement for re-aligning the needle and beam. Always make "micromovements" (small, millimetric movements).

R - Rotation: only used if there is a significant misalignment.

T - Tilting: The main objective is to define layer boundaries. Maintaining the tilt used at the beginning of the procedure is essential.

S - Seesaw movement of the needle: If none of the above probe movements helps in visualising the needle tip, use the seesaw motion of the needle, moving it up and down while observing its action on the screen.

This will help to locate the needle tip and realign the needle with the probe again. Another possible movement is jiggling the needle. Upon successfully observing the product injection in real-time in the appropriate anatomical plane, carefully remove the needle and maintain your training regimen. Before progressing to live patient training, practising on a phantom or simulated tissue is recommended.

4. DISCUSSION

When administering cosmetic products without visualisation, there is a risk of accidentally depositing the product in unintended anatomical or intravascular areas. Due to a limited number of trained professionals in this technology, sharing tips and best practises can make the technique more accessible and widely used.

It is essential to extend the application of high-frequency ultrasound (US) to the facial area to ensure the safety and optimal image quality required for these procedures. The lack of literature on this topic emphasises the need for additional publications to advance our understanding of high-frequency ultrasound in facial aesthetics [18, 19, 20].

The popularity of facial aesthetic procedures using fillers has increased significantly in recent times. However, this rise has also led to an increase in immediate aesthetic complications, such as embolisation of materials in arteries and veins, and late complications, such as nodules and excess products that require further removal [3, 21, 22].

The use of high-frequency ultrasound-guided facial procedures has changed the field of aesthetic medicine, providing practitioners with potentially more precise and effective methods for enhancing patient outcomes while reducing the likelihood of adverse events [2, 21]. To ensure the safety of these procedures, the use of sterile gel is crucial in reducing the risk of tissue damage during invasive medical procedures [23]. When instruments come into contact with body tissue, friction can cause tissue trauma and increase the chances of infection. Sterile gel plays a vital role in preventing such issues by offering lubrication, which effectively mitigates the risk of infection [24].

Several studies have emphasised the importance of using sterile gel during invasive procedures. A research conducted in India revealed that sterile gel reduced catheter-related infections by 46% compared to non-sterile gel [20]. Similar investigations conducted in various countries have also shown that sterile gel is crucial in minimising the risk of infections [25,26].

Filler materials are substances with different rheological qualities that can lead to various clinical outcomes. They are categorised based on their intended use. Therefore, it is essential to perform a guided ultrasound procedure to confirm the precise site of injection. The rheological characteristics of filler materials, such as viscosity and elasticity, significantly influence their clinical efficacy, resulting in different behaviours when injected into specific body areas. As a result, selecting a suitable filler product for a particular indication requires careful consideration of the clinical implications of using materials with varying mechanical properties [27,28].

Additionally, a US-guided procedure can be conducted before and after injection to ensure the proper placement of the filler material and prevent migration from the intended site. Ultrasound technology is used to visualise the injection site, facilitating the identification of the exact location of the filler material. The accurate placement of the filler material at the targeted injection site is fundamental for achieving optimal clinical outcomes [27,28]. Hence, there is a need for increased education and training in using high-frequency ultrasound for facial procedures [29,30].

The proposed didactic approach could serve as a valuable framework for addressing this knowledge deficiency by providing education and training on using high-frequency ultrasound in facial aesthetics. By improving the understanding of clinicians and researchers, this approach could promote the safe and effective use of high-frequency ultrasound in facial procedures.

The limited existing literature highlights the importance of expanding and refining the use of this technique while ensuring safety and optimal image quality. Proposing the extension of high-frequency ultrasound application to the facial area is imperative to address the knowledge deficit. Therefore, this paper advocates for a didactic approach to advance our understanding of high-frequency ultrasound in facial aesthetics, reinforcing the need for additional publications to enhance the body of knowledge in this area. The pedagogical approach used in this manuscript, utilising a flight plan analogy, provides a clear and concise understanding of the practical application of US in facial aesthetics, making the learning process simple and effective. Guiding a needle to its target and administering an injection can be challenging, especially when the needle tip is difficult to visualise. To shorten the learning curve and enhance performance, having access to practical and instructional tips is paramount. Just as with flying, where logging flight hours is crucial in developing skills

and proficiency, obtaining hands-on experience and guidance in needle guidance and injection techniques is equally important.

REFERENCES

1. Sundaram H, Voigts B, Beer K, Meland M. Comparison of the rheological properties of viscosity and elasticity in two categories of soft tissue fillers: calcium hydroxylapatite and hyaluronic acid. *Dermatol. Surg.* 2010; 36(3): 1859-65. DOI: 10.1111/j.1524-4725.2010.01743. x.
2. Donola G, Castilho V, Peron D. *Complicações e uso da Ultrassonografia na Estética Facial e Cosmiatria.* 1sted. Nova Odessa, SP, Napoleão Quintessence. 2022.
3. Cotofana S, Steinke H, Sattler G, Friebe PR, Schroeter CA, Vogt PM. The Anatomy of the Facial Vein: Implications for Plastic, Reconstructive, and Aesthetic Procedures. *Plast Reconstr Surg.* 2017; 139(6):1346-53. DOI: 10.1097/PRS.0000000000003382.
4. Vasconcelos-Berg R, Chagas AM, Magalhães RRF, Muller A, Navarini AA, Sigrist RMS. Doppler ultrasound-guided filler injections: useful tips to integrate ultrasound in the daily practice. *Aesthet Surg J.* 2023;3:sjac353. DOI: 10.1093/asj/sjac353.
5. Kadouch J, Schelke LW, Swift A. Ultrasound to Improve the Safety and Efficacy of Lipofilling of the Temples. *Aesthet Surg J.* 2021; 41(5): 603-12. DOI: 10.1093/asj/sjaa066.
6. Moore CL, Copel JA. Point-of-care ultrasonography. *N Engl J Med.* 2011; 364(8):749-57. DOI:10.1056/NEJMr1916062.
7. Ahuja AT, Ying M. Ultrasound in dermatology. In: Lui H, Maibach H, editors. *Handbook of Systemic Drug Treatment in Dermatology.* Springer; 2015; 33-44.
8. Hufschmidt K, Bronsard N, Foissac R, Baqué P, Balaguer T, Chignon-Sicard B, et al. The infraorbital artery: clinical relevance in esthetic medicine and identification of danger zones of the midface. *J Plast Reconstr Aesthet Surg.* 2019; 72(1): 131-36. DOI: 10.1016/j.bjps.2018.09.010.
9. DeLorenzi C. Anatomical Variations in the Course of Labial Arteries: A Literature Review. *Aesthetic surgeryjournal.* 2019; 39(11):1236-40. DOI: 10.1093/asj/sjy235.
10. Cotofana S, Raffaini M, Massei A, Redka-Swoboda W, Schneider W, Prestinaci F, et al. Facial Arterial Variations in Asians: A Study on Computed Tomographic Angiography. *Aesthet Surg J.* 2022; 42(5): 535-36. DOI: 10.1093/asj/sjab380.
11. Lee KL, Lee HJ, Youn KH, Kim HJ. Positional relationship of superior and inferior labial artery by ultrasonography image analysis for safe lip augmentation procedures. *Clin Anat.* 2020; 33(2):158-64. DOI: 10.1002/ca.23379.
12. Tansatit T, Phumyoo T, Jitaree B, Sawatwong W, Rungsawang C, Jiirasat N, et al. Ultrasound evaluation of arterial anastomosis of the forehead. *J Cosmet Dermatol.* 2018; 17(6):1031-36. DOI: 10.1111/jocd.12755.
13. Iwayama T, Hashikawa K, Osaki T, Yamashiro K, Horita N, Fukumoto T. Ultrasonography-guided cannula method for hyaluronic acid filler injection with evaluation using laser speckle flowgraphy. *Plast Reconstr Surg Glob Open.* 2018; 6(4): e1776. DOI: 10.1097/GOX.0000000000001776.
14. Munia MA, Munia CG, Parada MB, Parente JBH, Wolosker N. Doppler ultrasound in the management of vascular complications associated with hyaluronic acid dermal fillers. *J Clin Aesthet Dermatol.* 2022; 15(2): 40-43.
15. Lee W, Kim JS, Moon HJ, Yang EJ. A safe Doppler ultrasound-guided method for nasolabial fold correction with hyaluronic acid filler. *Aesthet Surg J.* 2021; 41(6): NP486-NP92. DOI: 10.1093/asj/sjaa153.
16. Kim HJ, Youn KH, Kim JS, Kim YS, Hong SO, Na J. Ultrasonographic anatomy of the face and neck for minimally invasive procedures: an anatomic guideline for ultrasonographic-guided procedures. 1st ed. 2021. Springer.
17. Kim SY, Chung HW, Oh TS, Lee JS. *Practical Guidelines for Ultrasound-Guided Core Needle Biopsy of Soft-Tissue Lesions: Transformation from Beginner to Specialist.* Korean J Radiol. 2017; 18(2): 361-69. DOI: 10.3348/kjr.2017.18.2.361.
18. Nie B, Jie X, Yang W, Su Y, Zhang W, Zhao Y, Xu W, Zhu L. High-Frequency Ultrasound-Guided Temporal Fat Transplantation: A Safe and Visualized Approach. *Plast Reconstr Surg.* 2023; 10-97. DOI: <https://doi.org/10.1097/prs.0000000000010211>.
19. Cipolletta E, Filippucci E, Incorvaia A, Schettino M, Smerilli G, Di Battista J, Tesei G, Cosatti MA, Di Donato E, Tardella M, Di Matteo A. Ultrasound-guided procedures in rheumatology daily practice: feasibility, accuracy, and safety issues. *JCR: J Clin Rheumatol.* 2021; 27(6):226-31. DOI: 10.1097/RHU.0000000000001298.
20. Castilho, VA, Furtado GRD, Oliveira RCG, Barbosa, KL. First ultrasound report of temporal extension of bichat fat: correlation between anatomy and ultrasonography. *Res., Soc. Dev.* 2022; 11(11): e342111133586. DOI: 10.33448/rsd-v11i11.33586.
21. Wortsman X. *Textbook of Dermatologic Ultrasound.* Cham: Springer; 2022. ISBN: 978-3-031-08735-6.
22. Del Cura JL, Aza I, Zabala RM, Sarabia M, Korta I. US-guided Localization and Removal of Soft-Tissue Foreign Bodies. *Radiographics.* 2020; 40(4):1188-95. DOI: 10.1148/rg.2020200001.

23. Lai NM, Lai NA, O'Riordan E, Chaiyakunapruk N, Taylor JE, Tan K. Skin antisepsis for reducing central venous catheter-related infections. *Cochrane Database Syst Rev.* 2016; 7:CD010140.DOI: 10.1002/14651858.CD010140.pub2.
24. Centers for Disease Control and Prevention. Healthcare-associated infections. <https://www.cdc.gov/hai/surveillance/index.html> (accessed January 31, 2022).
25. Jehanjir W, Ali F, Sabih. Ultrasound scan, coupling gel as a source of infection. *Int J Infect Dis.* 2012; 16(1): E467. DOI:<https://doi.org/10.1016/j.ijid.2012.05.677>.
26. Cheng A, Sheng WH, Huang YC, Sun HY, Tsai YT, Chen ML, et al. Prolonged postprocedural outbreak of *Mycobacterium massiliense* infections associated with ultrasound transmission gel. *Clin Microbiol Infect.* 2016; 22(4): 382.e1-382.e11. DOI: 10.1016/j.cmi.2015.11.021.
27. Nielsen MB, Segard SB, Bech Andersen S, Skjoldbye B, Hansen KL, Rafaelsen S, et al. Highlights of the development in ultrasound during the last 70 years: A historical review. *Acta Radiol.* 2021; 62(11):1499-14.DOI: 10.1177/02841851211050859.
28. Stocks D, Sundaram H, Michaels J, Durrani MJ, Wortzman MS, Nelson DB. Rheological evaluation of the physical properties of hyaluronic acid dermal fillers. *J drugs Dermatol.* 2011; 10(9): 974-80.
29. Shah S, Bellows BA, Adedipe AA, Totten JE, Backlund BH, Sajed D. Perceived barriers in the use of ultrasound in developing countries. *Crit Ultrasound J.* 2015;7(1):28.DOI: 10.1186/s13089-015-0028-2.
30. Scholten HJ, Pourtaherian A, Mihajlovic N, Korsten HHM, Bouwman RA. Improving needle tip identification during ultrasound-guided procedures in anaesthetic practice. *Anaesthesia.* 2017;72(7):889-904.DOI: 10.1111/anae.13921.