

Review Article

Sigmoid Volvulus-Current Management-Narrative review article

Abstract

Sigmoid volvulus is a common cause of intestinal obstruction in older patients and the diagnosis is made by clinical examination and imaging. Sigmoid volvulus can be divided into complicated or uncomplicated clinical presentation. Once the diagnosis of sigmoid volvulus is made, the treatment is initially endoscopic decompression followed by flatus tube insertion. This is followed by surgical intervention which is sigmoid colectomy followed by anastomosis. For complicated sigmoid volvulus, the Hartmann's procedure is the most common operation. We have conducted this review article to review the current management of sigmoid volvulus.

Keywords- "sigmoid volvulus", "endoscopic decompression", "sigmoid colectomy", "Hartmann's procedure"

Introduction

Sigmoid volvulus is defined as a condition where the sigmoid colon wraps itself around its own mesentery and causes intestinal obstruction. It accounts for intestinal obstruction in up to 50% of cases in Africa, central Asia, and south America but only 5% to 10% of cases in Europe and

the United States. It is most seen in the 4th to 8th decade of life and in males rather than females.(1,2)

The etiology is multifactorial with chronic constipation, the frequent use of laxatives, high fiber in the diet and previous laparotomy being some of the common causes. The mesosigmoid twist by more than 180 degrees which then leads to torsion and intestinal obstruction. The two mechanisms of torsion are axial mesocolic volvulus and organo-axial volvulus.(3)

The management of sigmoid volvulus can be divided into conservative treatment and surgical treatment. The conservative treatment involves sigmoidoscopy and decompression followed by flatus tube insertion. The surgical management can be divided into sigmoid colectomy followed by primary anastomosis or the Hartmann's procedure. The surgical management depends on whether the patient presents with signs of peritonitis, and it is indicated to prevent recurrence after endoscopic decompression.(4–8)

As there is no uniform consensus on the management of Sigmoid volvulus, we have conducted this review article to investigate the various treatment options. We conducted a literature review using PUBMED, Cochrane database of clinical reviews and Google scholar looking for clinical trial, observational and cohort studies, systemic reviews, and meta-analysis from 1990 to 2022. We used the following keywords, "Sigmoid volvulus", "endoscopic decompression", "Flatus tube", "Sigmoid colectomy", "Hartmann's procedure". All articles were in English language only. Further articles were obtained by manual cross referencing of the literature.

Case reports and studies with less than 10 patients and editorials were excluded. Only adult patients were included, and pediatric and pregnant patients were excluded.

UNDER PEER REVIEW

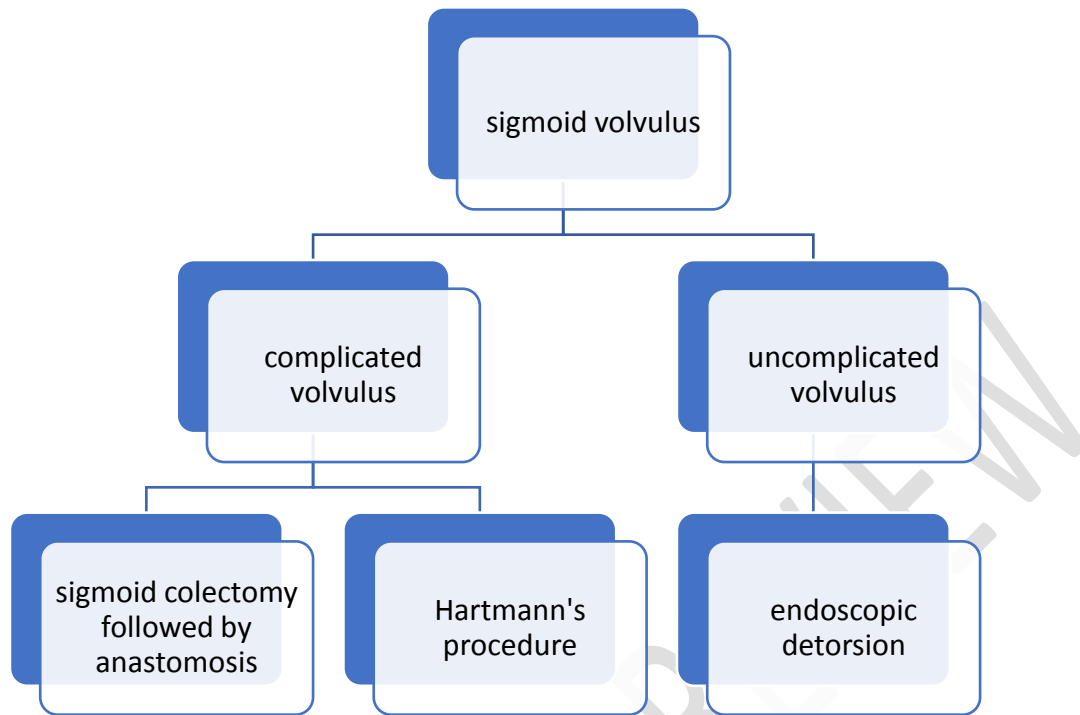


Image 1 : Flow chart on the classification and management of sigmoid volvulus

Diagnosis and imaging of sigmoid volvulus

The symptoms of sigmoid volvulus depend on the age of the patient, with the predominant symptoms being abdominal pain, vomiting and abdominal distension. In older patients' constipation is a common symptom. Abdominal x-ray is usually diagnostic with a coffee bean appearance showing a massive distended sigmoid colon and it is diagnostic in 50% to 75% of

cases. Computerized tomography and barium enema can also be used to diagnose this condition.(9)

The Coffee bean sign on abdominal x ray shows the apposition of the medial walls of the dilated loops of bowel forming the cleft of the bean and the lateral wall forming the outer wall of the bean which is seen in sigmoid volvulus. The assessment of the patient with sigmoid volvulus by using an abdominal x-ray is also good at predicting the clinical outcome. Computerized tomography is useful to exclude ischemic or necrosis of the segment of sigmoid colon and is to rule out complications like perforation.(10–12)

Among the factors that lead to sigmoid volvulus is the dolichosigmoid which is an elongated sigmoid colon with a narrow-based mesentery. Other factors include excessive bowel motion and prolonged starvation followed by excessive eating. Other factors include presence of comorbidities, the duration of the disease and presence of shock.(13–15)

Diagnosis of sigmoid volvulus can also be made with sigmoidoscopy with the classical finding of a spiral sphincter like twist of the lumen which is about 20 to 30cm from the anal verge. It has a high diagnostic value but quantitative data in the literature is lacking.(16)

An attempt was made to classify sigmoid volvulus by Atamanalp, who divided patients with sigmoid colitis into 5 categories, Class C1, patients with no risk factors, C2, patients with no shock or gangrene, but with age above 60 years and associated diseases. C3, those with shock, C4, those with sigmoid gangrene and C5, patients with both shock and sigmoid gangrene. Class 3,4 and 5 is further subdivided to subclass a and b.(17,18)

Treatment of sigmoid volvulus

A) Endoscopic decompression-This can be performed using a rigid sigmoidoscope, flexible sigmoidoscopy or colonoscopy. The scope is slowly advanced with minimal insufflation, and it detorts the colon once the torsion has been passed, following which there will be release of fluid and gas. A rectal tube is usually placed after the procedure to prevent recurrence.(19,20)

Although associated with a high recurrence rate, endoscopic decompression is still a good first line therapy for the management of sigmoid volvulus as it helps to optimize and prepare the patients for elective surgery. Sigmoidoscopic decompression is safe in the initial management of uncomplicated sigmoid volvulus.(21–26)

Several factors have been associated with influencing the outcomes of endoscopic decompression that include the absence of abdominal tenderness on examination, history of chronic use of laxatives, previous abdominal surgery, and use of opioids. (27,28)

Percutaneous endoscopic colostomy is also an alternative endoscopic treatment for patients who are frail and not fit for surgery.(29) Systemic reviews by Frank et al and Jackson et al concluded that two percutaneous endoscopic colostomy tubes must be inserted to avoid recurrence and the tubes should be left indefinitely. The drawback from this systemic review was that it was retrospective in nature and that future randomized trials may be needed to evaluate this.(30,31)

B. Surgical management

The World Society of Emergency Surgeons consensus guidelines on sigmoid colon management recommended urgent sigmoid resection for cases of failed endoscopic decompression, and the choice of either sigmoid resection followed by a colorectal anastomosis or a Hartmann's procedure will depend on the viability of the colon and the clinical status of the patient.(32)

The American Society of Colon and Rectal Surgeons guidelines on the management of sigmoid volvulus also concluded that sigmoid resection should be offered for patients who underwent endoscopic decompression to prevent recurrence. Surgical resection will include sigmoid resection with either bowel anastomosis or stoma formation. (33)

Sigmoid resection is indicated to prevent recurrence of sigmoid volvulus, and it is safe and should be considered for all cases. Surgery should be done as early as possible to prevent recurrence of symptoms.(34–36)

The retrospective study by Tan K et al on the management of sigmoid volvulus concluded that sigmoid colectomy followed by anastomosis should be offered as an elective procedure to prevent recurrence as the mortality from emergency surgery was 17.6% in this study.(37)

The current trend in the surgical management of sigmoid volvulus has been sigmoid resection followed by primary anastomosis. This will depend on whether there is presence of gangrene of the sigmoid colon, as absence of gangrene is associated with lower complication rates.(38–40)

An observational retrospective study by Lee et al on the surgical management of sigmoid volvulus concluded that in emergency cases, the Hartmann's procedure was the most common

surgical procedure and for elective cases, sigmoid resection followed by colorectal anastomosis is the most common operation. The post complication rates, and morbidity rates were higher in the emergency cases.(41)

When deciding on the surgical treatment for sigmoid volvulus, the choice of surgery will depend on the patient's general condition and the viability of the sigmoid colon. The retrospective study by Traore et al showed that a sigmoid colectomy followed by anastomosis was associated with a higher mortality than with a Hartmann's procedure. (42)

Surgical treatment for sigmoid volvulus should also be offered as early as possible to prevent recurrence and these studies showed that surgical management was associated with better survival and outcomes regardless of patient characteristics.(43–45)

For patients who present with complication from sigmoid volvulus like bowel perforation or intestinal obstruction than emergency surgery should be the treatment of choice with the Hartmann's procedure being the preferred operation of choice. The factors that affect the operative mortality were the patient's condition, state of the disease and timing of surgery.(46–48)

A retrospective study by shahmoradi et al comparing the outcomes between primary anastomosis and the Hartmann's procedure in the surgical treatment of sigmoid volvulus concluded that there was no difference in the post operative complications and mortality rates.(49)

For patients with concomitant megacolon and megarectum that present at the time of surgery, a subtotal colectomy should be performed as a primary procedure to reduce the risk of recurrence.(50)

Other surgical procedures have been attempted like mesosigmoidoplasty, where the sigmoid colon mesentery is fixed, but it is indicated in uncomplicated sigmoid volvulus, and it is not practiced as it is associated with a high recurrence rate and most case series are of low patient volume.(51)

UNDER PEER REVIEW

Table I Table of the studies showing the various treatment results of sigmoid volvulus

study	year	N=numbers	Endoscopic detorsion	Sigmoid colectomy and anastomosis	Hartmann's procedure	Study type
Agoglu et al	2005	32	7	9	16	Retrospective study
Larkin et al	2009	27	19	4	4	Retrospective study
Tan K.K et al	2010	71	53	11	7	Retrospective study
Mulugula et al	2018	131	29	78	24	Retrospective study
Lee et al	2018	74	5	46	23	Retrospective study
Tarore et al	1996-2010	417	101	149	167	Retrospective study

Conclusion

Sigmoid volvulus is diagnosed clinically, and confirmation is done by abdominal x-ray or computerized tomography. Uncomplicated sigmoid volvulus is treated initially with endoscopic decompression followed by an insertion of a flatus tube. Elective surgery should be planned to prevent recurrence and the choice of surgery is a sigmoid colectomy followed by anastomosis.

In complicated sigmoid volvulus the surgery of choice is either the Hartmann's procedure or sigmoid colectomy with bowel anastomosis, but due to contamination of signs of shock, formation of a stoma is usually done. Early diagnosis of sigmoid colitis is important as these cases can be scheduled for elective sigmoid resection, and this can prevent future attacks and limit the risk of complication.

References

1. Atamanalp SS. Sigmoid Volvulus. *Eurasian J Med* [Internet]. 2010 Dec 1;42(3):142–7. Available from: <http://www.eajm.org/text.php3?id=364>
2. Ballantyne GH, Brandner MD, Beart RW Jr, Ilstrup DM. Volvulus of the colon. Incidence and mortality. *Ann Surg*. 1985 Jul;202(1):83-92. doi: 10.1097/00000658-198507000-00014. PMID: 4015215; PMCID: PMC1250842.
3. Perrot L, Fohlen A, Alves A, Lubrano J. Management of the colonic volvulus in 2016. Vol. 153, *Journal of Visceral Surgery*. Elsevier Masson SAS; 2016. p. 183–92.

4. Madiba TE, Thomson SR. The management of sigmoid volvulus. *J R Coll Surg Edinb.* 2000 Apr;45(2):74-80. PMID: 10822915.
5. Lal SK, Morgenstern R, Vinjirayer EP, Matin A. Sigmoid Volvulus an Update. Vol. 16, *Gastrointestinal Endoscopy Clinics of North America.* 2006. p. 175–87.
6. Bhuiyan MM, Machowski ZA, Linyama BS, Modiba MC. Management of sigmoid volvulus in Polokwane-Mankweng Hospital. *S Afr J Surg.* 2005 Feb;43(1):17-9. PMID: 15887420.
7. Lyons D. Sigmoid Volvulus: A Case Series, Review of the Literature and Current Treatment. *Am J Biomed Sci Res.* 2019 Dec 9;6(4):352–7.
8. Atamanalp SS, Peksoz R. Sigmoid volvulus: Treatment options and volvulus recurrence. *Emergency Care Journal.* 2021 Dec 20;17(4).
9. Gingold D, Murrell Z. Management of colonic volvulus. *Clin Colon Rectal Surg.* 2012;25(4):236–43.
10. Jaffe T, Thompson WM. Large-bowel obstruction in the adult: Classic radiographic and CT findings, etiology, and mimics. *Radiology.* 2015 Jun 1;275(3):651–63.
11. Levsky JM, Den EI, DuBrow RA, Wolf EL, Rozenblit AM. CT findings of sigmoid volvulus. *American Journal of Roentgenology.* 2010 Jan;194(1):136–43.
12. Ishibashi R, Niikura R, Obana N, Fukuda S, Tsuboi M, Aoki T, et al. Prediction of the clinical outcomes of sigmoid volvulus by abdominal X-Ray: AXIS classification system. *Gastroenterol Res Pract.* 2018;2018.

13. Dişçi E, Atamanalp SS. Factors precipitating volvulus formation in sigmoid volvulus. *Ulusal Travma ve Acil Cerrahi Dergisi*. 2022 Mar 1;28(3):281–4.
14. Bayeh AB, Abegaz BA. The role of sigmoid colon anatomic dimensions in the development of sigmoid volvulus, North-Western Ethiopia. *PLoS One*. 2021 Dec 1;16(12 December).
15. Atamanalp SS, Disci E, Atamanalp RS. Sigmoid volvulus: Comorbidity with sigmoid gangrene. *Pak J Med Sci*. 2019;35(1):288–90.
16. Atamanalp SS, Atamanalp RS. The role of sigmoidoscopy in the diagnosis and treatment of sigmoid volvulus. *Pak J Med Sci*. 2016;32(1):244–8.
17. Atamanalp SS. Sigmoid volvulus: An update for atamanalp classification. *Pak J Med Sci*. 2020 Jul 1;36(5):1137–9.
18. Selçuk Atamanalp S, Öztürk Mahmut Başoğlu İlhan Yildirgan GM. Classification of Sigmoid Volvulus [Internet]. Vol. 38, *Turkish Journal of Medical Sciences*. 2008. Available from: <https://journals.tubitak.gov.tr/medical:https://journals.tubitak.gov.tr/medical/vol38/iss5/8>
19. Underhill J, Munding E, Hayden D. Acute Colonic Pseudo-obstruction and Volvulus: Pathophysiology, Evaluation, and Treatment. *Clin Colon Rectal Surg*. 2021 Jul 1;34(4):242–50.

20. EGPA D, M F, B N, AM C, M M, I S, et al. Adult sigmoid volvulus in West Africa: Management and outcome at principal hospital of Dakar. *International Journal of Surgery Science*. 2021 Jul 1;5(3):32–7.
21. Da Rocha MC, Capela T, Silva MJ, Ramos G, Coimbra J. Endoscopic Management of Sigmoid Volvulus in a Debilitated Population: What Relevance? *GE Port J Gastroenterol*. 2020 Apr 1;27(3):160–5.
22. Moro-Valdezate D, Martín-Arévalo J, Pla-Martí V, García-Botello S, Izquierdo-Moreno A, Pérez-Santiago L, et al. Sigmoid volvulus: outcomes of treatment and predictors of morbidity and mortality. *Langenbecks Arch Surg*. 2022 May 1;407(3):1161–71.
23. Lou Z, Yu E Da, Zhang W, Meng RG, Hao LQ, Fu CG. Appropriate treatment of acute sigmoid volvulus in the emergency setting. *World J Gastroenterol*. 2013;19(30):4979–83.
24. Firat N, Mantoglu B, Ozdemir K, Muhtaroglu A, Akin E, Celebi F, et al. Endoscopic Detorsion Results in Sigmoid Volvulus: Single-Center Experience. *Emerg Med Int*. 2020 May 13;2020:1–5.
25. oter serdar. Endoscopic treatment and outcomes of sigmoid volvulus, single center experience. *Laparoscopic Endoscopic Surgical Science*. 2022;
26. Fagan PV, Stanfield B, Nur T, Henderson N, El-Haddawi F, Kyle S. Management of acute sigmoid volvulus in a provincial centre-a 20-year experience. *NZMJ [Internet]*. 2019;12:1493. Available from: www.nzma.org.nz/journal

27. Iida T, Nakagaki S, Satoh S, Shimizu H, Kaneto H, Nakase H. Clinical outcomes of sigmoid colon volvulus: Identification of the factors associated with successful endoscopic detorsion. *Intest Res.* 2017;15(2):215–20.
28. Dahiya DS, Perisetti A, Goyal H, Inamdar S, Singh A, Garg R, et al. Endoscopic versus surgical management for colonic volvulus hospitalizations in the United States. *Clin Endosc.* 2023 May 30;56(3):340–52.
29. Khan MA, Ullah S, Beckly D, Oppong FC. Percutaneous endoscopic colostomy (PEC): an effective alternative in high risk patients with recurrent sigmoid volvulus. *J Coll Physicians Surg Pak.* 2013 Nov;23(10):806-8. PMID: 24169390.
30. Frank L, Moran A, Beaton C. Use of percutaneous endoscopic colostomy (PEC) to treat sigmoid volvulus: a systematic review. *Endosc Int Open.* 2016 Jun 29;04(07):E737–41.
31. Jackson S, Hamed MO, Shabbir J. Management of sigmoid volvulus using percutaneous endoscopic colostomy. Vol. 102, *Annals of the Royal College of Surgeons of England.* Royal College of Surgeons of England; 2020. p. 654–62.
32. Tian BWCA, Vigutto G, Tan E, van Goor H, Bendinelli C, Abu-Zidan F, et al. WSES consensus guidelines on sigmoid volvulus management. Vol. 18, *World journal of emergency surgery : WJES.* NLM (Medline); 2023. p. 34.
33. Vogel JD, Feingold DL, Stewart DB, Turner JS, Boutros M, Chun J, et al. Clinical practice guidelines for colon volvulus and acute colonic pseudo-obstruction. Vol. 59, *Diseases of the Colon and Rectum.* Lippincott Williams and Wilkins; 2016. p. 589–600.

34. Hardy NP, McEntee PD, McCormick PH, Mehigan BJ, Larkin JO. Sigmoid volvulus: definitive surgery is safe and should be considered in all instances. *Ir J Med Sci.* 2022 Jun 1;191(3):1291–5.
35. Ifversen AKW, Kjaer DW. More patients should undergo surgery after sigmoid volvulus. *World J Gastroenterol.* 2014 Dec 28;20(48):18384–9.
36. Suleyman O, Kessaf AA, Ayhan KM. Sigmoid volvulus: long-term surgical outcomes and review of the literature. *S Afr J Surg.* 2012 Feb 14;50(1):9-15. PMID: 22353314.
37. Tan KK, Chong CS, Sim R. Management of acute sigmoid volvulus: An institution's experience over 9 years. *World J Surg.* 2010 Aug;34(8):1943–8.
38. Safioleas M, Chatziconstantinou C, Felekouras E, Stamatakos M, Papaconstantinou I, Smirnis A, et al. Clinical considerations and therapeutic strategy for sigmoid volvulus in the elderly: A study of 33 cases. *World J Gastroenterol [Internet].* 2007;13(6):921–4. Available from: www.wjgnet.com
39. Mulugeta GA, Awlachev S. Retrospective study on pattern and outcome of management of sigmoid volvulus at district hospital in Ethiopia. *BMC Surg.* 2019 Aug 9;19(1).
40. Heis HA, Bani-Hani KE, Rabadi DK, Elheis MA, Bani-Hani BK, Mazahreh TS, et al. Sigmoid volvulus in the Middle East. *World J Surg.* 2008 Mar;32(3):459–64.
41. Lee K, Oh HK, Cho JR, Kim M, Kim DW, Kang SB, et al. Surgical management of sigmoid volvulus: A multicenter observational study. *Ann Coloproctol.* 2021 Dec 31;36(6):403–8.

42. Traoré D, Sanogo ZZ, Bengaly B, Sissoko F, Coulibaly B, Togola B, et al. Acute sigmoid volvulus: Results of surgical treatment in the teaching hospitals of Bamako. *J Chir Visc.* 2014 Apr 1;151(2):104–8.
43. Slack Z, Shams M, Ahmad R, Ali R, Antunes D, Dey A, et al. Prognostic factors in the decision-making process for sigmoid volvulus: results of a single-centre retrospective cohort study. *BMC Surg.* 2022 Dec 1;22(1).
44. Labkin JO, Thekiso TB, Waldron R, Barby K, Eustace PW. Recurrent sigmoid volvulus - Early resection may obviate later emergency surgery and reduce morbidity and mortality. *Ann R Coll Surg Engl.* 2009 Apr;91(3):205–9.
45. Ağaoğlu N, Yücel Y, Türkyılmaz S. Surgical treatment of the sigmoid volvulus. *Acta Chir Belg.* 2005;105(4):365–8.
46. Cirocchi R, Farinella E, La Mura F, Morelli U, Trastulli S, Milani D, et al. The sigmoid volvulus: Surgical timing and mortality for different clinical types. *World Journal of Emergency Surgery.* 2010 Jan 13;5(1).
47. Samuel JC, Akinkuotu A, Msiska N, Cairns BA, Muyco AP, Charles AG. Re-examining treatment strategies for sigmoid volvulus: An analysis of treatment and outcomes in Lilongwe, Malawi.
48. Barbieux J, Plumereau F, Hamy A. Current indications for the Hartmann procedure. *J Visc Surg.* 2016 Feb;153(1):31–8.

49. Kazem shahmoradi M, khoshdani farahani P, Sharifian M. Evaluating outcomes of primary anastomosis versus Hartmann's procedure in sigmoid volvulus: A retrospective-cohort study. *Annals of Medicine and Surgery*. 2021 Feb 1;62:160–3.
50. Chung YFA, Eu KW, Nyam DCNK, Leong AFPK, Ho YH, Seow-Choen F. Minimizing recurrence after sigmoid volvulus. Vol. 86, *British Journal of Surgery*. 1998.
51. Campos-Badillo JA, Rojas-Huizar JÁ, Luis Vargas-Ávila A, Chávez-Acevedo S, Denisse López-Olivera K. CLINICAL CASE Mesosigmoidoplasty: an alternative technique for sigmoid volvulus in critically ill patients [Internet]. Vol. 41, *Cirujano General*. 2019. Available from: www.medigraphic.com/cirujanogeneralwww.medigraphic.org.mx