

**LOW GRADE APPENDICEAL NEOPLASM**

**ABSTRACT**

Mucinous tumors of appendix are not frankly malignant but, if ruptured can result in intraperitoneal spread and development of pseudomyxoma peritonei [PMP]. At the lower end of spectrum are Low grade mucinous neoplasm [LAMN], which have been historically called mucoceles of appendix and accounts for less than 0.3% of appendectomy findings. We present the case of 33 years old male who had complaints of sudden onset of pain abdomen for 5 days. Computer tomography was done with evidence of dilatation of appendix with cystic lesion of 50\*43mm. The patient underwent laparotomy with right hemicolectomy. The histology report showed a low grade appendiceal neoplasm. Therefore LAMN should be considered as, one of the differentials in patients presenting with acute abdomen and right iliac fossa mass.

**Keywords-** Acute appendicitis, Low grade appendiceal neoplasms, Rare cancer, Pseudomyxoma peritonei.

**INTRODUCTION**

Appendiceal mucinous neoplasms are rare [1-3]. These lesions are extraordinarily variable and can range from non-neoplastic to neoplastic and tends to occur in the 5<sup>th</sup> to 6<sup>th</sup> decade of life and are more common in females [4]. They arise from the luminal mucosa of the appendix and produce thick, tenacious mucus. LAMNs always lack overt infiltrative epithelial invasion of the appendix. These lesions are pathologically flat or villous with associated epithelial mucin. The serosal surface may appear completely normal. Mucin continues to fill the lumen and eventually the appendix may rupture [5]. This can lead to peritoneal seeding of mucin –producing cells leading mucinous ascites, a condition known as pseudomyxoma peritonei (PMP) [6,7]. Nodal and hematogenous metastases are uncommon. LAMNs are usually discovered incidentally during radiologic or endoscopic evaluation for unrelated complaints or in the pathologic specimen of an appendectomy.

Patients are often asymptomatic or have nonspecific symptoms [8]. The most frequent is right lower quadrant pain, which can mimic as acute appendicitis. An abdominal mass is occasionally palpable. Less frequently patients can present with intermittent colicky pain and gastrointestinal bleeding associated with intussusception of mucocele, intestinal obstruction, genitourinary symptoms due to right ureter obstruction; rarely, acute abdomen from mucocele rupture and sepsis. If the tumor has ruptured, drop ovarian metastasis is common and patient may present with large ovarian tumors, which are frequently confused for primary tumor. LAMNs previously known as appendiceal mucinous cystadenomas, are rare mucinous tumors of appendix showing low grade cytological atypia. We present the case of 33 old male and was found to have LAMN presenting as acute appendicitis, treated by right hemicolectomy.

### **Presentation of case**

A 33 years old male presented with complaint of pain abdomen since five days. Initially pain was in the epigastric region and then the pain was localized to right lower quadrant. It was associated with nausea, vomiting and fever which was documented to be 101 F. It was not associated with altered bowel and bladder habits. History of similar episode of pain was present 2 years back but patient did not take any treatment and relieved by own.

On examination patient was conscious cooperative and oriented to time, place and person. His vitals were blood pressure 122/80mmHg, pulse -112/min, oxygen saturation:98%, temperature :38C. On examination of abdomen it was non distended, guarding to palpation in right lower quadrant, positive McBurney sign, no lump palpable and decreased bowel sounds. The blood tests had the presence of Neutrophilia [81.1%] and CRP of 50mg/L. Abdominal ultrasonography was showing a well defined heterogeneously hypoechoic collection of 5.4\*4.4\*5.5cm with internal echogenic content in right iliac fossa and increased echogenicity of surrounding peritoneal fat. Computer tomography was suggestive of dilated appendix with hypodense cystic lesion of size 50\*43mm with heterogenous contents and calcification in the lumen wall. [Figure.1]

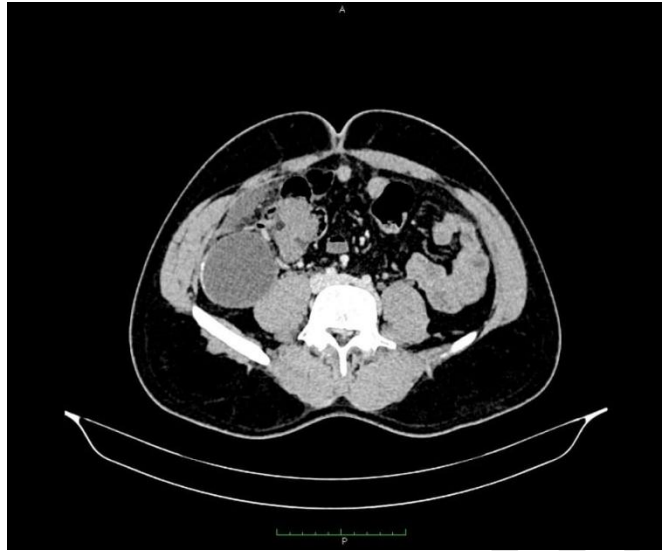


Figure.1 Heterogenous contents and calcification in the lumen wall

Patient underwent exploratory laparotomy with right hemicolectomy. Grossly there was a hard to cystic mass of 5\*5 cm involving caecum, appendix and distal ileum. Histology of tissue specimen [Figure.2] indicated LAMN with columnar epithelial cells with foci of mucin and showing low grade dysplasia. There were five lymph nodes having reactive lymphoid hyperplasia.

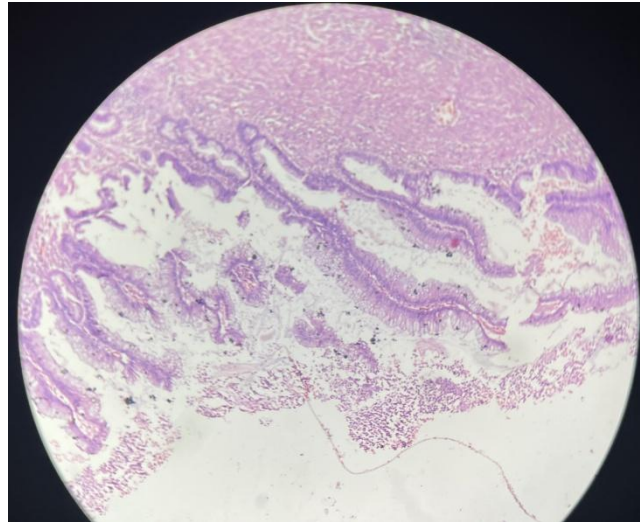


Figure.2 Histology of tissue specimen

The patient discharged in satisfactory condition and was seen in follow up for 2 years and doing well.

### **Discussion**

Appendiceal mucinous lesions are heterogenous group of non- neoplastic lesions (mucocele) and neoplastic lesions (serrated polyps, hyperplastic polyps, LAMN, HAMN, and mucinous adenocarcinomas) [10]. Presently LAMNs are staged according to the 8th edition of the American Joint Committee on Cancer Staging Manual. The staging depends on the depth of invasion through appendiceal wall. Histologically, a villous or flat proliferation of mucinous epithelium with low- grade atypia is hallmark of LAMNs[14]. Even though they don't have any malignant features but these are precursor lesions to pseudomyxoma peritonei. The prominent mucin production increases intraluminal pressure, which may penetrate into or through the appendix wall, subsequently disseminate to the peritoneal cavity, and cause mucinous ascites ultimately. Bell et al. conclude that LAMNs are indolent neoplasms when confined to the appendix, in this 117 case series only 1 case led to pseudomyxoma[15].

Patients are often asymptomatic or have nonspecific symptoms and the diagnosis is made incidentally in the course of another examination.

The gold standard preoperative diagnostic imaging test is computed tomography CT scan. The finding of calcification in the wall is very much suggestive of mucinous neoplasia but it is found in less than 50% of cases [11,12]. In addition CT scan also allow us to evaluate the extent of disease and to diagnose complications including inflammation, invagination, torsion, compression of ureter and the presence of peritoneal disease. Kehagias et al documented on CT scans of a LAMN presented as acute appendicitis a cystic mass with 83 mm diameter that contained a partly curvilinear calcification similar to our case [11].

The measurement of tumor markers (CEA, CA19.9, CA125) may be useful. Carmignani et al found that 67% of patients have elevated markers [13]. These markers are useful in terms of prognosis because elevated levels at the time of appendectomy could indicate an increase risk of recurrence. In our patient tumors markers were normal.

The definitive management of LAMNs is the surgical approach, but there are discrepancies in the extent of surgical resection. We perform right hemicolectomy in this case, as the ileocaecal valve was not patent. The patient is under close follow up for 2 years and is asymptomatic to date. Appendectomy alone is curative for benign and grossly intact mucinous neoplasm. Right hemicolectomy is only recommended when there is risk of ileocaecal valve injury due to traumatic manipulation or protusion of tumor towards the caecal lumen [12].

### **Conclusion**

Mucinous appendiceal neoplasms can present with a variety of clinical manifestations. Extreme care is taken to prevent the rupture of appendix during manipulation to avoid iatrogenic dissemination of mucin producing cells. Accurate histopathological evaluation is essential to assess malignancy risk, metastasis and outcome of patient presenting with acute appendicitis. Maintaining a high index of suspicion for the possibility of appendiceal neoplasm is crucial in deciding appropriate management modality. Further studies are needed to determine the management and monitoring strategies for LAMNs.

### **Declaration of patient consent**

The authors certify that they have obtained all appropriate patient consent forms. In the form the patient has given his consent for his clinical information to be reported in journal.

## REFERENCES

1. Fournier K, Rafeeq S, Taggart M, et al. Low grade Appendiceal Mucinous Neoplasm of Uncertain Malignant Potential [LAMN-UMP]:Prognostic factors and Implications for Treatment and Follow-up. *Ann Surg Oncol* 2017;24:187-93.
2. Klag T, Wehkamp J, Bosmuller H, et al. Low-grade appendiceal mucinous neoplasm [LAMN]- 3 yaers endoscopic follow up underlines benign course of LAMN type 1. *Z Gastroenterol* 2017;55:149-52
3. Rymer B, Forsythe RO, Husada G. Mucocele and ncinous tumours of the appendix :a review of the literature. *Int J Surg* 2015;18:132-5.
4. Pai RK, Beck AH, Norton JA et al. Appendiceal mucinous neoplasms:clinicopathological study of 116 cases with analysis of factors predicting recurrence. *Am J Surg Pathol* 2009;33:1425-1439.
5. Higa E, Rosai J, Pizzimbono CA et al. Mucosal hyperplasia, mucinous cystadenoma and mucinous cystadenocarcinoma of the appendix. A re-evaluation of appendiceal mucocele. *Cancer* 1973;32:1525-1541
6. Misdraji J, Yantiss RK, Graeme –Cook F Met al. Appendiceal mucinous neoplasms: a clinicopathological analysis of 107 cases. *Am J Surg Pathol* 2003;27:1089-1103.
7. Umetsu SE, Shafizadeh N, Kakar S. Grading and staging mucinous neoplasms of the appendix : a case seires and review of the literature. *Hum Pathol* 2017;69:81-9.
8. Agrusa A, Romano G, Galia M, Cucinella G, Sorce V, et al. Appendiceal mucinous neoplasm : an uncertain nosological entity. REort of a case. *G Chir.* 2016;37:86-9.
9. Dixit A, Robertson JH, Mudan SS, Akle C. Appendiceal muucoceles and pseudomycoma peritonei. *World J Gastroenterol.* 2007;13[16]; 2381-4.

10. N.J. Carr, T.D. Cecil, F. Mohamed et al. A consensus for classification and pathologic reporting of pseudomyxoma peritonei and associated appendiceal neoplasia. *Am J Surg Pathol* 2016;40:14-26.
11. Kehagias I, Zygomalas A, Markopoulos G, et al. Diagnosis and treatment of mucinous appendiceal neoplasm presented as acute appendicitis. *Case Rep Oncol Med* 2016;2016:2161952.
12. Zhou ML, Yan FH, Xu PJ et al. Mucinous cystadenoma of appendix: CT findings. *Chin Med J* 2006;119:1300-3.
13. Carmignani CP, Hampton R, Sugarbaker CE, et al. Utility of CEA and CA 19.9 tumor markers in diagnosis and prognostic assessment of mucinous epithelial cancers of appendix. *J Surg Oncol* 2004;87:162-6.
14. Mohanty AK, Anand G, Nemeč J, Alnajjar A, Albarrak J. Low grade appendiceal mucinous neoplasm- rare neoplasm ; A case report. *J Cancer Prev Curr Res* 2018;9:77-9.
15. Bell PD, Huber AR, Drage MG, Barron SL, et al. Clinicopathologic features of low -grade appendiceal mucinous neoplasm : a single institution experience of 117 cases. *Am J Surg Pathol*. 2020;44[11]:1549-55.