

E-Cadherin expression as a cell marker in benign and malignant breast lesions

Abstract

Background: Breast cancer continues to be a major cause of morbidity and mortality throughout the world. The behaviour of breast cancer varies widely. Several parameters have been investigated to predict the prognosis in breast cancer. But still there is no single parameter that can predict prognosis in an individual patient. Among the novel prognostic markers is E-cadherin; a calcium-dependent epithelial cell adhesion molecule. Its loss has been associated with metastases, thereby providing evidence for its role as an invasion suppressor. This study was conducted to evaluate the expression of E-cadherin as epithelial cell marker in the differential diagnosis of benign and malignant breast lesions and to evaluate its role as a diagnostic bio marker in breast cancer.

Methods: This prospective study was carried out from November 2020 to November 2022 in the Department of Surgery, at Jawaharlal Nehru Medical College, Aligarh, India. The study was conducted on 117 patients presenting with breast lesions. A detailed history, complete physical examination and preliminary investigations were done. Histopathological examination one on formalin fixed and paraffin embedded tissue sections of breast lesion. Immunostains for E-cadherin were employed on cases. The data was collected and analyzed using SPSS 2020.

Results: Most of the patients were below 30 years of age (36.7%) and the mean age was 38.1 ± 16.9 years. 54 patients (46.4%) were benign and 63 patients (53.6%) were malignant. Out of a total of 63 malignant breast lesions, Infiltrating ductal carcinoma Not otherwise specified (IDC NOS) was most frequent, comprising 34 cases (53.9%). We stained cases of carcinoma breast for E-cadherin. Out of 15 cases of Grade 1 IDC NOS, 11 (73.3%) showed 3+ proportion score, 3 (20.0%) cases showed 2+ score, whereas 1 (6.6%) case showed 1+ score. Out of 12 cases of Grade 2 IDC NOS, 6 (50.0%) showed 3+ and 5 (41.6%) showed 2+ proportion score and 1 case (8.3%)

showing 1+ score. Out of 7 cases of Grade 3 IDC NOS, 6 (85.7%) cases showed 2+ proportion score and 1 case (14.2%) showed 1+, none showed 3+ score. A statistically significant finding ($p=0.0059$) was seen between grade and E-cadherin score. A statistically significant ($p=0.0169$) between E-cadherin scoring on benign and malignant cases overall implying stronger expression of E-cadherin in benign lesions as compared to malignant ones.

Conclusion: It is concluded that expression of E-Cadherin is associated with benign or malignant nature of breast lesion, with expression stronger in benign. It has a prognostic value in IDC grading.

Key words: E-cadherin, Cancer, breast, benign, IDC NOS, grading.

Introduction

Breast cancer continues to be a major cause of morbidity and mortality throughout the world. The behavior of breast cancer varies widely. Several parameters have been investigated to predict the prognosis in breast cancer. But still there is no single parameter that can predict prognosis in an individual patient. Among the novel prognostic markers is E-cadherin; and a calcium-dependent epithelial cell adhesion molecule [1]. Its loss has been associated with metastases, thereby providing evidence for its role as an invasion suppressor. Breast cancer is the second most common cancer in the world. By far, it is the most frequent cancer among women with an estimated 2.26 million new cancer cases diagnosed in 2020 comprising of 24.5% of all cancers [GLOBOCAN 2020 (International Agency for Research on Cancer)] [2]. Breast cancer ranks fifth in mortality amongst all cancers. India is moving through a period of dramatic socio economic turnaround. Malignancies are the second most common cause of deaths in India after cardiovascular diseases with a rise in incidence of 0.5%-2% yearly in all age groups but more in younger groups (<45) [3]. Cervical cancers have been leading the way, but breast carcinoma has emerged as the most common cancer diagnosed in Urban India constituting >30% of all cancers in urban females with westernized lifestyle and change in the reproductive behaviour being the main culprit. The low survival rates in less developed countries

can be explained mainly by the lack of early detection programmes, resulting in a high proportion of women presenting with late-stage disease, as well as by the lack of adequate diagnosis and treatment facilities. The process of cancer invasion and metastasis consists of a complex series of sequential steps, involving specific tumor cells and host properties [4]. Detachment of tumor cells from the primary lesion is assumed to be the initial and important step in the metastatic process [5]. Their detachment is regulated by the property of tumor cell called adhesiveness. However, the molecular basis of the mutual adhesiveness of cancer cells has not been clarified in vivo, and it is difficult to estimate the actual strength of intercellular connection from the expression of a single adhesive molecule [6]. Recently the existence of abnormal E-Cadherin expression in human cancerous tissues was demonstrated and a significant relationship was found between E-cadherin expression and histological grade or invasiveness in gastric cancer [7]. Proper histopathologic categorization of breast carcinomas has prognostic implications. The majority of invasive lobular carcinomas (IC) have shown a complete loss of E-cadherin expression [8]. The loss of E-cadherin is from the outset, i.e., in the pre-invasive stage of lobular carcinoma in situ (CIS). E-cadherin loss explains the histopathologic appearance of LCIS including a diffuse growth pattern of this non-gland-forming tumor with discohesive tumor cells [9]. Keeping in mind the prognostic factors in breast cancer, this study was carried out to diagnose and grade cases of breast cancer and to evaluate their relationship to E-cadherin expression.

Methodology

The study was an observational, prospective study carried out from November 2020 to November 2022 in Department of Surgery and Pathology at Jawaharlal Nehru Medical College, Aligarh, India. The study was conducted on 117 patients presenting with breast lesions. A detailed history, complete physical examination and preliminary investigations were done. Histopathological examination one on formalin fixed and paraffin embedded tissue sections of breast lesion. Immunostains E-

cadherin were employed on cases. The data was collected and analysed using SPSS 2020.

INCLUSION CRITERIA:

- Patients giving well written informed consent for the study
- Patients with 16 years or more age
- Patients with breast lesions
-
-

A detailed history, including age of presentation, duration of disease, age at menarche, age at menopause, duration of breast feeding, any first degree relative having positive history for breast cancer, intake of Oral Contraceptive Pills /Hormone Replacement Therapy; complete physical examination and preliminary investigations were recorded in each case. Consent was taken for surgical intervention. Specimen then sent for histopathological examination.

Nottingham modification of the bloom Richardson system was used for grading of malignant lesions.

Feature	Score
Tubule formation	
Majority of tumour showing tubule formation (>75%)	1
Moderate degree of tubule formation (10-75%)	2
Little or none (< 10%)	3
Nuclear pleomorphism	
Small, regular and uniform	1
Moderate increase in size and variability	2
Marked variation	3
Mitotic counts/ HPF (Field diameter 0.44 mm/ field area 0.152 mm ²)	

0-5	1
6-10	2
>11	3

The scores were added to calculate the final grade:-

3-5: GRADE 1 (Well differentiated or low grade).

6-7: GRADE 2 (Moderately differentiated or intermediate grade).

8-9: GRADE 3 (Poorly differentiated or high grade).

Immunohistochemistry was done for E-Cadherin.

E-cadherin scoring: 4-point scale

a) Scoring of Intensity

0 = Negative

1+ = Weak and heterogeneous

2+= Mild or weak and homogeneous

3+= Moderate or strong and heterogeneous

4+= Intense or strong and homogeneous

RESULT-

Negative score= 0, 1+, 2+

Positive score= 3+, 4+

b) Scoring of proportion was calculated on positive percentage of cells, showing membrane

expression from 0 - 3:

0 - complete absence or negative expression

1+=<10%

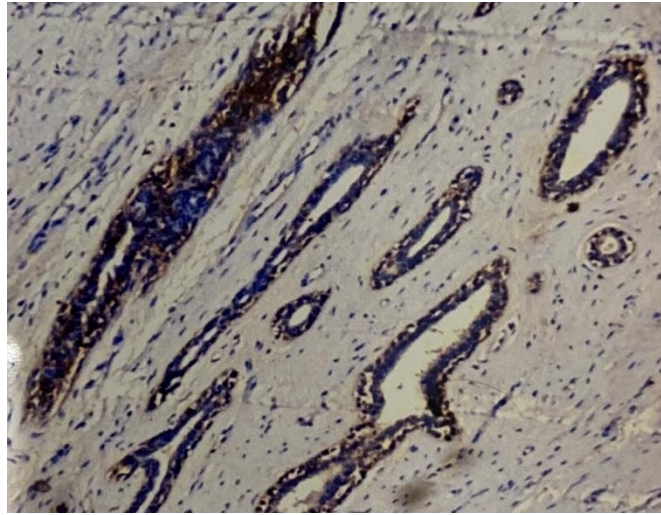
2+ = 10-50%

3+=> 50%

RESULT -

Negative score- 0

Positive score= 1+, 2+, 3+



UNDER PEER REVIEW

Figure 1. Fibroadenoma showing breast ducts with moderate E-cadherin expression

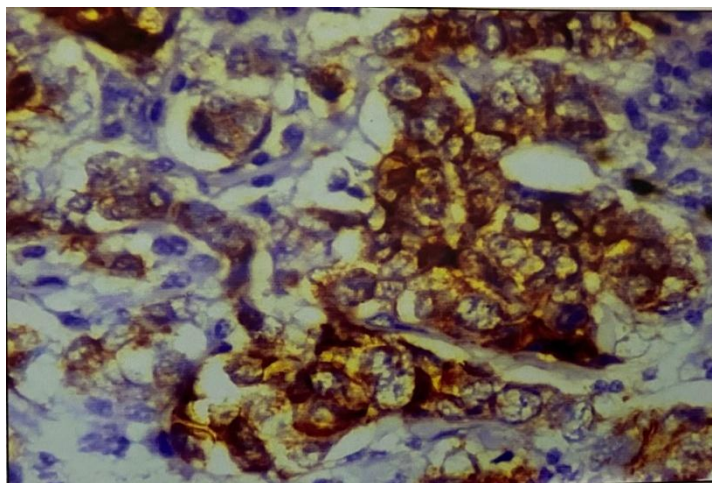


Figure 2. IDC Grade 3 showing moderately positive duct cells for E-cadherin

Statistical Analysis:

The data was collected and analysed using SPSS 2020.
Fischer exact probability test was applied on data.
P value of:-
< 0.01= highly significant
0.01 to 0.05 = significant
> 0.05= not significant

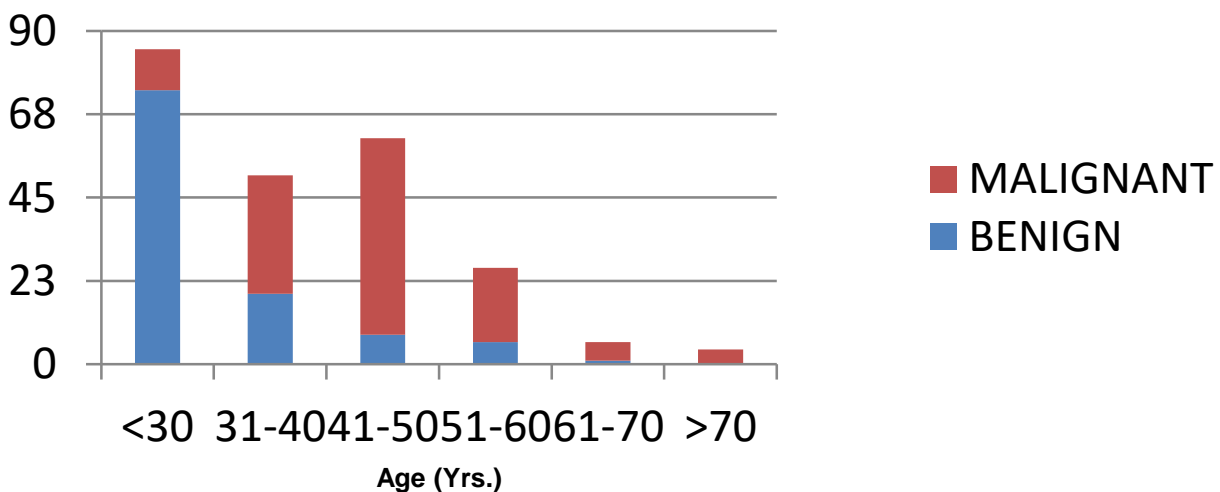
Observations and results

UNDER PEER REVIEW

Epidemiological characteristics-

Age distribution :

Figure 3. Graphical distribution of Malignancy in different age groups.



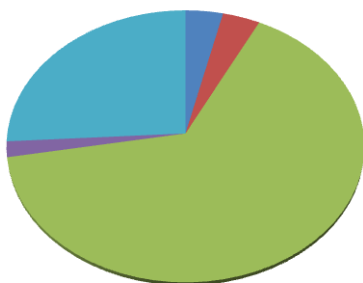
The demographic characteristics of the study population showed mean age of 38.1±16.9years. There were more number of participants (36.7%) within the <30years age group and least number of cases (1.7%) beyond 70 years.

1. Benign histological types

2. Malignant histological types

UNDER PEER REVIEW
**DISTRIBUTION OF BENIGN CASES
ACCORDING TO HISTOLOGICAL TYPES**

- CHRONIC MASTITIS
- FIBROCYSTIC DISEASE
- FIBROADENOMA
- BENIGN PHYLLOIDS
- GYNAECOMATIA



DISTRIBUTION OF MALIGNANT BREAST LESIONS ACCORDING TO HISTOLOGICAL TYPES

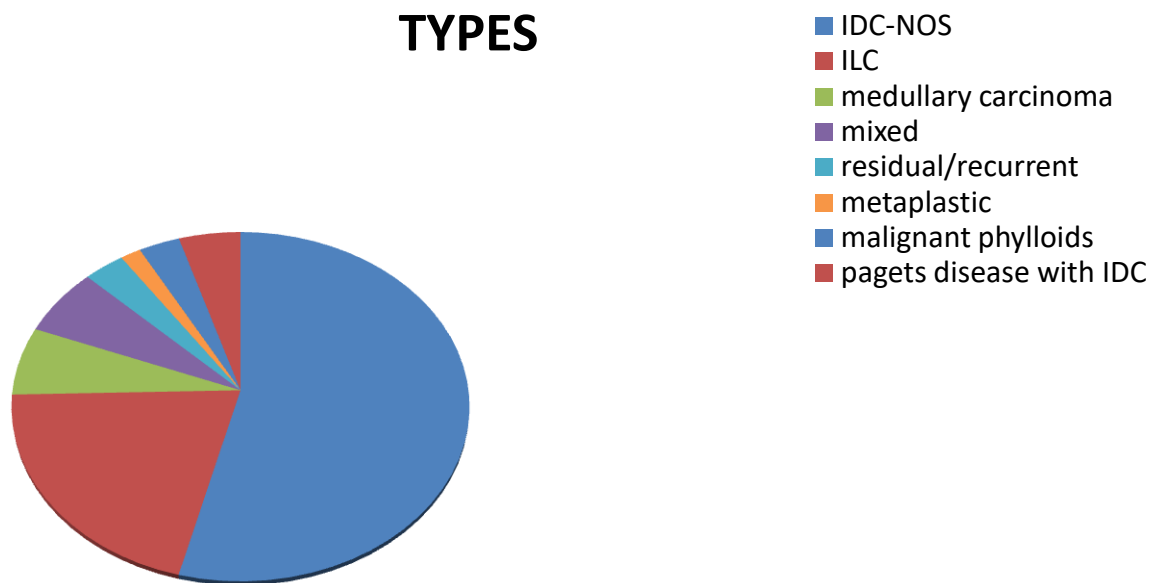


Figure 4. DISTRIBUTION OF MALIGNANT BREAST LESIONS ACCORDING TO HISTOLOGICAL TYPES

UNDER PEER REVIEW

3. Grading of malignant lesions

Histological grading was done according to Nottingham modification of the bloom-richardson system(1982).

Majority cases 26(42.0%) were grade 2, followed by 24(37.4%) grade 1 and 13 cases (20.6%) of grade 3.

4. E-cadherin expression in benign cases:

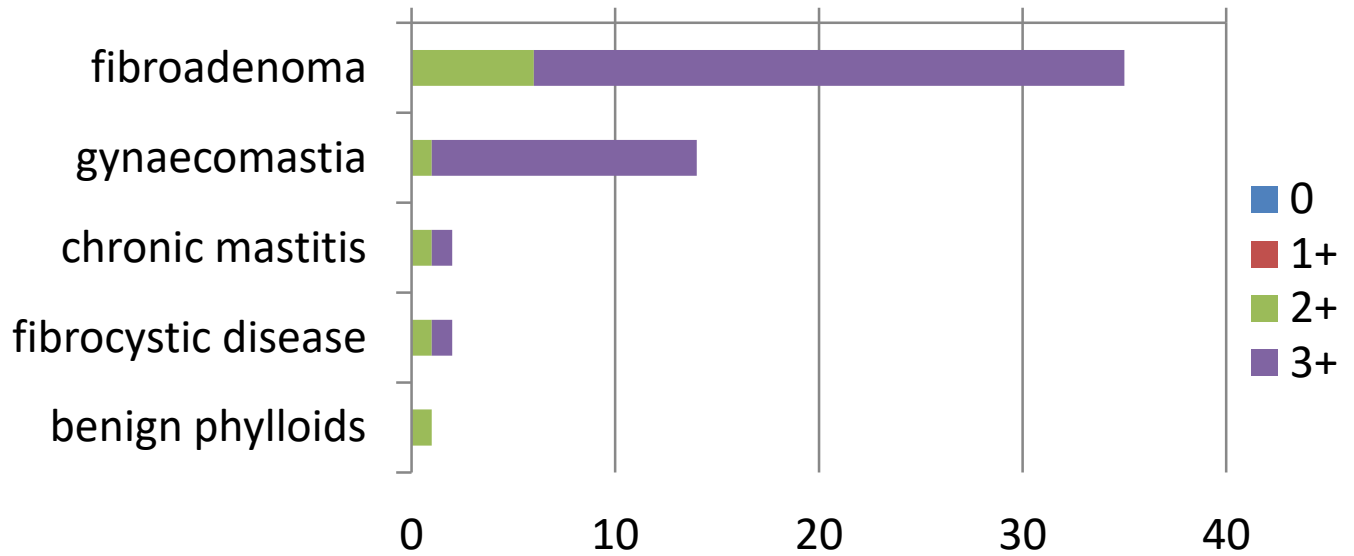


Figure 5. Benign lesions distribution and their E-cadherin expression

29 cases of fibroadenoma showed 3+ E-cadherin positivity and 6 cases of fibroadenoma showed 2+ positivity. 13 cases of gynaecomastia showed 3+ positivity and 1 case showed 2+. 1 case of chronic mastitis showed 3+ positivity and 1 case showed 2+. 1 case of fibrocystic disease showed 3+ positivity and 1 case showed 2+. 1 case of benign phyllodes showed 2+ positivity. None of the benign lesion showed 1+ positivity.

E-cadherin expression showed strong and homogeneous membranous positivity in all the benign lesions.

5. E-Catherine expression in malignant cases:

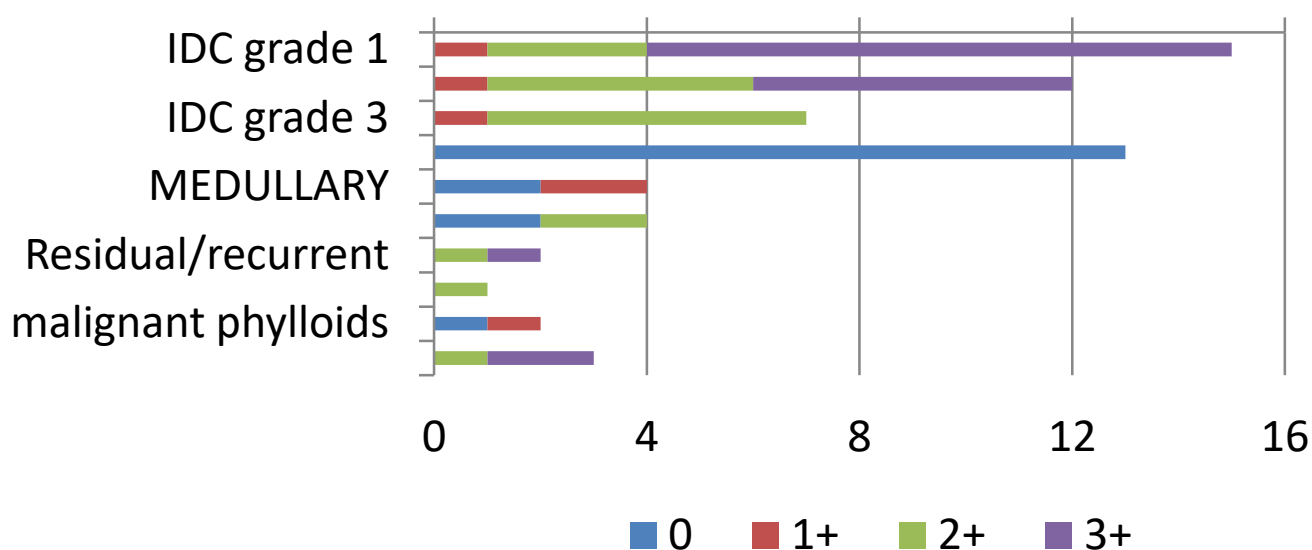


Figure 6. Malignant lesions distribution and their E-cadherin expression

As presented in the figure 6, out of 15 cases of Grade 1 IDC NOS, 11 showed 3+ proportion score, 3 cases showed 2+ score, whereas 1 case showed 1+ score. Out of 12 cases of Grade 2 IDC NOS, 6 showed 3+ and 5 showed 2+ proportion score and 1 case showing 1+ score. Out of 7 cases of Grade 3 IDC NOS, 6 cases showed 2+ proportion score and 1 case showed 1+, none showed 3+ score. Out of 13 cases of invasive lobular carcinoma ILC, none showed E-cadherin expression. Out of 4 cases of medullary carcinoma, 2 cases showed 1+ positivity and 2 showed 0 proportion score. 2 cases of mixed carcinoma showed 1+ and 2 cases showed 0 proportion score. 1 case of recurrent/residual carcinoma showed 3+ and 1 case showed 2+ proportion score. 1 case of metastatic carcinoma showed 2+ positivity for E-cadherin. 1 case of malignant phyllodes showed 1+ and 1 case showed 0 proportion score. 2 cases of pagets with IDC showed 3+ proportion score and 1 case showed 2+ positivity.

Infiltrating ductal carcinoma showed significant association between grade and expression of E-cadherin. On applying Fischer exact probability test between grade and E-Cadherin score, p value was **0.0059** which was statistically significant.

On applying Fischer exact test on E-cadherin scoring on benign and malignant cases overall, p value of **0.0169** was found, which was statistically significant. It implies expression of E-cadherin in benign lesions stronger as compared to malignant ones.

Discussion

Out of a total of 63 malignant breast lesions, Infiltrating ductal carcinoma Not otherwise specified (IDC NOS) was most frequent, comprising 34 cases (53.9%). We stained cases of carcinoma breast for E-cadherin. Out of 15 cases of Grade 1 IDC NOS, 11 (73.3%) showed 3+ proportion score, 3 (20.0%) cases showed 2+ score, whereas 1(6.6%) case showed 1+ score. Out of 12 cases of Grade 2 IDC NOS, 6 (50.0%) showed 3+ and 5 (41.6%) showed 2+ proportion score and 1 case (8.3%) showing 1+ score. Out of 7 cases of Grade 3 IDC NOS, 6 (85.7%) cases showed 2+ proportion score and 1 case (14.2%) showed 1+, none showed 3+ score. A statistically significant finding ($p=0.0059$) was seen between grade and E-cadherin score in our study which is consistent with studies of Qureshi HS, 2006 [10]. A statistically significant ($p=0.0169$) between E-cadherin scoring on benign and malignant cases overall implying stronger expression of E-cadherin in benign lesions as compared to malignant ones. These findings were consistent with Suciú C et al, 2008 [11].

Conclusion

It is concluded that expression of E-Cadherin is associated with benign or malignant nature of breast lesion, with expression stronger in benign. It has a prognostic value in IDC grading.

Ethical Approval:

As per international standard or university standard written ethical approval has been collected and preserved by the author(s).

Consent

As per international standard or university standard, patient(s) written consent has been collected and preserved by the author(s).

Abbreviations

IDC- Infiltrating ductal carcinoma

IDC-NOS - Infiltrating ductal carcinoma Not otherwise specified

ILC - Infiltrating lobular carcinoma

LCIS - Lobular carcinoma in situ

References

1. Ricciardi GR, Adamo B, Ieni A, Licata L, Cardia R, Ferraro G, Franchina T, Tuccari G, Adamo V. Androgen Receptor (AR), E-Cadherin, and Ki-67 as Emerging Targets and Novel Prognostic Markers in Triple-Negative Breast Cancer (TNBC) Patients. *PLoS One*. 2015 Jun 3;10(6):e0128368.

2. Deo, S.V.S., Sharma, J. & Kumar, S. GLOBOCAN 2020 Report on Global Cancer Burden: Challenges and Opportunities for Surgical Oncologists. *Ann Surg Oncol* **29**, 6497–6500 (2022).

3. Murthy NS, Agarwal UK, Chaudhary K, Saxena S. A study on time trends in incidence of breast cancer-Indian scenario. *European Journal of Cancer Care* 2007;16(2): 185-186.

4. Nicolson GL. Cancer metastasis: tumor cell and host organ properties important in metastasis to specific secondary sites. *Biochimica et biophysica Acta* 1988; 948:175-224.

4. Barresi V. Colorectal Cancer: From Pathophysiology to Novel Therapeutic Approaches. *Biomedicines*. 2021 Dec 8;9(12):1858.

5. Coman DR. Adhesiveness and stickiness: two independent properties of the cell surface,

Cancer Res 1961; 21 (1): 1436-1438.

6. Oka HI, Shiozaki H, Kobayashi K, Inoue M, Tahara H, Kobayashi T et al.

Expression of E-Cadherin Cell Adhesion Molecules in Human Breast Cancer Tissues and Its Relationship to Metastasis. Cancer Res 1993; 53(1) 1696-1701.

7. Kurata A, Yamada M, Ohno SI, Inoue S, Hashimoto H, Fujita K, Takanashi M,

Kuroda M. Expression level of microRNA-200c is associated with cell morphology in vitro and histological differentiation through regulation of ZEB1/2 and E-cadherin in gastric carcinoma. Oncol Rep. 2018 Jan;39(1):91-100.

8. McCart Reed AE, Kutasovic JR, Nones K, Saunus JM, Da Silva L, Newell F,

Kazakoff S, Melville L, Jayanthan J, Vargas AC, Reid LE, Beesley J, Chen XQ, Patch AM, Clouston D, Porter A, Evans E, Pearson JV, Chenevix-Trench G, Cummings MC, Waddell N, Lakhani SR, Simpson PT. Mixed ductal-lobular carcinomas: evidence for progression from ductal to lobular morphology. J Pathol. 2018 Apr;244(4):460-468.

9. Singhai R, Patil VW, Jaiswal SR, Patil SD, Tayade MB, Patil AV. E-Cadherin as a diagnostic biomarker in breast cancer. N Am J Med Sci. 2011 May;3(5):227-33.

10. Qureshi HS, Linden MD, Divine G and Raju UB. E-cadherin status in breast cancer correlates with histologic type but does not correlate with established prognostic parameters, Am J Clin Pathol 2006; 125(3): 377-385.

11. Suciu C, Cîmpean AM, Muresan AM, Izvernariu D, Raica M. E-cadherin expression in invasive breast cancer. *Romanian Journal of Morphology and Embryology* 2008; 49(4):517-523.

UNDER PEER REVIEW