

Case study

Role of Ultrasonography in Peripheral Nerve Involvement in Leprosy: A Cross-sectional Study

Abstract:

Leprosy is a chronic infectious disease with severe morbidity. The clinical skill of recognizing skin lesions of leprosy and testing for anesthesia is declining. It can only detect the presence of neuropathy, which indicates that there is already a substantial amount of nerve damage. Being one of most common treatable peripheral nerve disorders there is a need to diagnose early involvement of nerves to prevent disability. USG can show the detailed morphological changes in the nerve and can emerge as an evolving tool in early screening of peripheral nerve involvement in leprosy

Key words: Leprosy, Ultrasonography, Screening, Peripheral Nerves, MRI, Mycobacterium leprae

INTRODUCTION:

Leprosy is a chronic infectious disease caused by *Mycobacterium leprae* (*M. leprae*). Two key components of the disease are skin and nerve involvement. Leprosy patients develop anaesthesia of hands and feet, which puts them at risk of developing deformity and contractures.(7)

Loss of fingers and toes is caused by repeated injury in weak, anaesthetic limbs, and these visible deformities cause significant stigmatisation. Mononeuritis multiplexis a typical presentation of leprosy. (8)

Diagnosis is based on the recognition of anesthetic skin lesions, identification of enlarged nerves, and the demonstration of the causative organism *M leprae*. (1)

With the integration of leprosy into the general health system, the clinical skill of recognizing skin lesions of leprosy and testing for anesthesia is declining. The palpation of nerves is a disappearing clinical skill, which is subjective and prone to inter-observer variability. In the absence of clinical evidence of leprosy elsewhere, or loss of sensation , purely neuritic leprosy poses as a diagnostic challenge for early as well as experienced practitioners

Since the accurate detection of nerve thickening is very important in the classification and treatment of leprosy , there is need for a more objective method of assessment (2).At this juncture, the use of high-resolution ultrasonography (HRUS) for imaging peripheral nerves in leprosy has been ushered as a new diagnostic tool. (1)

High-resolution ultrasound reveals the nerves as distinct from the surrounding epineurium, giving a characteristic echo pattern in the transverse plane; the dark punctate areas produced by the nerve fascicle groups distributed throughout the hyperechoic background of the perineurium impart a “honeycomb” appearance. (5)

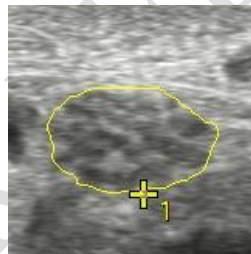


Fig 1 : Ultrasonography (USG) of nerves in leprosy

Recently, ultrasonography (USG) of nerves in leprosy has shown a number of changes, including increased vascularity, distorted echo texture and enlargement of nerves, and damage observed by USG was more extensive and included more nerves than clinically expected. (3)

Hence , there is a growing interest in USG to evolve as a core diagnostic tool for diseases of peripheral nervous system.

AIMS AND OBJECTIVES

To assess the role of USG in identifying patterns of nerve involvement across the spectrum of leprosy.

To compare the sonographic findings of peripheral nerves with clinical assessment

Case presentation:

Twenty newly diagnosed, untreated cases of leprosy were recruited , regardless of sex and age ,and were classified into paucibacillary (PB) and multibacillary (MB) on basis of clinical findings.

Nerve examination was performed in which the nerves were palpated for thickness and tenderness along with motor and sensory involvement .

Clinical grading of the nerve thickness was done and tenderness, motor and sensory deficit was recorded

Chart 1 : Clinical grading of the nerve thickness

NORMAL (GRADE 0)	Normo-echogenic
GRADE 1	Some hypo-reflectivity
GRADE 2	Obvious hypo-reflectivity
GRADE 3	Loss of fascicular pattern
GRADE 0	No nerve thickening
GRADE 1	Thickened compared to opposite side
GRADE 2	Rope like thickening
GRADE 3	Beading or nodularity of nerves

USG of B/L ulnar nerve (UN) & median nerve (MN) & Common peroneal nerve (CPN) was performed subsequently to identify the changes across the disease spectrum.

Sonographic changes including cross sectional area (CSA), change in echotexture and other abnormalities such as fusiform enlargement and oedema, were noted. CSA was measured at the maximum diameter.

The normal CSAs of the nerves considered for UN (0.085 cm²), MN (0.062 cm²), CPN(0.059 cm²)) were those calculated by Jain et al. (3) in their study of 30 those calculated by Jain et al. (3) in their study of 30 healthy Indian subjects

The normal nerve is echogenic with a fascicular pattern. Any deviation from the normal echotexture was graded as following:

DISCUSSION

Out of 20 cases of Leprosy (11 of MB and 9 of PB Leprosy), cross sectional area of median and ulnar nerve were significantly increased in patients with MB as compared to PB, however both PB and MB patients showed increased CSA as compared to normal limit for healthy individuals.

Patients with hypo-echogenicity and increased CSA showed a strong correlation with sensory deficit.

Out of 120 nerves examined ,70 showed nerve thickness clinically, (58%)however increased CSA of nerve was identified in 86/120 nerves on USG (71%); the difference was statistically significant ($P < 0.001$)

Similarly, 10 clinically thickened nerves (grade I) (UN 8 ,MN 1,CPN 1) did not show any increase in CSA on sonographic examination.

Out of the 50 nerves that were not thickened clinically , USG was able to detect 26 nerves with increased CSA and hypo-echogenicity.

All patients with grade II and higher nerve thickness showed increased CSA on USG findings

Among the 9 PB patients, it was seen that in 3 cases, where clinical evaluation did not detect any nerve thickening, USG could detect enlargement in more than one nerve.

The altered echotexture defined as the loss of normal honey-comb structure was found in 56/120 nerves (46%) and correlated with sensory/motor impairment

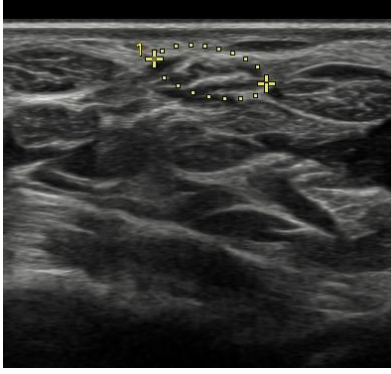SPECTRUM OF INVOLVEMENT

Fig 2 : Normal ulnar nerve with fascicular pattern

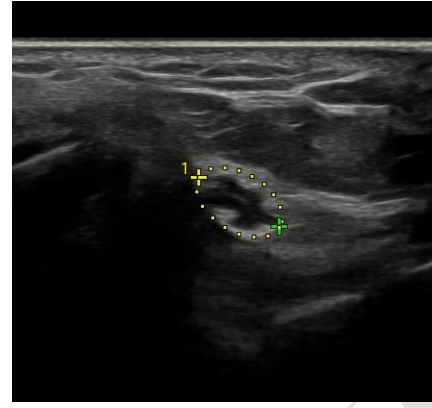


Fig 3 : Hypoechoic ulnar nerve of a leprosy patient (Early involvement)

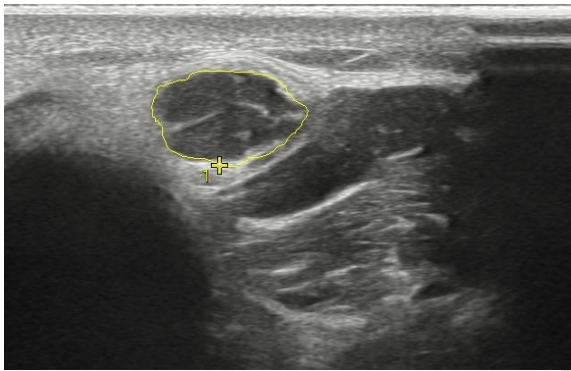


Fig 4 : Ulnar nerve of a MB leprosy patient showing marked increased CSA & hypoechoic nerve with poorly maintained fascicular pattern. (Advanced)

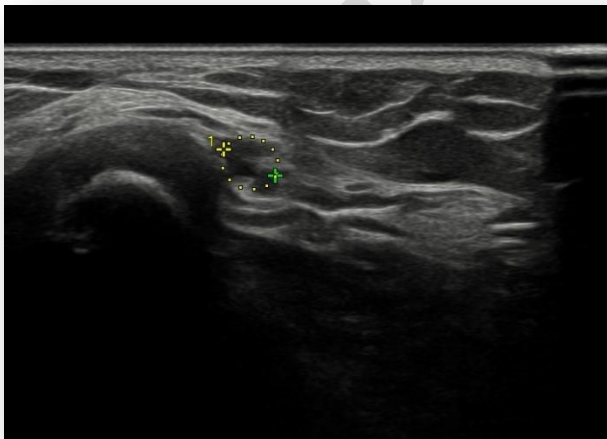
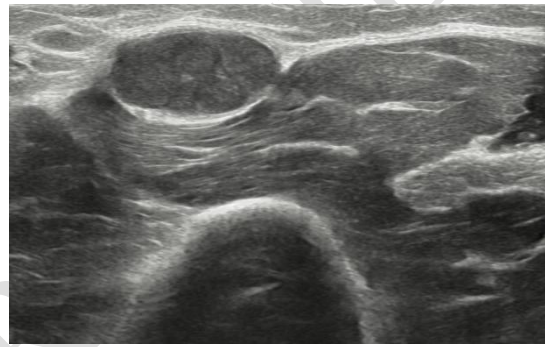


Fig 5 : High resolution ultrasound image (transverse view) of normal CPN

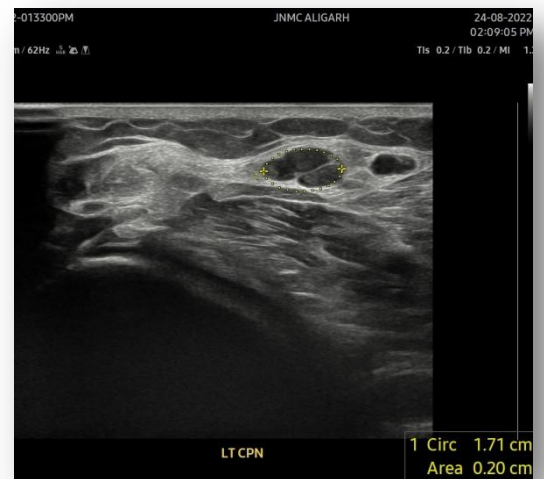

Fig 6 : CPN of a leprosy patient showing marked thickening and hypoechoic echotexture, however fascicular pattern is maintained

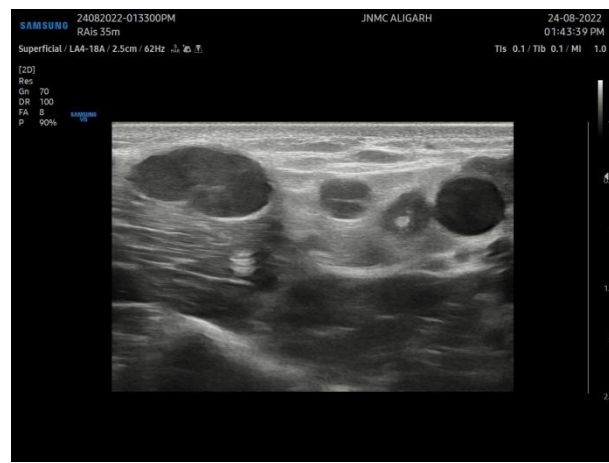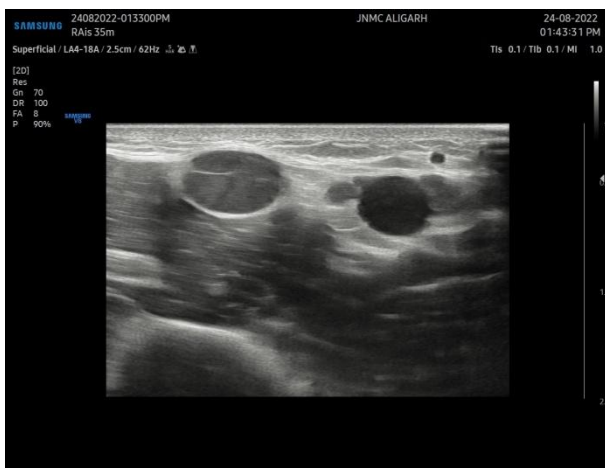


Fig 7 :High resolution ultrasound image (transverse view) of ulnar nerve of a leprosy patient showing markedly thickened , hypoechoic nerve with complete loss of fascicular pattern and edema (endoneurial abscess)

In our study , we were able to detect 86/120 nerves with

thickening and involvement, 26 of which were reported normal clinically. The degree of morphological changes on USG correlated strongly with the symptoms of the patient . Endo-neural abscess formation was demonstrated in few cases.

In nerves with clinical features of impairment of function, HRUS was able to detect more extensive changes than those diagnosed clinically.

Moreover, many clinically normal nerves showed features of nerve involvement in HRUS analysis

Careful clinical testing can be useful, can only detect the presence of neuropathy, which indicates that there is already a substantial amount of nerve damage

Hence, being one of most common treatable peripheral nerve disorders there is a need to diagnose early involvement of nerves to prevent disability

The greater sensitivity of high-resolution ultrasound in comparison to the clinical examination to detect nerve thickening becomes more significant in the setting of nerve function impairment, since it is one of the cardinal criteria to diagnose leprosy

USG can show the detailed morphological changes in the nerve—the internal structure of individual fascicles based on echogenicity,^[6] as well as the perineurium and the epineurium.(4)

The use of color Doppler (CD) in addition enables the visualization of vascular channels and blood flow signals within the nerve

By defining the diagnostic parameters for peripheral nerve involvement on high-resolution ultrasound, we might improve the sensitivity of this criterion to diagnose leprosy

Real-time and dynamic imaging, maneuverability to examine the length of the nerve, and pinpoint the precise location of a nerve lesion make it a preferred option in leprosy. (2)

It permits analysis of nerve involvement and can be performed at the patient's bedside, and there are no contraindications to USG.(6,7)

Thought USG is operator-dependent and produces limited images that may not resemble traditional anatomical illustrations. Despite these limitations, USG has many advantages for nerve imaging. It has high spatial resolution, providing excellent views of nerves as small as 1 mm.(3)

CONCLUSION

USG is an excellent portable cost-friendly & non-invasive modality for imaging of peripheral nerves providing a high-resolution spatial image that can be an important tool in classification, early detection and management of leprosy.

Early changes in morphology of nerves is useful for confirmation in all clinical types of leprosy, and can complement other diagnostic investigations, and as it is easily available it has potential to become the first modality for the evaluation of peripheral nerves.

REFERENCES

- 1) Suneetha, Sujai K.; Rao, P. Narasimha¹. High-Resolution Ultrasonography in Leprosy: Value and Applications. Indian Dermatology Online Journal: Jul–Aug 2021 - Volume 12 - Issue 4 - p 497-499
- 2) Sreejith K, Sasidharanpillai S, Ajithkumar K, Mani RM, Chathoth AT, Menon PS, et al. High-resolution ultrasound in the assessment of peripheral nerves in leprosy: A comparative cross-sectional study. Indian J Dermatol Venereol Leprol 2021;87:199-206.
- 3) Jain S, Visser LH, Praveen TL et al. High-resolution sonography: A new technique to detect nerve damage in leprosy. PLoS Negl Trop Dis, 2009; 3: e498.
- 4) Rao PN, Jain S. Newer management options in leprosy. Indian J Dermatol, 2013; 58: 6–1
- 5) Afsal M, Chowdhury V, Prakash A et al. Evaluation of peripheral nerve lesions with high-resolution ultrasonography and color Doppler. Neurol India, 2016; 64: 1002–1009.
- 6) Zaidman CM, Seelig MJ, Baker JC et al. Detection of peripheral nerve pathology: Comparison of ultrasound and MRI. Neurology, 2013; 80: 1634–1640.
- 7) Visser LH, Smidt MH, Lee ML. High-resolution sonography versus EMG in the diagnosis of carpal tunnel syndrome. J Neurol Neurosurg Psychiatry, 2008; 79: 63–67.
- 8) Smith WC, Saunderson P. Leprosy. BMJ Clin Evid, 2010; 2010: pii: 0915s high spatial resolution, providing excellent views of nerves as small as 1 mm.(3)