

Case study

# DISSEMINATED CRYPTOCOCCOSIS IN AN IMMUNOCOMPETENT PATIENT

## ABSTRACT:

Cryptococcosis is the fungal infection caused by the yeast that belongs to the cryptococcus species which is divided into two broad categories, Cryptococcus neoformans and Cryptococcus gattii. Cryptococcosis is the opportunistic infection in the immunocompromised individual, particularly in HIV infected individual. In immunocompetent individual there may be serological evidence of cryptococcal infection, but cryptococcal disease is very rare in the absence of impaired immunity. Here we are reporting a case of disseminated cryptococcosis (multiple cold abscess, sacroiliitis and asymptomatic pulmonary

nodules) in immunocompetent patient, which was initially thought to be mycobacterium tubercular infection.

**KEY WORDS: Cryptococcosis, Immunocompetent, Cold Abscess**

## **INTRODUCTION:**

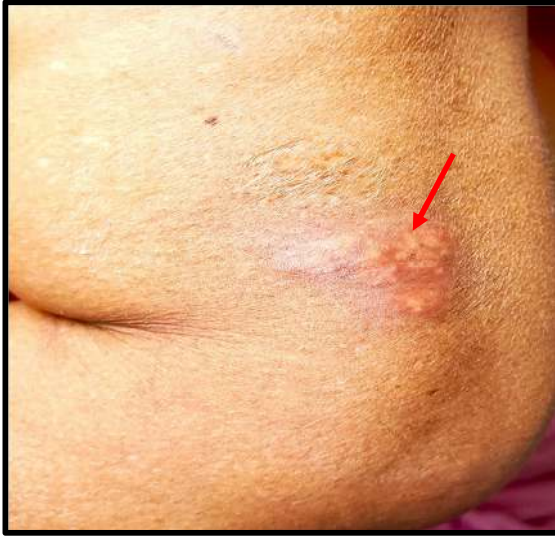Cryptococcal infection is acquired from the environment. Cryptococcus neoformans is frequently found in the soil, infected with pigeon excreta (1). In contrast, Cryptococcus gattii inhabits a variety of arboreal species, including several types of eucalyptus tree. In immunocompromised patient, the majority of the infections are caused by Cryptococcus neoformans, where Cryptococcus gattii more commonly affects HIV negative individual (2). HIV infected individual with CD4 count less than 100cells/mm<sup>3</sup> are at highest risk of infection (2). The annual incidence of cryptococcosis in HIV negative patients is approximately 0.2 to 0.9 per 100,000, depending on the geographical area studied (3). The spectrum of the disease caused by cryptococcus species consist predominantly of meningoencephalitis and pneumonia but skin and soft tissue infection also occur, in fact it can affect any organ and tissue. Cryptococcosis can present with wide variety of skin manifestation, including papule, plaque, purpura, vesicles, nodule, abscess, granuloma, pustule, draining sinus, cellulitis, tumour like lesion, rash (4).

## **CASE REPORT:**

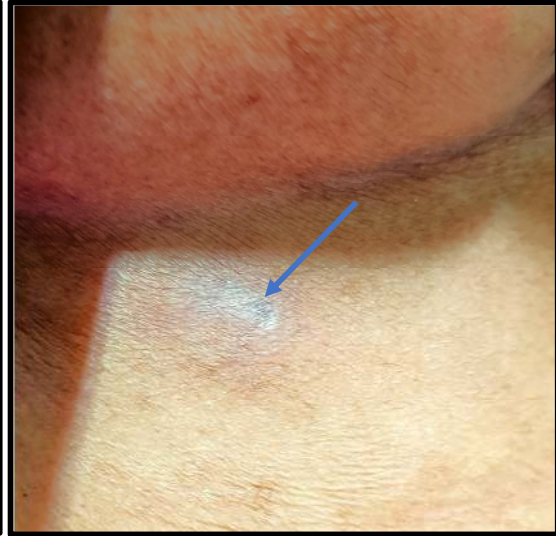
55-year-old female without any comorbidity presented with complaints of swelling over the left elbow, followed by left sided lower back region and behind the left ear for last 3 months, pain in the right buttock for similar duration. She also complained of discharge from right inframammary area for last 1 month. On clinical examination, she had mild pallor with unremarkable systemic examination. On the left elbow she had papulopustular lesion (Figure 1), In inframammary region, there was discharging sinus with underlying swelling (Figure 2) and nodular lesion behind the ear (Figure 3). On the left infrascapular area there was a soft tissue swelling without overlying sinus

formation (**Figure 4**). Sacroiliac joint tenderness was there in right side with positive Patrick test. Central nervous system examination was unremarkable.

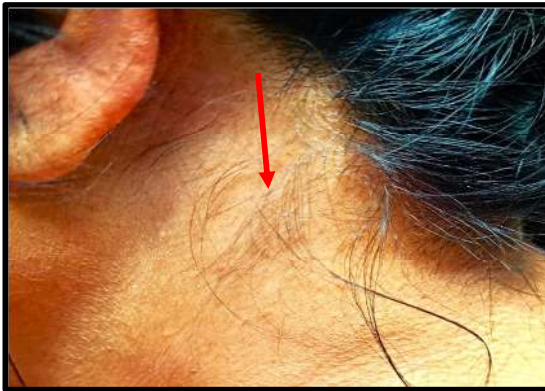On evaluation, complete hemogram showed anaemia ~~which was normocytic and normochromic pattern~~ (Haemoglobin 10.8gm/dl, TLC 4500/ $\mu$ l, Platelet count 3.5 Lac) with raised inflammatory markers (ESR 110mm/hour, CRP 6.45 mg/L) ~~revealed~~. Liver and renal function tests were normal. Chest imaging (HRCT thorax) revealed broncho centric nodules with lymphocytic interstitial pneumonia (**Figure 5a&b**). Lymphocytic cellularity was found in the BAL fluid study without any evidence of infection. Ultrasonogram of whole abdomen and pelvis showed no pelvic collection or psoas abscess. USG of bilateral breast showed 22 $\times$ 15 mm sized thick wall collection in the anterior chest wall below the inframammary fold on the right side, in the subcutaneous plane (volume 0.5 cc) (**Figure 6**). MRI of the back revealed altered signal intensity peripherally enhancing septated collection in left posterior abdominal wall in intermuscular plain and intramuscular plane of left latissimus dorsi muscle extending into subcutaneous plane with partial to complete thick enhancing septation (**Figure 7a and 7b**). MRI of pelvis showed altered signal intensity enhancing areas noted in right sacrum involving right sacroiliac joint (**Figure 8**). MRI of left elbow joint showed asymmetrical bone destruction with marrow oedema of olecranon process, surrounding soft tissue swelling with oedema around triceps-anconaeus (**Figure 9a, b, c, d**). The contrast MRI of brain revealed no evidence of central nervous system involvement. CSF study was unremarkable. USG guided aspiration was done from back swelling and aspirate fluid ZN stain, modified ZN stain, gram stain as well as CBNAAT were negative. Rapid culture for mycobacterium tuberculosis from aspirate fluid was negative. Special stain like Grocott stain and Alcian blue stain of pus material revealed budding yeast cells (**Figure 10a&b**). India ink stain showed round budding yeast with small capsule (**Figure 11**). Antigen testing for cryptococcus was positive (**Titre 1:126**) by Cryptococcal Antigen Latex Agglutination System (CALAS) in the pus material (**Figure 11**). Culture growth from pus revealed no fungal growth. She had negative result of HIV serological test. Her CD4 T cell count was normal and the level of serum immunoglobulin including IgG, IgA, IgM, and total IgE were within normal range.



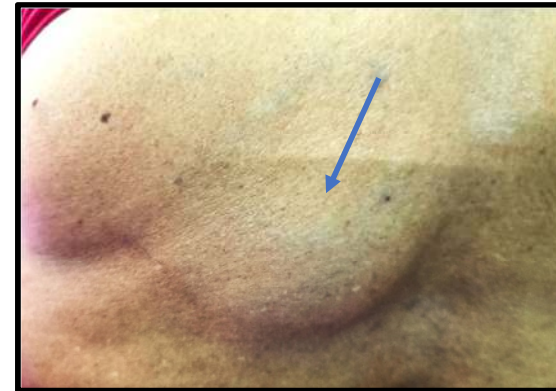**Figure 1: Papulopustular lesion over left elbow (Red Arrow)**



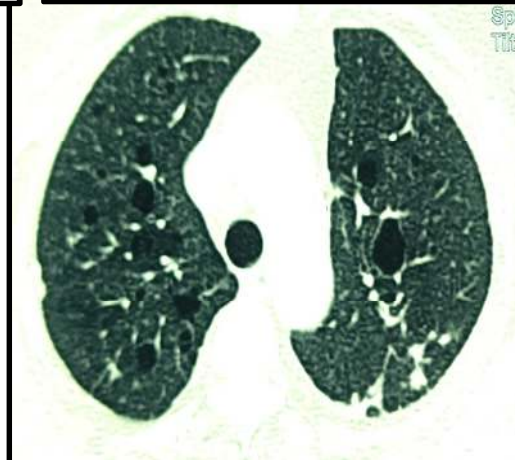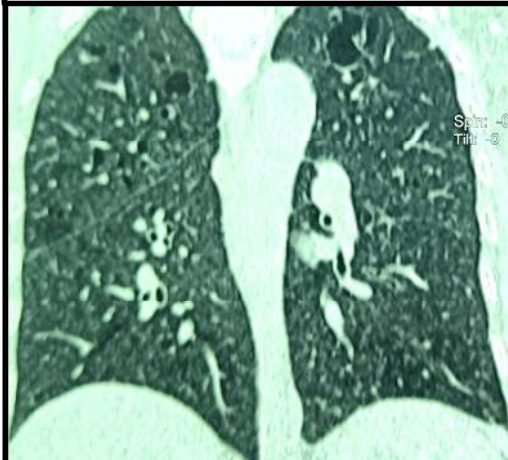
**Figure 2: Discharging sinus in right inframammary region (Blue Arrow)**



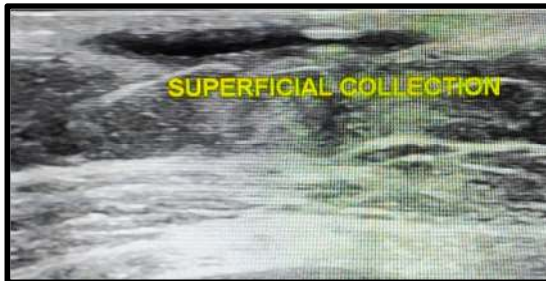**Figure 3: Nodule behind the ear (Red Arrow)**



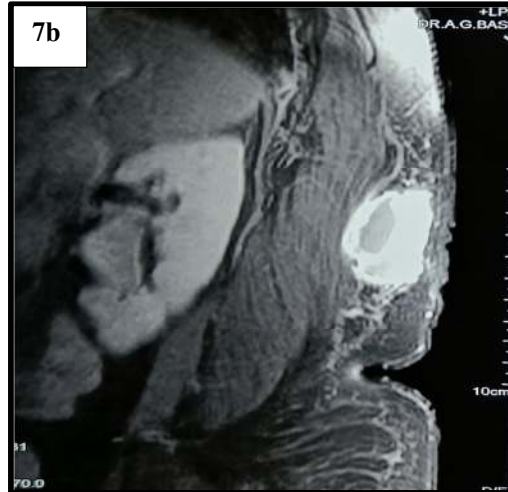
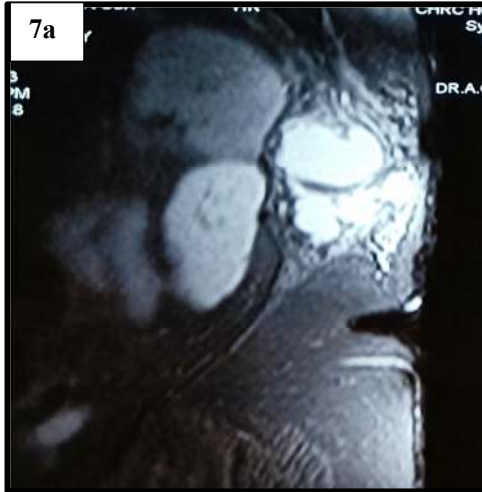**Figure 4: Soft tissue swelling in infrascapular area (Blue Arrow)**



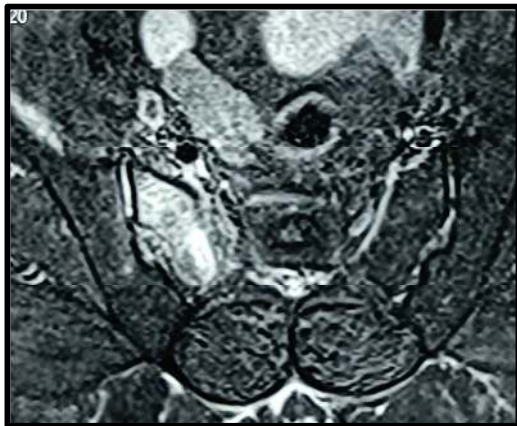**Figure 5a & b:(HRCT thorax): Brochocentric nodule with lymphocytic interstitial pneumonia**



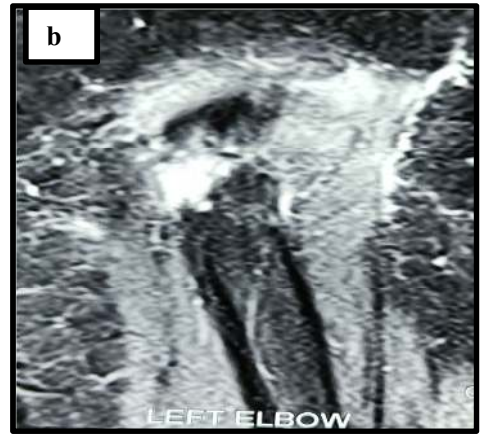
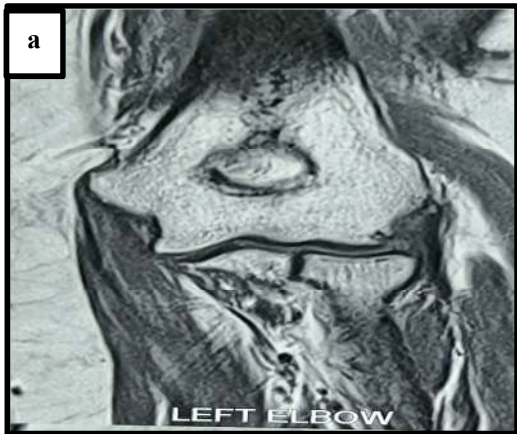
**Figure 6: Superficial collection in anterior chest wall in right inframammary area**



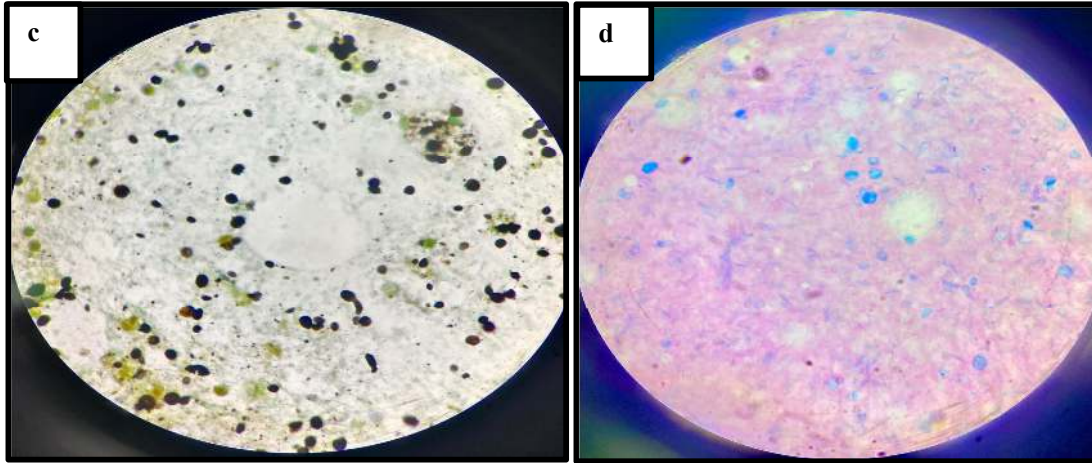
**Figure 7a & 7b: Collection in left posterior abdominal wall and left latissimus dorsi muscle**



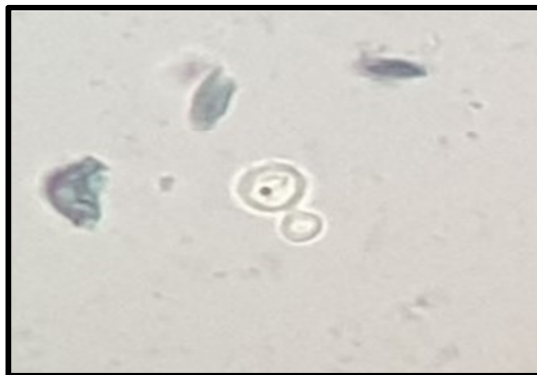**Figure 8: Altered signal intensity changes in right sacrum involving right sacroiliac joint**



**Figure 9a & b: Asymmetrical bone destruction with marrow oedema of olecranon process**



**Figure 9c (Grocott Stain), 9d (Alcian Blue Stain): Capsule Negative Budding**



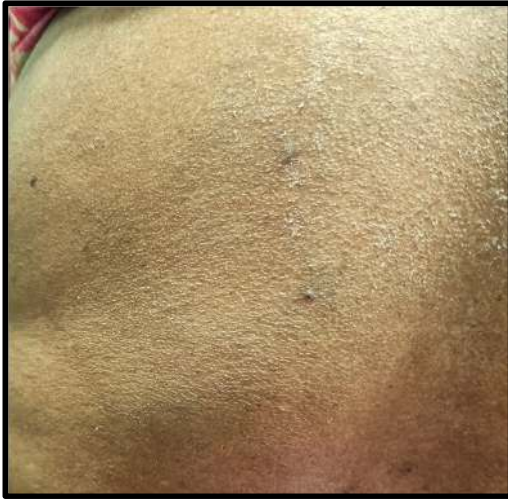**Figure 10: Round budding yeast with small capsule**



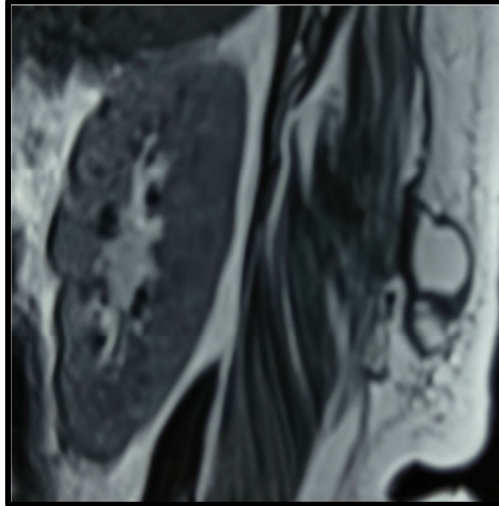
**Figure 11: Antigen testing for positive (Titre 1:126) by CALAS**

## **DISCUSSION:**

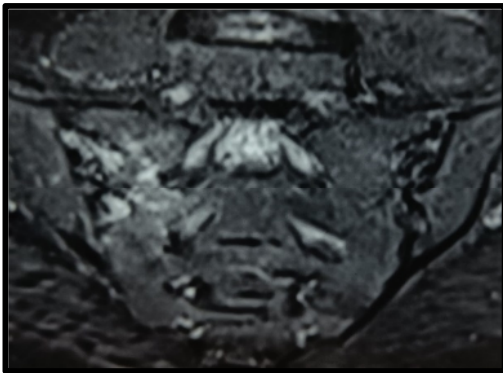
Cryptococcosis is an opportunistic infectious disease caused by basidiomycetous, yeast like fungus that exist as yeast in both environment and tissue (5). Primary foci of the infection is the lung by respiratory droplets with dissemination through hematogenous route in the meninges, skin, bone, prostate, and other organs. Disseminated cryptococcosis in immunocompetent population is very rare and usually involves central nervous system. Most of the cutaneous infection occur as a sign of disseminated cryptococcal infection, which can be seen in 10 to 15% of the cases (6). In tuberculosis endemic countries, it can be easily misdiagnosed as tuberculosis as there is high degree of overlap in clinical, laboratory, and radiographic presentation. In high tuberculosis burden area disseminated tuberculosis should be ruled out carefully when cryptococcosis is complicated with tuberculosis. Disseminated cryptococcosis is confirmed by positive culture or pathological results. Cryptococcus from biological samples can easily grow on routine fungal and bacterial culture media. However, our patient was negative for fungal culture, which may be due to insensitivity of culture at early stage of infection. In addition, less fungemia is seen in immunocompetent patient compared with immunocompromised host. CLAT detect the capsular polysaccharide antigens, which has been established as a reliable diagnostic tool with overall sensitivities of 93 to 100% (7). The capsule is composed of glucuronoxylomannan and galactoxylomannan polysaccharide. It is the one of the classical virulent factors for neoformans and mutant without capsule are less virulent (8). Several genes that synthesize capsules have been identified and site directed gene mutants result in hypo capsular or acapsular strains. The CrAg test is approximately 95% sensitive and specific (9). False negative results are reported due to poorly encapsulated strain. Our patient was treated with liposomal amphotericin B (3mg/kg) along with oral Flucytosine (100mg/kg/day) for 14 days. Now the patient is on consolidation phase with oral fluconazole (800 mg/day). After 14 days of induction therapy, swellings have been reduced in size (Figure 12); buttock pain has been improved. Repeat MRI of the back was done which revealed decreased size of the collection with less signal intensity (Figure 13). Repeat MRI of SI joint also showed decreased signal intensity of right SI joint (Figure 14).



**Figure 12: Back swelling has reduced in size after 14 days of induction therapy**



**Figure 13(MRI Back): Decreased collection size**



**Figure 14: MRI of SI joint showed decreased signal intensity compared to before therapy**

### **CONCLUSION:**

In developing **country** like India where there is **high** incidence of tuberculosis, fungal infection like cryptococcosis is likely to be missed; if high index of clinical suspicion is not there. From this case, we want to highlight that disseminated cryptococcosis should be kept in mind, where clinical picture is like tuberculosis but relevant investigation does not define tuberculosis.

**CONSENT:**

Written informed consent was obtained from the patient for publication of this case report and accompanying images.

**REFERENCES:**

- 1) Takahara DT, Lazéra Mdos S, Wanke B, Trilles L, Dutra V, Paula DA, Nakazato L, Anzai MC, Leite Júnior DP, Paula CR, Hahn RC. First report on *Cryptococcus neoformans* in pigeon excreta from public and residential locations in the metropolitan area of Cuiabá, State of Mato Grosso, Brazil. *Rev Inst Med Trop Sao Paulo*. 2013 Nov-Dec;55(6):371-6. doi: 10.1590/S0036-46652013000600001. PMID: 24213188; PMCID: PMC4105083.
- 2) Bruner KT, Franco-Paredes C, Henao-Martínez AF, Steele GM, Chastain DB. *Cryptococcus gattii* Complex Infections in HIV-Infected Patients, South-eastern United States. *Emerg Infect Dis*. 2018 Nov;24(11):1998-2002. doi: 10.3201/eid2411.180787. PMID: 30334702; PMCID: PMC6199986.
- 3) Antinori S. New Insights into HIV/AIDS-Associated Cryptococcosis. *ISRN AIDS*. 2013 Feb 25; 2013:471363. doi: 10.1155/2013/471363. PMID: 24052889; PMCID: PMC3767198.
- 4) Maziarz EK, Perfect JR. Cryptococcosis. *Infect Dis Clin North Am*. 2016 Mar;30(1):179-206. doi: 10.1016/j.idc.2015.10.006. PMID: 26897067; PMCID: PMC5808417.

- 5) Maziarz EK, Perfect JR. Cryptococcosis. *Infect Dis Clin North Am.* 2016 Mar;30(1):179-206. doi: 10.1016/j.idc.2015.10.006. PMID: 26897067; PMCID: PMC5808417.
- 6) Srivastava GN, Tilak R, Yadav J, Bansal M. Cutaneous Cryptococcus: marker for disseminated infection. *BMJ Case Rep.* 2015 Jul 21;2015:bcr2015210898. doi: 10.1136/bcr-2015-210898. PMID: 26199299; PMCID: PMC4513468.
- 7) Negroni R, Cendoya C, Arechavala AI, Robles AM, Bianchi M, Bava AJ, Helou S. Detection of *Cryptococcus neoformans* capsular polysaccharide antigen in asymptomatic HIV-infected patients. *Rev Inst Med Trop Sao Paulo.* 1995 Sep-Oct;37(5):385-9. doi: 10.1590/s0036-46651995000500002. PMID: 8729747.
- 8) Zaragoza O, Rodrigues ML, De Jesus M, Frases S, Dadachova E, Casadevall A. The capsule of the fungal pathogen *Cryptococcus neoformans*. *Adv Appl Microbiol.* 2009;68:133-216. doi: 10.1016/S0065-2164(09)01204-0. PMID: 19426855; PMCID: PMC2739887.
- 9) Rajasingham R, Wake RM, Beyene T, Katende A, Letang E, Boulware DR. Cryptococcal Meningitis Diagnostics and Screening in the Era of Point-of-Care Laboratory Testing. *J Clin Microbiol.* 2019 Jan 2;57(1):e01238-18. doi: 10.1128/JCM.01238-18. PMID: 30257903; PMCID: PMC6322457.