

Case study

Omental Cysts A Rare Intra-Abdominal Pathology: Two Case Reports

Abstract

Omental cysts are any cyst that is confined to greater or lesser omentum, the most common site benign the greater omentum. The incidence of omental cyst is 1 in 20000 among children's. So far, only 150 cases have been reported in the literature.

Omental cysts are benign intra-abdominal lesions primarily in children under the age of 10 years (68%), although they have been reported in adults. These are most commonly serous-filled cysts lined by cuboidal epithelium with fibrous wall. The cysts may be filled with serous, chylous or haemorrhagic fluid. They can also present with features of an acute abdomen due to bleeding in to the cyst, torsion or rupture of the cysts.

Herein, we report two cases of omental cysts, 32 years old lady who presented with abdominal lump at epigastric and umbilical region and cyst was originating from lesser sac. Second case of 8 years' boy who presented with pain in abdomen and lump in abdomen. Both patients were diagnosed on abdominal ultrasonography, a cystic mass which is freely mobile in the abdomen. Patients underwent explorative laparotomy and we performed total excision of the omental cyst.

Keywords

Greater omental cyst, Lesser omental cyst, Omental cyst

Introduction

Omental cysts are cystic lymphangioma and are benign proliferation of ectopic lymphatics that do not have communication with the normal lymphatic system. They occur usually in the paediatric age group and are in adults. Omental cyst is located in lesser and greater omentum. They are single or multiple unilocular or multilocular, may contains serous chylous, haemorrhagic or infected fluids. [1,2]

The first report of an omental cyst was published in 1852 by Gairdner. Omental Cysts are generally asymptomatic abdominal palpable mass in up to 60% cases and large cysts cause compression symptoms. The most common symptoms are pain in abdomen and distension of abdomen. Omental cysts in children may present with complication like torsion and intestinal volvulus, intra-cystic haemorrhage, infection or rupture. Large omental cysts are commonly mistaken for ascites on ultrasonography. Radiological investigation, ultrasonography and CT scan is diagnostic modality for mesenteric cysts. The preferred treatment of omental cyst in complete excision of the cyst. [2,3,4]

Case Reports

Case 1

A 14 years' boy was admitted to our centre on 11/05/2012, with complains of pain and a palpable lump in the abdomen. On physical examination of the child, abdomen was soft and there was palpable lump and it was freely mobile. A transabdominal ultrasound was performed which

showed a large cystic mass of size 10x8 cm and solitary, arising from the greater omentum. CT Abdomen was not done. His laboratory investigation was normal and patient was planned for surgery.

The patient underwent laparotomy through midline incision. During surgery a well-defined cyst of size 10x8 cm and spherical in shaper was wrapped in the greater omentum. Cyst was predominantly on right side and 15 cm away from the transverse colon. The greater omental cyst was freely mobile. No other cysts were noted in the omentum and mesentery. Total excision of the omental cyst along with the cut of the omentum was done using a combination of ligatures and cautery. No bleeding was observed and no drains were placed. A postoperative period is uneventful and the boy was discharged on 8th post-operative day.

On gross examination an omental cyst of size 10x8 cm and containing transparent fluid. Histopathological examination revealed as wall of cyst lined by flattened cells containing serous fluid suggestive of cystic lymphangioma. Boy is healthy for more than one years after surgery. **(Figure 1-3)**

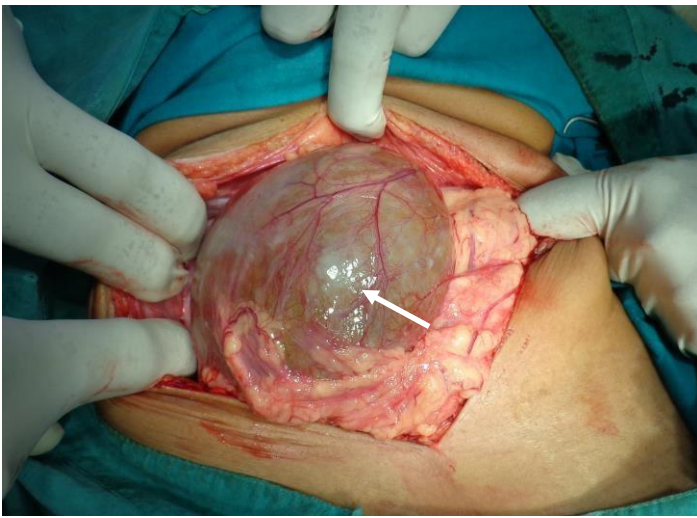


Fig-1 Intraoperative photographs showing omental cyst of greater omentum

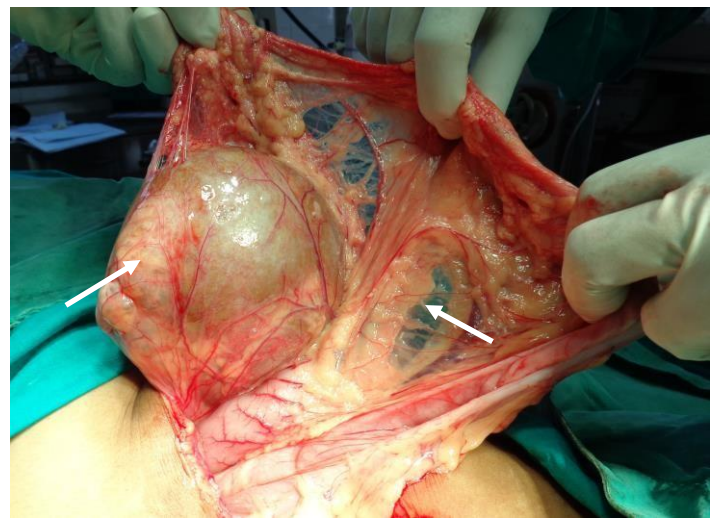


Fig-2 Intraoperative photographs showing Cystic lymphangioma of greater omentum

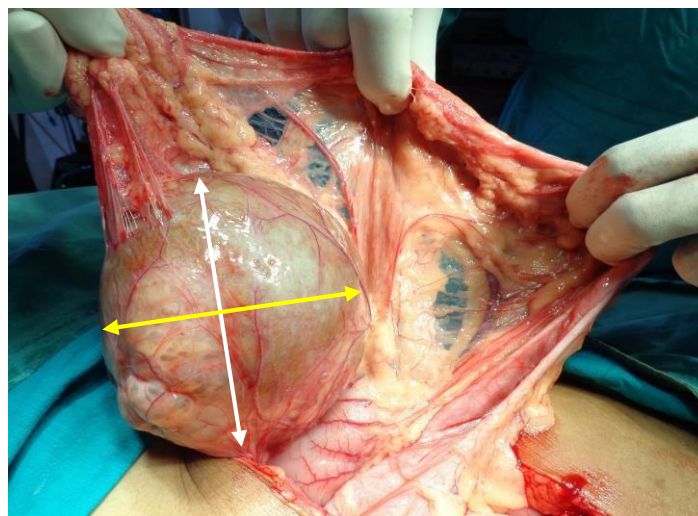


Fig-3 Intraoperative photographs showing Cystic lymphangioma of size 10x8 cm

Case 2

A 32 years old female presented to our centre on 22/05/2012, with complains of lump in abdomen for 6 months, which was gradually increase in size and associated with pain in abdomen. On physical examination lump was extending from xiphisternum up to umbilicus and lump was moving with deep inspiration. We noticed a huge lump in the upper part of the abdomen, which was non-tender, smooth surfaced with a very little mobility due to huge in size.

An ultrasonography revealed an anechoic cystic lesion of size 15x12x10cm in the epigastric region and location of cyst was anterior to stomach and pancreas. Diagnosis of mesenteric cyst of pseudo-pancreatic cyst was made. A large cyst, thick walled and unilocular cystic lesion extending from xiphisternum up to the umbilicus. Her routine haematological and bio chemical investigation were normal. Her serum amylase was normal.

The patient underwent explorative laparotomy and we noticed a large cyst which was extending from the xiphisternum up to the umbilicus. The cyst was found enclosed with in the lesser omentum and cyst was located anterior to the stomach and pancreas was normal. Huge cyst was originated from lesser omentum of size 15x12x10 cm and spherical in shape. Total excision of the cyst was performed and complete haemostasis achieved.

On gross examination of the cyst it was thick walled, of size 15x12x10cm and spherical in shape. Histopathological examination revealed that the wall of cyst lined by cuboidal epithelium and the diagnosis of omental cyst was confirmed. Postoperative recovery was uneventful and patient discharged on 8th post-operative day. After follow-up of 6-month patient was healthy. (Figure 4-7)

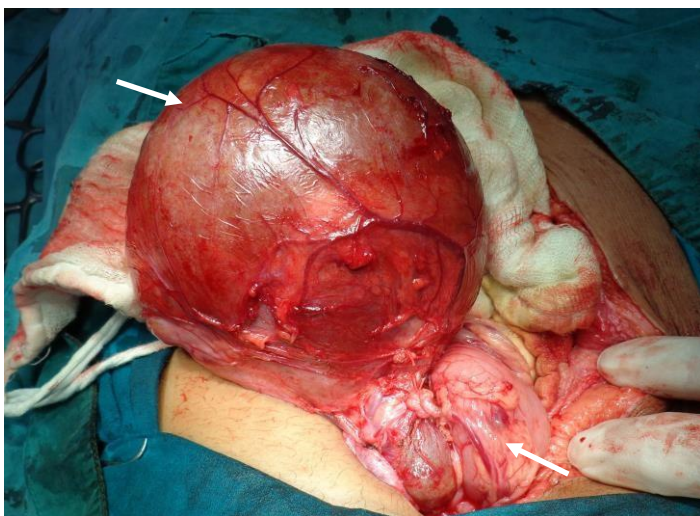


Fig-4 Intraoperative photographs showing omental cyst of lesser omentum

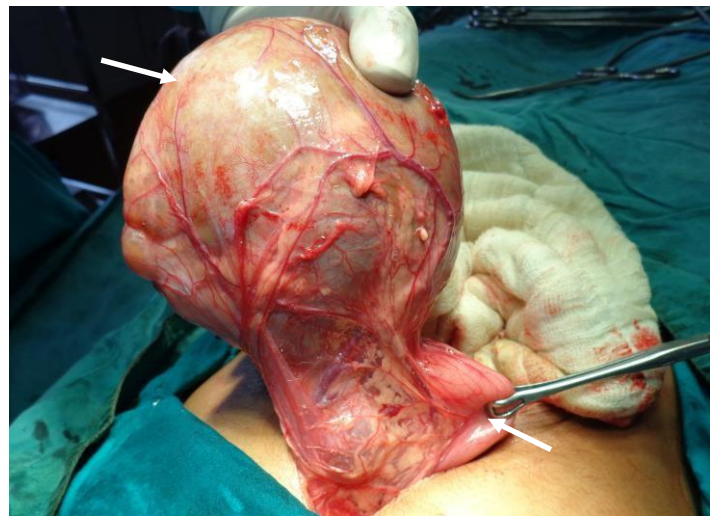

Fig-5 Intraoperative photographs showing lesser omental cyst attached to stomach

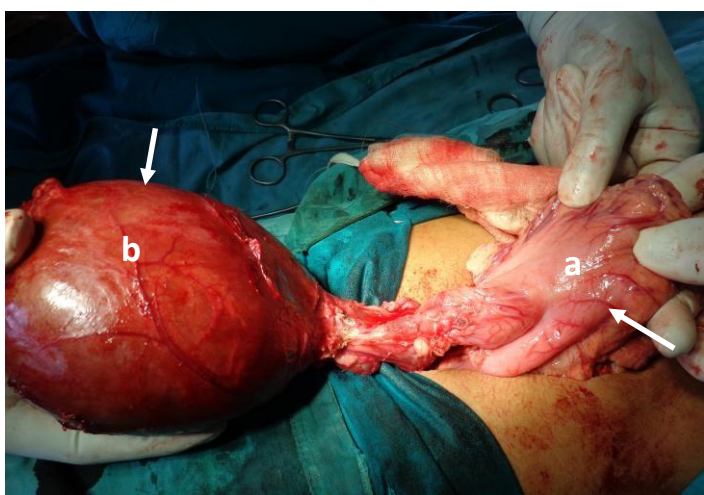


Fig-6 Intraoperative photographs showing excision of b-large lesser omental cyst a- stomach

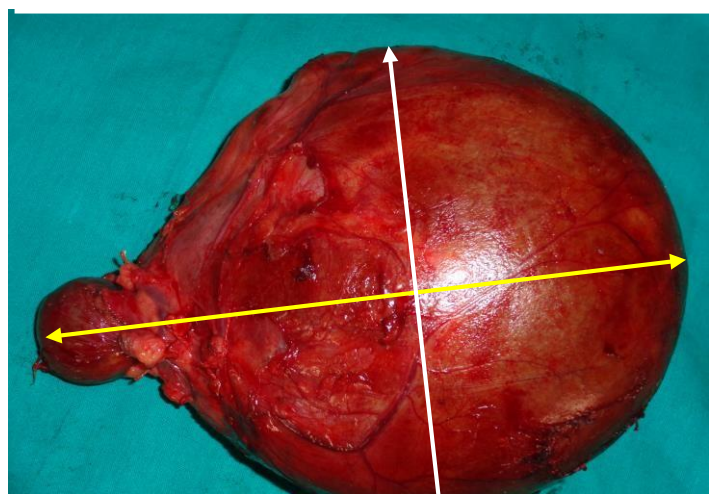


Fig-7 Intraoperative photographs showing large lesser omental cyst of size 15x12x10 cm

Discussion

Omental cyst is the benign proliferation of ectopic lymphatics that lack communication with the normal lymphatic system. Other theories include.

1. Failure of the embryonic lymph channels to join the venous channel.
2. Failure of the leaves of the mesentery to fuse.
3. Trauma
4. Degeneration of lymph-nodes. [1,2]

Omental cysts are present in the greater and lesser omentum and are lined by endothelium mainly cuboidal epithelium. Omental cysts are generally asymptomatic but large cyst causes compressive symptoms. The most common symptoms are pain in abdomen and distension of abdomen. Omental cysts in children's may present with complication like torsion, volvulus, intestinal obstruction, intra-cystic haemorrhage, infection or rupture. [3,4,5],

A correct preoperative diagnosis cyst has been made in only 13-25% of cases. Abdominal ultrasonography reveals fluid filled cystic structures with internal echoes from debris, haemorrhage or infection. CT and MRI are the most useful investigation to diagnosis the condition preoperatively. Total surgical excision of the omental cyst is the gold standard treatment. [2]

In our cases, a paediatric case of omental cyst was located in the greater omentum and second adult case of female, cyst was located in the lesser omentum, which is extremely rare cases and only 5-7 cases are reported in the literature. They are mostly lymphatic cysts or cystic lymphangioma. Both cases presented with palpable abdominal masses and pain in abdomen. Both cysts were single cysts, containing serous and lymph fluid inside the cysts. [1,2,3]

Conclusion

Omental cysts are rare intra-abdominal benign tumours occupying commonly in childhood but rare in adults. Laparoscopic resection of the small cysts can be performed by an experienced surgeon but in large omental cysts open surgery is strongly recommended. Complete excision of the omental cyst offers an excellent results and prognosis.

Ethical Approval:

As per international standard or university standard written ethical approval has been collected and preserved by the author(s).

Consent

As per international standard or university standard, patient(s) and Parental written consent has been collected and preserved by the author(s).

References

1. Robbins KJ, Antiel RM, Shakhsher BA. Omental cyst: a case report and review of the literature. *Ann Pediatr Surg.* 2021;17(1):62. doi: 10.1186/s43159-021-00129-0. Epub 2021 Dec 2. PMID: 34992640; PMCID: PMC8679654.
2. Baghai-Wadji M, JalalKamali A, Mirshekari T. Cystic lymphangioma of the lesser sac. *Can J Surg.* 2006 Aug;49(4):292. PMID: 16955953; PMCID: PMC3207560.
3. Mahim Koshariya, Vankodoth Vamshi Nayak, Rahul Rao Rathod, Sourabh Mishra, Bhoomika Agarwal and Shivangi Pandey , Lesser Omental Cyst in Adults: A Rare Intraabdominal Pathology and Literature Review, *Acta Scientific Gastrointestinal Disorders* (ISSN: 2582-1091)
4. Souvik Saha , Garga Basu, Lesser Omental Cyst: A Rare Case Of Abdominal Lump: A case Report

And Review Of Literature, IOSR Journal of Dental and Medical Sciences (IOSR-JDMS) e-ISSN: 2279-0853, p-ISSN: 2279-0861. Volume 14, Issue 4 Ver. I (Apr. 2015), PP 62-65

5. Alemu H, Alemu S, Berhane M. Omental Cyst Presenting as an Acute Abdomen in a Pediatric Patient: A Case Report. *Int Med Case Rep J.* 2022;15:43-46
<https://doi.org/10.2147/IMCRJ.S351406>
6. Maimuna Sayeeda, Benzamina Sharmin Aktera, Wahiduzzaman Mazumdera, Bazlul Karima Bishnu Pada Deyb, Omental Cyst – Rare Cause of Abdominal Pain in a 7-Year-Old Child: A Case Report, *GE Port J Gastroenterol* 2021;28:202–206, DOI: 10.1159/000510022
7. Dahal GR. Omental lymphangioma: a rare case report. *Journal of Chitwan Medical College.*2020;10(33):106-08
8. Shah, Apoorvi; Phatak, Suresh; Jain, Soumya; Samad, Sameeda. Hemorrhagic Omental Cyst in a Child Presenting with Hemoperitoneum: Ultrasonography Diagnosis. *Journal of Datta Meghe Institute of Medical Sciences University* 15(4):p 672-674, Oct–Dec 2020. | DOI: 10.4103/jdmimsu.jdmimsu_140_19
9. Tezuka K, Ogawa Y, Satake K, et al. Lymphangioma of lesser omentum associated with abdominal and esophageal carcinoma: report of a case. *Surg Today* 2002;32:362-6. [PubMed]
10. Ouaisi M, Emungania O, Sebbag H, et al. [Cystic lymphangioma of lesser omentum.] *Presse Med* 2003;32:1165-6. [PubMed]