

Intradural Spinal metastasis from Renal cell carcinoma: A rare entity

ABSTRACT:

Renal cell carcinoma constitutes about 2% of all malignant neoplasms . It is known to metastasize to lung, bone and lymph nodes; intradural spinal metastases(IDSM) are relatively uncommon, only 5% as per literature. Keeping in mind the curative, functional, and palliative aspects; the management should be tailored for each patient. Surgery represents the gold standard of treatment for spinal metastases.

However Radiation therapy offers a less invasive means of tumor control, and can be utilized as the initial treatment or as an adjunct in the postoperative setting. The decision to use radiation therapy largely depends on factors, namely neurologic compromise, overall performance, and systemic tumor burden.

Here we present a case of 66 year old male, diagnosed as renal cell carcinoma - clear cell histology. Patient was subjected to radical nephrectomy & subsequently put on '*pazopanib*. While on pazopanib patient developed low back pain, evaluation revealed spinal cord lesion adjacent to L2&3 lumbar vertebrae suggestive of *intradural metastasis*. Patient was treated with external beam radiotherapy (EBRT) after he refused surgery & subsequent evaluation revealed complete disappearance of spinal lesion. Patient is alive & still on follow up.

Key words: *intradural metastasis, renal cell carcinoma, stereotactic body radiotherapy*

1 .Introduction :

Renal cell carcinoma (RCC) is a rare tumor constituting less than 5% of all cancers combined [1,2]. Over one third of these cancers eventually metastasize, with half of them metastasizing

metachronously.[3] Though renal cell carcinoma can metastasize to any site , most common sites involved include lung, bone and lymph-nodes [4].

Spinal '*intradural metastases*' from renal cell carcinoma are extremely rare with only a few case reports reported so far. "Its seen to occur many years from the diagnosis of the primary malignancy, posing problems in differential diagnosis and management thereof. Metastases to the spinal intradural space can occur through the following different routes: hematogenous dissemination, via perineural lymphatics, subarachnoid space, and through direct invasion from nearby anatomical structures" [5,6,7,18]. Because of the scarcity of data regarding *spinal intradural metastasis (extramedullary or intramedullary)* from renal cell carcinoma, there is no unanimous consensus about their best management; the armamentarium at disposition includes surgery, radiotherapy, and chemotherapy, performed in an isolated manner or in combination.

Spinal metastases can impact the quality of life when they are complicated by intractable pain, spinal cord compression with resultant neurological deficits and pathological fractures. Radiotherapy (RT) is a widely used modality in the palliative treatment of spinal metastases.

A study published "in 1996 examined *in-vitro radio-sensitivity* of multiple human cancer cell lines, showing that RCC was relatively radio-resistant to conventionally fractionated radiation therapy" [8]. "However the paradigm of clinical experience has changed with the advent of highly conformal radiotherapy techniques like stereotactic body radiotherapy (SABR) or hypofractionated radiotherapy (HFRT) for both intracranial and extracranial spinal metastases of various origin. These techniques have shown excellent local control (LC) rates exceeding 90%" [9-11]. In this case we also treated a patient with external beam radiation therapy, though with conventional techniques, after he refused any sort of surgical intervention and post treatment images showed complete resolution of spinal lesion which proves role of radiation in treatment of intradural spinal mets.

2.Case report

60 years old male with no comorbidities presented with intermittent painless hematuria of four months duration. Subsequent evaluation with a PET-CT revealed a hypermetabolic exophytic

right renal grade IV *Bosniak* mass lesion arising from upper polar region of kidney and inferior vena cava thrombus suggestive of mitotic lesion in kidney.. Patient underwent right radical nephrectomy with thrombectomy in July 2019.

Histopathology was suggestive of clear cell carcinoma. Patient was prescribed tyrosine kinase inhibitor pazopanib by treating Medical Oncologist which he took from November 2019 upto January 2021. Follow up PET-CTs done in February & September 2020 showed no evidence of metabolically active disease.. Patient presented in February 2021 patient complaints of low back ache radiating to both lower limbs. PET-CT was again done in February 2021 on the advice of Medical Oncologist, which was suggestive of multiple peritoneal deposits indenting into liver and stomach, discrete abdominal, peritoneal & serosal deposits, intradural spinal cord lesion along L2 and L3 vertebrae and adrenal deposits. Patient was advised surgery for the spinal cord lesion which he refused.

Patient then came to our department & we advised him CEMRI of spine for radiological categorization of the lesion. MRI was suggestive of a well defined oval 2.3x1.1x1.0 cm lesion with signal characteristics as *T1 mildly hyperintense* and *T2 iso to hyperintense* showing diffusion restriction and vivid post contrast enhancement at L2 and L3 level (intradural location) suggestive of metastatic deposits. As patient had already refused any sort of surgical intervention we advised him a biopsy of the lesion to rule out any other pathology. Patient refused & we proceeded with the radiological diagnosis after explaining the pros & cons of treating empirically (in view of rarity of intradural metastasis). He was given option of Stereotactic body radiation therapy but patient was reluctant and chose to go for conventional radiotherapy. Patient was treated with External beam radiation therapy to a dose of 20 Gy/5#/1 week, which he completed in March 2021.

Patient was switched over to another tyrosine kinase inhibitor Lenvatinib & mtor inhibitor Evrolimus by treating Medical Oncologist, in view of disease progression.

Patient was lost to follow up since then & reported in October, 2022, to our department where a check CEMRI Spine was done which showed complete resolution of the erstwhile lesion in spine.

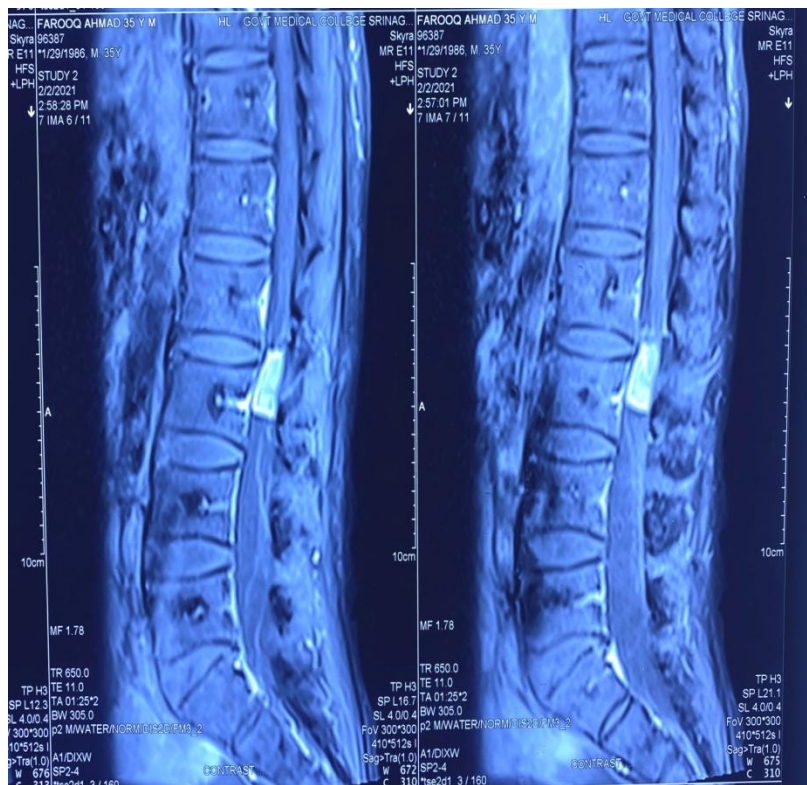


Figure 1

T1 post contrast sagittal images show intradural enhancing lesion at 12-13 level(Pretreatment).

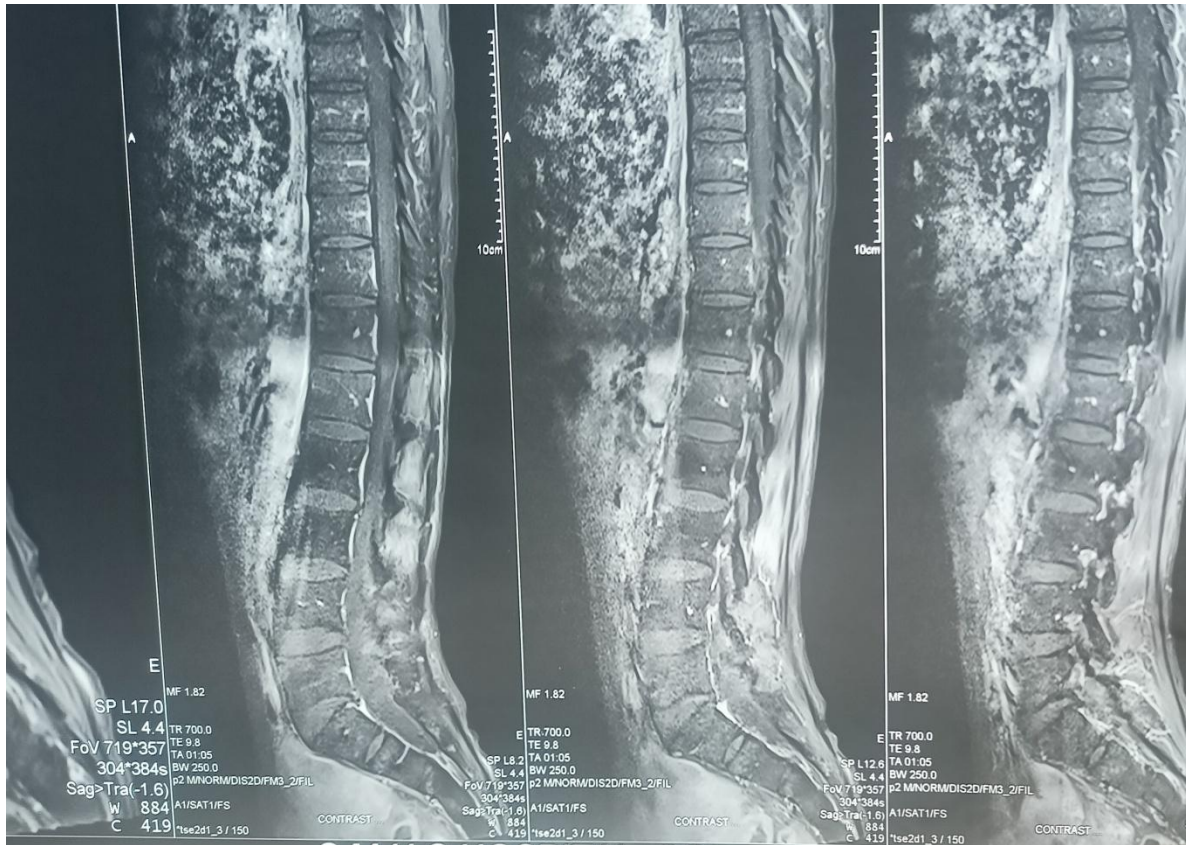


Figure 2

T1 post contrast images shows complete resolution.(post treatment)

3.Discussion:-This report presents a rare case of *IDSM* It constitutes only 5% of all spinal metastasis which as per literature is 5% .[12] “Spinal intradural metastases from renal cell carcinoma is extremely rare and may occur many years from the diagnosis of the primary malignancy, posing problems in differential diagnosis and management” [13]

“Keeping in mind the curative, functional, and palliative aspects; the management should be tailored for each patient. Surgery represents the gold standard of treatment for spinal metastases presenting with acute onset of neurological symptoms, with the aim of arresting the decline of neurological functions, improving clinical symptoms (neurological deficits and/or pain), and preventing new-onset, potentially irreversible neurological deficits through the decompression of neural structures”.[14]

. “However Radiation therapy offers a less invasive means of tumor control, and can be utilized as the initial treatment or as an adjunct in the postoperative setting. The decision to use radiation therapy largely depends on factors, namely neurologic compromise, overall performance, and systemic tumor burden. Unfortunately, there is a paucity of rigorous data regarding radiation treatment for intradural and intramedullary spinal metastases. However, many case studies have advocated the use of radiation for patients with intramedullary spinal cord tumors due to their overall poor prognosis” [15]

There are data to suggest that “hypofractionation radiation therapy decreases the likelihood of retreatment with improved rates of local control” [16]. Newer modern radiation techniques like sbrt have proven to reduce pain and improve local control in case of intradural spinal mets which was proven by a study conducted by Scott g et al[17].

But in our study patient refused sbrt so he was treated by conventional hypofractionation .

4.CONCLUSION:- The treatment of intradural and intramedullary spinal metastases is complex and necessitates a multidisciplinary team for multimodal therapies. Surgery and radiation are the mainstays of treatment, which the few clinical studies available have supported

Radiation is both an established and emerging treatment option in patients with intradural spinal mets who decline surgery or are not a surgical candidate Newer radiation modalities like SBRT are extremely helpful in these clinical situations.

CONSENT.

As per international standard or university standard, patients' written consent has been collected and preserved by the author(s).

ETHICAL APPROVAL As per international standard or university standard written ethical approval has been collected and preserved by the author(s).

REFERENCES:-

- 1 Sandeep Anand Padala, Adam Barsouk, Krishna Chaitanya Thandra, Kalyan Saginala Azeem MohammedAnusha Vakiti,Prashanth Rawla, and Alexander Barsouk Epidemiology of Renal Cell CarcinomaWorld J Oncol. 2020 Jun; 11(3): 79–87.
2. Lipworth L, Morgans AK, Edwards TL, et al. Renal cell cancer histological subtype distribution differs by race and sex. British journal of urology International 2016;117: pp260–5.
3. Dabestani, S.; Thorstenson, A.; Lindblad, P.; Harmenberg, U.; Ljungberg, B.; Lundstam, S. Renal cell carcinoma recurrences and metastases in primary non-metastatic patients: A population-based study. World journal Urology. 2016, 34, pp1081–1086
4. Bianchi, M.; Sun, M.; Jeldres, C.; Shariat, S.F.; Trinh, Q.D.; Briganti, A.; Tian, Z.; Schmitges, J.; Graefen, M.; Perrotte, P.; et al. Distribution of metastatic sites in renal cell carcinoma: A population-based analysis. Annals. Oncology. 2012, 23, pp 973–980.
- 5.Mak, K.H.; Kwok, J.C. Intradural spinal metastasis from renal cell carcinoma: A case report. J. Orthopaedic Surgery journal. 2001, 9, pp57–61.
6. Kim, D.Y.; Lee, J.K.; Moon, S.J.; Kim, S.C.; Kim, C.S. Intradural spinal metastasis to the cauda equina in renal cell carcinoma: A case report and review of the literature. Spine 2009, 34, E892–E895. apy
- 7.Mosdal, C.; Bang, F. Intradural spinal metastases. ActaNeurochirurgica. 1981, 56, pp107–110.
8. Deschavanne, P.J.; Fertil, B. A review of human cell radiosensitivity in vitro. International. Journal. Radiation. Oncology. 1996, 34,pp 251–266
- 9.Marion Tonneau,Raphaëlle Mouttet Audouard,Florence Le Tinier, Xavier Mirabel and David Pasquier .Stereotactic body radiotherapy for intamedullary metastatis: a retrospective series at the Oscar lambert centre and a systematic review,british Medical journal 2021 ,,pp1168.

10. Matthias Guckenberger, MD,* Max Dahele, MBChB, PhD,y Wee Loon Ong, MBBS,z,x anArjun Sahgal, MD. Stereotactic Body Radiation Therapy for Spinal Metastases: BenefitsandLimitationsSeminars in Radiation OncologyVolume 33, Issue 2, April 2023, Pages 159-171

11 .Zeleftsky, M.J.; Greco, C.; Motzer, R.; Magsanoc, J.M.; Pei, X.; Lovelock, M.; Mechalakos, J.; Zatsky, J.; Fuks, Z.; Yamada, Y. Tumor Control Outcomes After Hypofractionated and Single-Dose Stereotactic Image-Guided Intensity-Modulated Radiotherapy for Extracranial Metastases From Renal Cell Carcinoma. International Journal Radiation Oncology. 2012, 82, pp1744–1748.

12. Perrin RG,LivingstonKE,Aarabi B.,intraduralextramedullary spinal metastasis ,Neurosurgery Rev 2001; 24, pp1-5.

13 Carminucci A, Hanft S. Intradural extramedullary spinal metastasis of renal cell carcinoma: illustrative case report and comprehensive review of the literature. Eur Spine J. 2020 Dec;29 (Suppl 2):176-182

14 . Hassan O, Gassie K, Goyal A, Foskey S, Abode-Iyamah K. Clinical Features and Neurosurgical Management of Metastatic Intradural Extramedullary Renal Cell Carcinoma. Cureus. 2023 Jan 10;15,

15 Winkelman MD, Adelstein DJ, Karlins NL. Intramedullary spinal cord metastasis. Diagnostic and therapeutic considerations. Arch Neurol. 1987;44(5):526–31. .

16 Howell DD, James JL, Hartsell WF, Suntharalingam M, Machtay M, Suh JH, Demas WF, Sandler HM, Kachnic LA, Berk LB. Single-fraction radiotherapy versus multifraction radiotherapy for palliation of painful vertebral bone metastases-equivalent efficacy, less toxicity, more convenient: a subset analysis of radiation therapy oncology group trial 97-14. Cancer. 2013;119(4):888

17G. Soltys MD , Jimm Grimm PhD MichaelT. Milano MD,PhD , Jinyu Xue PhD ,Arjun Sahgal MD , Ellen Yorke PhD , Yoshiya Yamada MD , George X. Ding PhD , XAllen Li PhD'D Stereotactic Body Radiation Therapy for Spinal Metastases: Tumor Control Probability Analysesand Recommended Reporting Standards. International Journal of Radiation OncologyBiologyPhysics.Volume 110, Issue 1, 1 May 2021, Pages 112-123.

18. Corvino S, Mariniello G, Solari D, Berardinelli J, Maiuri F. The Role of Surgery in Spinal Intradural Metastases from Renal Cell Carcinoma: A Literature Review. Cancers. 2022 Mar 21;14(6):1595.

UNDER PEER REVIEW