

Intradural Spinal metastasis from Renal cell carcinoma- A rare entity.

ABSTRACT:

Renal cell carcinoma constitutes about 2% of all malignant neoplasms . It is known to metastasize to lung, bone and lymph nodes; intradural spinal metastases(IDSM) are relatively uncommon, only 5% as per literature.

Here we present a case of 66 year old male, diagnosed as renal cell carcinoma - clear cell histology. Patient was subjected to radical nephrectomy & subsequently put on 'pazopanib. While on pazopanib patient developed low back pain, evaluation revealed spinal cord lesion adjacent to L2&3 lumbar vertebrae suggestive of *intradural metastasis*. Patient was treated with external beam radiotherapy (EBRT) & subsequent evaluation revealed complete disappearance of spinal lesion. Patient is alive & still on follow up.

Key words: *intradural metastasis, renal cell carcinoma, stereotactic body radiotherapy*

1 .Introduction :

Renal cell carcinoma (RCC) is a rare tumor constituting less than 5% of all cancers combined [1,2]. Over one third of these cancers eventually metastasize, with half of them metastasizing metachronously.[3] Though renal cell carcinoma can metastasize to any site , most common sites involved include lung, bone and lymph-nodes [4].

Spinal '*intradural metastases*' are extremely rare with only a few case reports reported so far. Its seen to occur many years from the diagnosis of the primary malignancy, posing problems in differential diagnosis and management thereof. Metastases to the spinal intradural space can

occur through the following different routes: hematogenous dissemination, via perineural lymphatics, subarachnoid space, and through direct invasion from nearby anatomical structures [5,6,7]. Because of the scarcity of data regarding *spinal intradural metastasis (extramedullary or intramedullary)* from renal cell carcinoma, there is no unanimous consensus about their best management; the armamentarium at disposition includes surgery, radiotherapy, and chemotherapy, performed in an isolated manner or in combination.

Spinal metastases can impact the quality of life when they are complicated by intractable pain, spinal cord compression with resultant neurological deficits and pathological fractures. Radiotherapy (RT) is a widely used modality in the palliative treatment of spinal metastases.

A study published in 1996 examined *in-vitro radio-sensitivity* of multiple human cancer cell lines, showing that RCC was relatively radio-resistant to conventionally fractionated radiation therapy [8]. However the paradigm of clinical experience has changed with the advent of highly conformal radiotherapy techniques like stereotactic body radiotherapy (SABR) or hypofractionated radiotherapy (HFRT) for both intracranial and extracranial spinal metastases of various origin. These techniques have shown excellent local control (LC) rates exceeding 90% [9-11]. In this case we also treated a patient with radiation therapy, though with conventional techniques, after he refused any sort of surgical intervention.

2. Case report

60 years old male with no comorbidities presented with intermittent painless hematuria of four months duration. Subsequent evaluation with a PET-CT revealed a hypermetabolic exophytic right renal grade IV *Bosnaik* mass lesion arising from upper polar region and inferior vena cava thrombus suggestive of primary mitotic pathology. Patient underwent right radical nephrectomy with thrombectomy in July 2019.

Histopathology was suggestive of clear cell carcinoma. Patient was put on *pazopanib* by treating Medical Oncologist which he took from November 2019 upto January 2021. Follow up PET-CTs done in February & September 2020 were normal. Patient presented in February 2021

patient complaints of low back ache radiating to both lower limbs. PET-CT was again done in February 2021 on the advice of Medical Oncologist, which was suggestive of multiple peritoneal deposits indenting into liver and stomach, discrete abdominal, peritoneal & serosal deposits, intradural spinal cord lesion along L2 and L3 vertebrae and adrenal deposits. Patient was advised surgery for the spinal cord lesion which he refused.

Patient reported to our department & we advised him CEMRI of spine for radiological categorization of the lesion. MRI was suggestive of a well defined oval 2.3x1.1x1.0 cm lesion with signal characteristics as *T1 mildly hyperintense* and *T2 iso to hyperintense* showing diffusion restriction and vivid post contrast enhancement at L2 and L3 level (intradural location) suggestive of metastatic deposits. As patient had already refused any sort of surgical intervention we advised him a biopsy of the lesion to rule out any other pathology. Patient refused & we proceeded with the radiological diagnosis after explaining the pros & cons of treating empirically (in view of rarity of intradural metastasis). He was given option of SBRT but patient was reluctant and chose to go for conventional radiotherapy. Patient was treated with EBRT to a dose of 20 Gy/5#/1 week, which he completed in March 2021.

Patient was switched over to Lenvatinib & Evrolimus by treating Medical Oncologist, in view of disease progression.

Patient was lost to follow up since then & reported in October, 2022, when a check CEMRI Spine was done which showed complete resolution of the erstwhile lesion in spine.

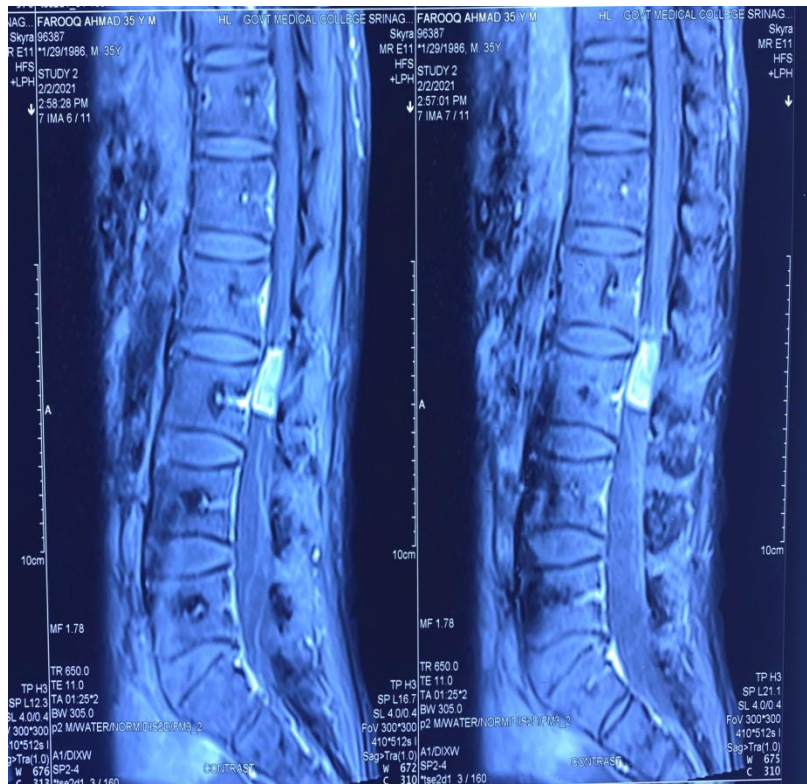


Figure 1

T1 post contrast sagittal images show intradural enhancing lesion at 12-13 level(Pretreatment).

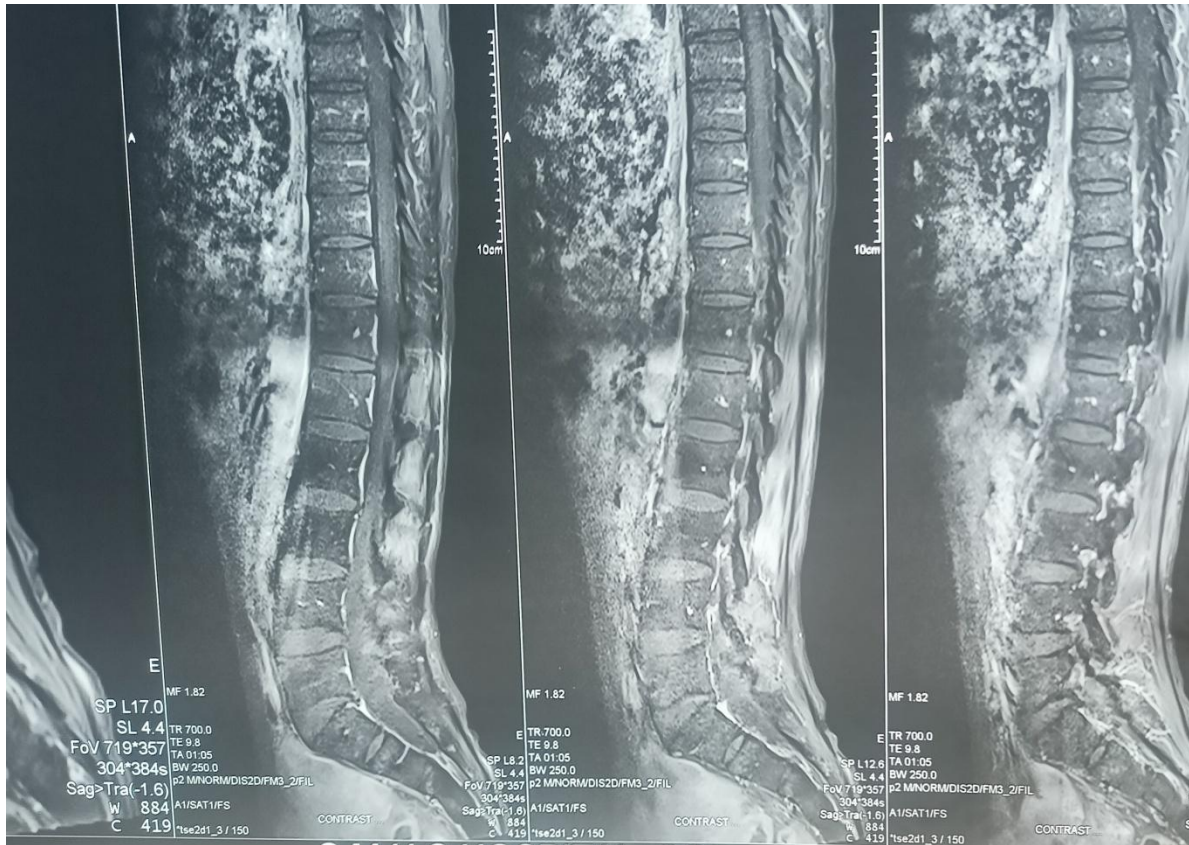


Figure 2

T1 post contrast images shows complete resolution.(post treatment)

3. Discussion:- This report presents a rare case of *IDSM*. It constitutes only 5% of all spinal metastasis which as per literature is 5% .[12]Spinal intradural metastases from RCC is extremely rare and may occur many years from the diagnosis of the primary malignancy, posing problems in differential diagnosis and management.

Keeping in mind the curative, functional, and palliative aspects; the management should be tailored for each patient. Surgery represents the gold standard of treatment for spinal metastases presenting with acute onset of neurological symptoms, with the aim of arresting the decline of neurological functions, improving clinical symptoms (neurological deficits and/or pain), and preventing new-onset, potentially irreversible neurological deficits through the decompression of neural structures.

In addition to surgery and systemic therapy, radiation therapy is a promising treatment modality for RCC, although it was traditionally thought to be radio-resistant

4. **CONCLUSION** :- Intradural spinal metastasis is a rare clinical entity. EBRT is both an established and emerging treatment option in those patients who decline surgery or are not a surgical candidate. Newer radiation modalities like SBRT are extremely helpful in these clinical situations. It facilitates dose escalation to the target area with minimal radiation to the nearby critical structures.

CONSENT.

As per international standard or university standard, patients' written consent has been collected and preserved by the author(s).

ETHICAL APPROVAL As per international standard or university standard written ethical approval has been collected and preserved by the author(s).

REFERENCES :-

1. Graves A, Hessamodini H, Wong G, et al. Metastatic renal cell carcinoma: update on epidemiology, genetics, and therapeutic modalities. *Immunotargets Therapy* 2013;2:pp73–90.
2. Lipworth L, Morgans AK, Edwards TL, et al. Renal cell cancer histological subtype distribution differs by race and sex. *British journal of urology International* 2016;117: pp260–5.
3. Dabestani, S.; Thorstenson, A.; Lindblad, P.; Harmenberg, U.; Ljungberg, B.; Lundstam, S. Renal cell carcinoma recurrences and metastases in primary non-metastatic patients: A population-based study. *World journal Urology*. 2016, 34, pp1081–1086
4. Bianchi, M.; Sun, M.; Jeldres, C.; Shariat, S.F.; Trinh, Q.D.; Briganti, A.; Tian, Z.; Schmitges, J.; Graefen, M.; Perrotte, P.; et al. Distribution of metastatic sites in renal cell carcinoma: A population-based analysis. *Annals. Oncology*. 2012, 23, pp 973–980.
5. Mak, K.H.; Kwok, J.C. Intradural spinal metastasis from renal cell carcinoma: A case report. *J. Orthopaedic Surgery journal*. 2001, 9, pp57–61.
6. Kim, D.Y.; Lee, J.K.; Moon, S.J.; Kim, S.C.; Kim, C.S. Intradural spinal metastasis to the cauda equina in renal cell carcinoma: A case report and review of the literature. *Spine* 2009, 34, E892–E895. apy
7. Mosdal, C.; Bang, F. Intradural spinal metastases. *Acta Neurochirurgica*. 1981, 56, pp107–110.

8. Deschavanne, P.J.; Fertil, B. A review of human cell radiosensitivity in vitro. *International Journal. Radiation. Oncology.* 1996, 34,pp 251–266
9. Wersäll, P.J.; Blomgren, H.; Lax, I.; Kälkner, K.-M.; Linder, C.; Lundell, G.; Nilsson, B.; Nilsson, S.; Näslund, I.; Pisa, P.; et al. Extracranial stereotactic radiotherapy for primary and metastatic renal cell carcinoma. *Radiotherapy. Oncology.* 2005, 77, pp 88–95.
10. Svedman, C.; Sandström, P.; Pisa, P.; Blomgren, H.; Lax, I.; Kälkner, K.-M.; Nilsson, S.; Wersäll, P. A prospective Phase II trial of using extracranial stereotactic radiotherapy in primary and metastatic renal cell carcinoma. *Acta Oncology.* 2006, 45,pp 870–875.
11. Zelefsky, M.J.; Greco, C.; Motzer, R.; Magsanoc, J.M.; Pei, X.; Lovelock, M.; Mechalakos, J.; Zatzky, J.; Fuks, Z.; Yamada, Y. Tumor Control Outcomes After Hypofractionated and Single-Dose Stereotactic Image-Guided Intensity-Modulated Radiotherapy for Extracranial Metastases From Renal Cell Carcinoma. *International Journal Radiation Oncology.* 2012, 82, pp1744–1748.
12. Perrin RG, Livingston KE, Aarabi B., intradural extramedullary spinal metastasis, *Neurosurgery Rev* 2001; 24, pp1-5.

UNDER