

Case report

Malignant melanoma metastasis to bone marrow : a rare case report

Abstract:

Malignant melanoma is an aggressive neoplasm, its metastasis to bone marrow is rare phenomenon. Here, we are presenting a case of metastatic malignant melanoma to bone marrow with unknown primary in 40 years old patient along with review of literature. This case is diagnosed as metastatic malignant melanoma in bone marrow aspirate and biopsy specimen first. Diagnosis was done on the basis of classical histological features and with the help of immunohistochemistry . After that, other investigations including radiological investigations were done to know primary site. After radiological investigations, Multiple metastasis including in liver and vertebra also identified in this patient. USG guided fine needle aspiration cytology of liver and biopsy of vertebral lesion were also performed, which confirms the diagnosis of malignant melanoma metastasis. In our case, patient died within one month after diagnosis. Early diagnosis of metastatic melanoma will help clinicians to better understanding of course of disease, so they can provide best possible patient care and management .

Keywords : Malignant melanoma, metastasis, bone marrow, HMB45

Introduction:

Malignant melanoma is an aggressive neoplasm, which holds to be 1-3% of all malignancies and represents 1% of skin malignancies. Involvement of bone marrow has been seen in many non hematological malignancies and is

believed to be an independent poor prognostic factor. Despite its propensity for distant metastases, metastasis of melanoma to bone marrow is even rarer and accounts for 5-7% of all malignant cases [1]. Draining lymph nodes are primary metastatic site for malignant melanoma, however it ultimately metastasizes to distant visceral sites. Most frequently involved organ through distant metastasis is lung followed by brain, liver, bone marrow and intestine [2]. Adjacent skin can also get involved occasionally. 5-15% of malignant melanoma cases are diagnosed without any known primary tumour, in these cases it was presumed that primary tumour has been subsided [3-5]. In literature, there are many case reports of metastatic malignant melanomas with known primary site are registered, but without that is very rare [6-8].

Here, we report a rare case of metastatic malignant melanoma to bone marrow with unknown primary in 40 years old patient along with review of literature. This case is diagnosed as metastatic malignant melanoma in bone marrow aspirate and biopsy specimen first. After that, other investigations including radiological investigations were done to know primary site. After radiology, Multiple metastasis including in liver and vertebra also identified in this patient. USG guided fine needle aspiration cytology of liver and biopsy of vertebral lesion were also performed, which confirms the diagnosis of malignant melanoma metastasis.

Case Presentation:

A 40 years old male presented in medicine outdoor with clinical history of pain in chest and back for 6 months and for that he has taken local treatment. On examination, patient was febrile, pale, ill looking without any lymphadenopathy. Symptomatic treatment was given to patient and advised for blood examinations.

Hematological examination revealed severe anemia and thrombocytopenia. Complete hemogram findings were as follows; haemoglobin 7.4gm/ dl, white blood cells $6.03 \times 10^3 / \mu\text{L}$ and platelets $50 \times 10^3 / \mu\text{L}$. Peripheral blood smear shows leukoerythroblastic blood picture. RBCs shows reduced RBC density, mild anisopoikilocytosis with presence of microcytes, tear drop cells and few nucleated RBCs (2/100 WBCs) . Mild left shift with differential of 06% myelocytes, 10% metamyelocytes, 67% polymorphs, 12% lymphocytes, 2%

monocytes, 3% eosinophils. Platelets were reduced on blood smear. Patient did not respond to hematinics and cytopenias worsened over time.

Bone marrow aspiration yielded no particles, but trails were cellular and showed infiltration of atypical cells replacing the normal marrow elements. These atypical cells were arranged in small clusters as well as scattered singly. These abnormal cells are large having round to mildly irregular nuclei with coarse chromatin, one to two prominent macronucleoli and moderate amount of cytoplasm. Cytoplasm having coarse clump of black pigment and vacuolations [Fig. 1]. Occasional interspersed erythroid and myeloid precursors were present. But no megakaryocytes were seen. Infiltration by pigmented atypical cells in bone marrow favouring metastatic malignant melanoma was conveyed. Trepine biopsy showed marked suppression of normal hematopoietic elements and are replaced by diffuse infiltrate of pleomorphic, loosely cohesive malignant cells having vesicular nuclear chromatin and distinct nucleoli. Cytoplasm shows coarse black pigment in tumour cells obscuring the nuclear morphology [Fig 2-3]. IHC staining on trephine biopsy showed that tumour cells positive for HMB 45 [Fig. 4]. Definitive report of bone marrow metastasis of malignant melanoma was given with a advice to look for primary site.

Ultrasonography of thorax shows an ill defined heterogeneously echogenic lesion with internal hypoechos area at left part of sternum at 2- 4 intercostal space intending into anterior mediastinum, abutting the arch of aorta with peripheral vascularity of approx size 2x 3.6cm. Features suggestive of metastatic lesion in mediastinum. CECT thorax-abdomen-pelvis shows a well defined hyper and hypodense lesion in bilateral lobes of liver size 3.3x 3.4x3.5 cm. Heterogeneous enhancing infiltrating paraspinal and retroperitoneal mass of size 4.6x 6.0x 8 cm. This mass infiltrates right psoas muscle abutting right renal vein and artery. Multiple lytic lesion in all vertebral bodies, iliac bones, sacrum, coccyx, multiple ribs suggestive of metastasis. USG guided FNA from liver mass shows atypical cells scattered singly and small clusters. These atypical cells show moderate nuclear pleomorphism, hyperchromatic nuclei, prominent 1-2 nucleoli and variable amount of cytoplasm. Background shows benign hepatocytes. Cytomorphological features were suspicion for malignant pathology. USG guided biopsy from liver and paraspinal mass also performed.

Histopathology of which showed pigmented cells arranged in nests and scattered singly. Cells having high N:C ratio, prominent eosinophilic nucleoli and moderate amount of cytoplasm. Some cells show dense pigmentation obscuring the nuclear details.

Tumour markers and serological markers were within normal limits. LDH was markedly raised.

While investigating patient, no previous history of skin lesion or surgery was done. No past exposure to UV light, organic dye or occupational history found. Lastly no primary site could be identified and refer for chemotherapy. During follow up, patient died within one month due to multiple metastasis and late presentation to this hospital.

Discussion:

Malignant melanoma is a malignant tumor originating mostly from melanocytes present in skin and other pigmented cells. It can also occur in mucous membrane, eyes, ears, gastrointestinal tract and leptomeninges. Bone marrow infiltration by malignant melanoma cells are reported in approximately 5-7% of the patients; including approximately 45% cases those are reported on autopsy as an evidence of metastasis [9]. There were male predominance in most of the reported cases. In hematological investigations Anemia was the most common finding noted followed by pancytopenia and thrombocytopenia. Leukoerythroblastic blood picture is also observed in most of the cases. In many case reports, patient lost the follow up or died despite taking chemotherapy. In our case, patient also expired due to advanced disease and multiple metastasis. Savage et al.[10] gave an account of total 97 cases of malignant melanoma, out of which they reported 5.4% cases show marrow involvement. Spiller et al. [11] described a rare case of metastatic malignant melanoma with giant congenital nevus in a child. However, primary locus was not showing any histological features suggesting malignant transformation in nevus [7-8]. Bhagwati N et al. [8] discussed a case where patient had history of exposure to UV light along with organic dyes since childhood. In our case we didn't get any past history of any exposure or organic dyes. Usually most of the patients present with history of lymphadenopathy; but our patient had no lymphadenopathy. De Wolff et al.

[12] described a case of malignant melanoma presented with extreme leucocytosis , however our patient complete hemogram showed bicytopenia and leukoerythroblastic blood picture.

Bone marrow involvement mostly presents with pancytopenia but our patient had normal white blood cell count with mild left shift. In melanoma patient , primary site might get regressed over an extent of time. In melanoma, partial regression is commonly observed than complete regression . 5-15% cases of metastatic melanoma present with unknown primary. In many of these cases either primary tumor has regressed completely or primary tumor would be in the internal organs. Often amelanotic variant of malignant melanoma metastasizes to bone marrow and cause disseminated disease [13]. But in our case the conclusion is straightforward as tumour cells or macrophages having melanin pigment. On the other side, differential diagnosis of amelanotic melanoma includes tumors like poorly differentiated carcinoma, lymphoma, and small round cell tumours. Spindle cell melanomas are also there, which are comprising of spindle shaped cells. On morphological basis, it is challenging to do a definite diagnosis without help of IHC markers. Immunohistochemistry study is beneficial in confirming diagnosis of malignant melanoma. IHC markers mostly comes positive in melanoma are microphthalmia transcription factor, tyrosinase, S-100, HMB-45, vimentin and melan –A [14]. Out of these many markers HMB-45 is definitive marker of melanoma [15]. Definitive diagnosis of our case is done by its histomorphology along with immunohistochemistry.

Conclusion:

Bone marrow involvement by malignant melanoma is rare but without any primary site evident is much a rarer entity. Early diagnosis and treatment of malignant melanoma is necessary to provide better patient care, treatment and prognosis. It is very necessary for clinicians that they should aware of progression of disease, clinical manifestations of distant and metastatic malignant melanoma. So that they can order proper investigations for early definitive diagnosis and proper management.

References:

1. Rigel DS, Friedman RJ, Kopf AW: The incidence of malignant melanoma in the United States: issues as we approach the 21st century. *J Am Acad Dermatol* 1996, 34:839-847.
2. de la Monte SM, Moore GW, Hutchins GM: Patterned distribution of metastases from malignant melanoma in humans. *Cancer Res* 1983, 43(7):3427-33.
3. Anbari KK, Schuchter LM, Bucky LP, Mick R, Synnestvedt M, Guerry D, Hamilton R, Halpern AC: Melanoma of unknown primary site: presentation, treatment, and prognosis – a single institution study. University of Pennsylvania Pigmented Lesion Study Group. *Cancer* 79(9):1816-21. 1997 May 1
4. Baab GH, McBride CM: Malignant melanoma: the patient with an unknown site of primary origin. *Arch Surg* 1975, 110(8)
5. Chang P, Knapper WH: Metastatic melanoma of unknown primary. *Cancer* 49(6):1106-11. 1982 Mar 15
6. Brown D, Boniuk M, Font RL: Diffuse malignant melanoma of iris with metastases. *Surv Ophthalmol* 1990, 34(5)
7. Tuncer I, Paydas S, Cosar EF, Ersöz C: Metastatic malignant melanoma in bone marrow: importance of aspiration cytology. *Turkish Journal of Cancer* 1994, 24:168- 170.
8. Bhagwati N, Seno R, Dutcher JP, Oleksowicz L: Fulminant metastatic melanoma complicated by a microangiopathic hemolytic anemia. *Hematopathol Mol Hematol* 1998, 11(2):101-8.
9. Serrier C, Lesesve J-F. Metastatic malignant melanoma in the bone marrow. *Blood* 2013;121:721.10.1182/blood-2012-09-454546
10. Savage RA, Lucas FV, Hoffman GC: Melanoma in marrow aspirates. *Am J Clin Pathol* 1983, 79:268-269 10.1093/ajcp/79.2.268

11. Spiller SE, Hawkins DS, Finn LS, Sze RW, Sybert V: Metastatic malignant melanoma presenting as pancytopenia in a three year-old boy. *Pediatr Blood Cancer* 2005, 45(1):60-3.
12. de Wolff JF, Planken EV, den Ottolander GJ: Extreme leucocytosis and splenomegaly in metastasised melanoma. *Neth J Med* 2004, 62(5):164-7.
13. Villarrubia J, de Misa RF, Escribano L, Bellas C, Velasco JL: Amelanotic bone marrow infiltration secondary to pigmented malignant melanoma. *J Dermatol* 1995, 22:620-2.
14. Yaziji H, Gown AM: Immunohistochemical markers of melanocytic tumors. *Int J Surg Pathol* 2003, 11(1):11-5.
15. Bacchi CE, Bonetti F, Pea M, Martignoni G, Gown AM: HMB-45: a review. *Appl Immunohistochem* 1996, 4:73-85.

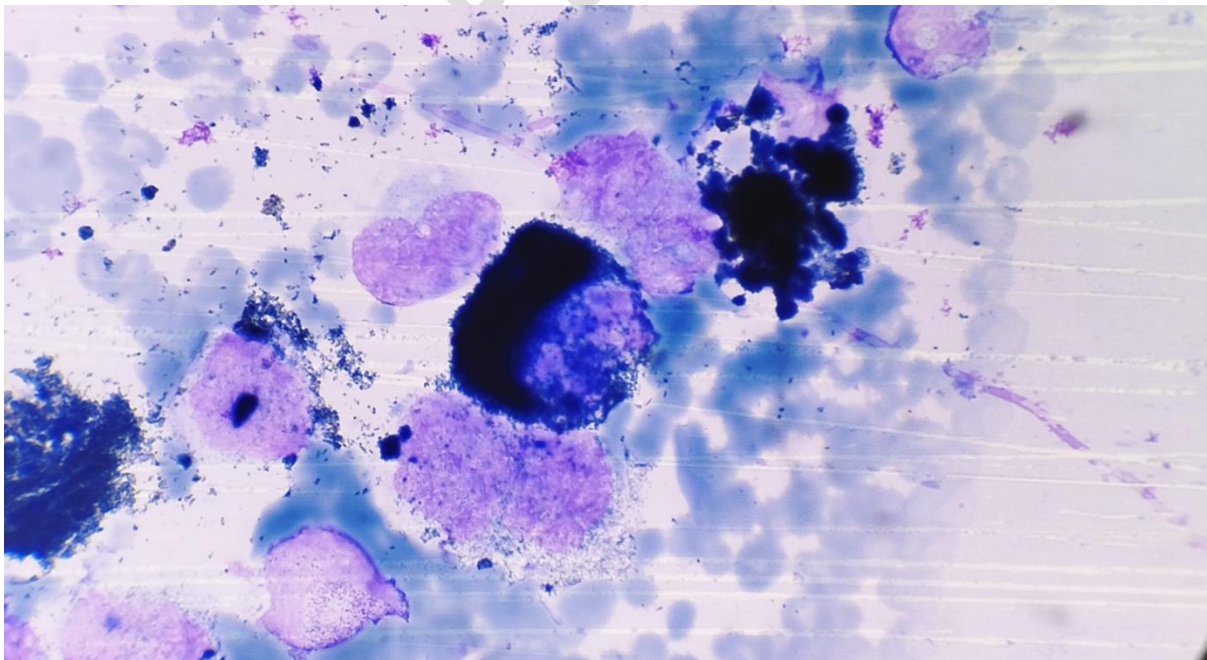


Figure 1: Bone marrow aspiration shows presence of pigmented large cells (40x)

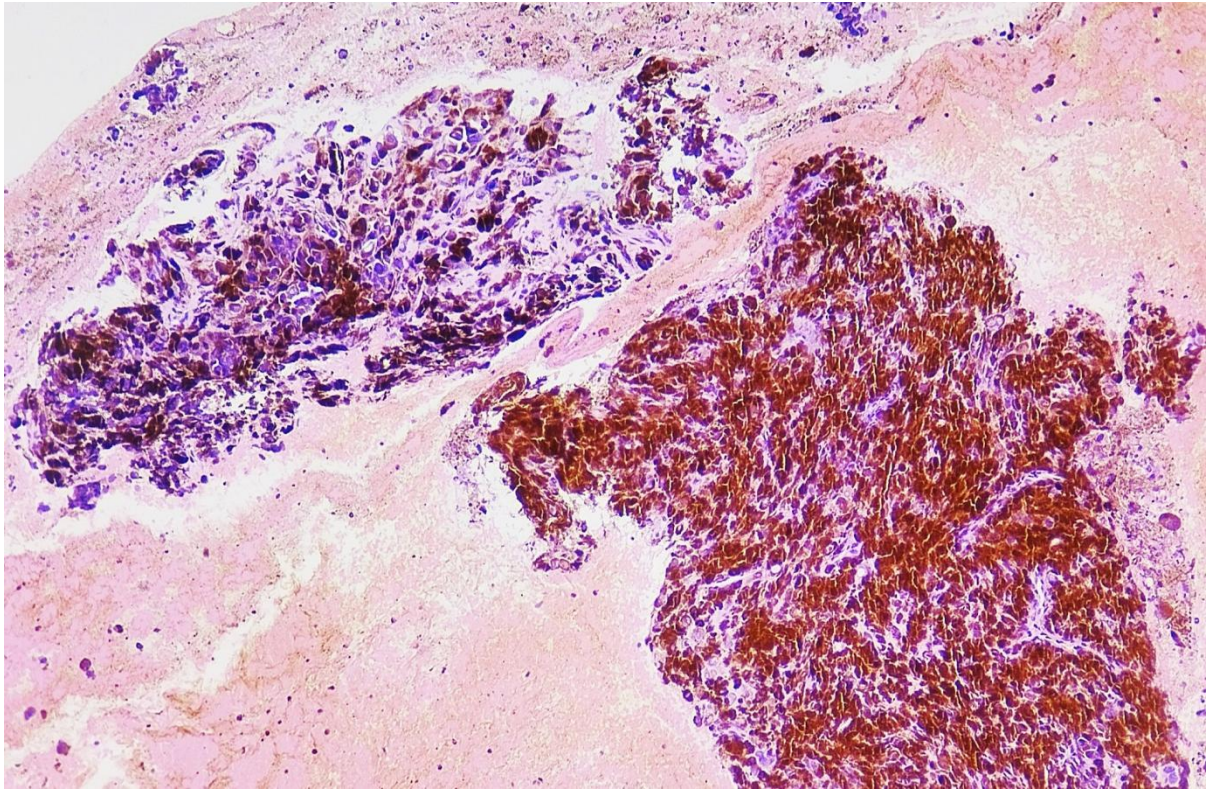


Figure 2: Bone marrow biopsy shows sheets and nests of pigmented large cells replacing hematopoietic elements (10x)

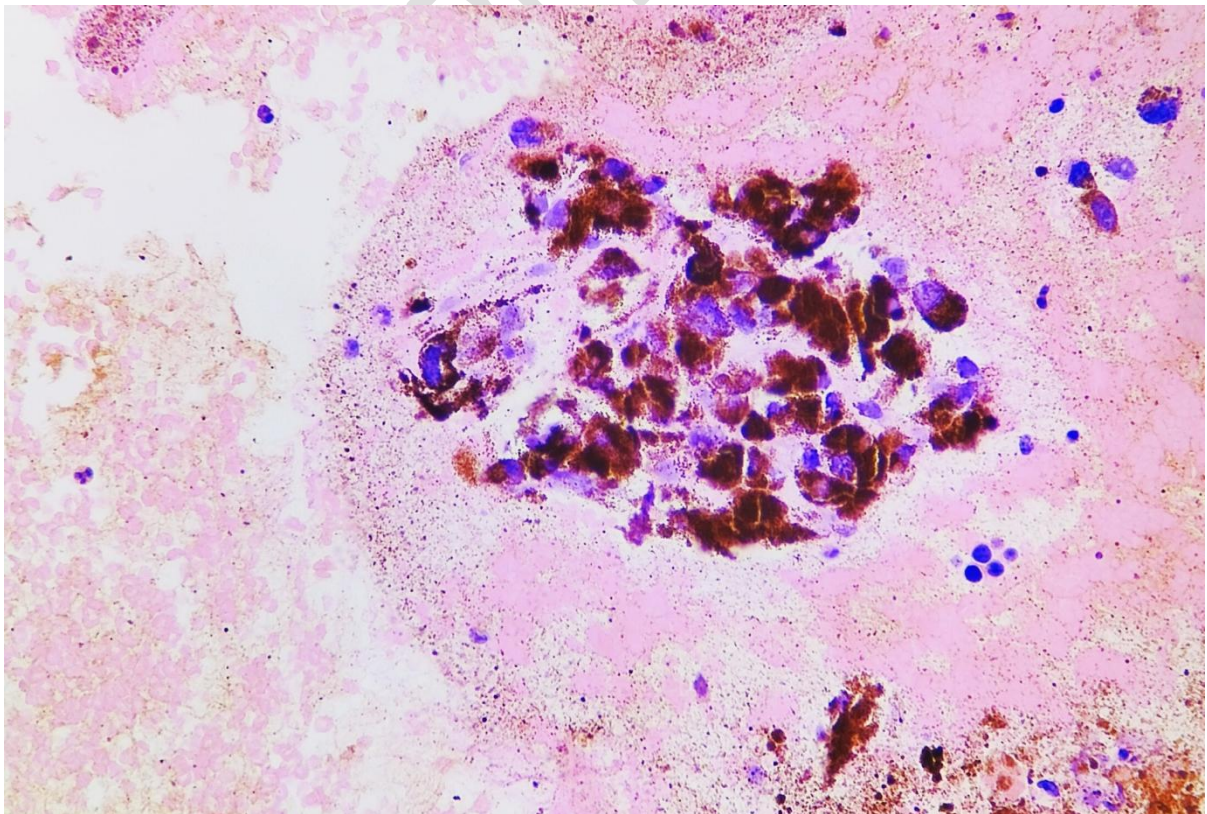


Figure 3: Bone marrow biopsy shows clusters of large pigmented cells (40x)

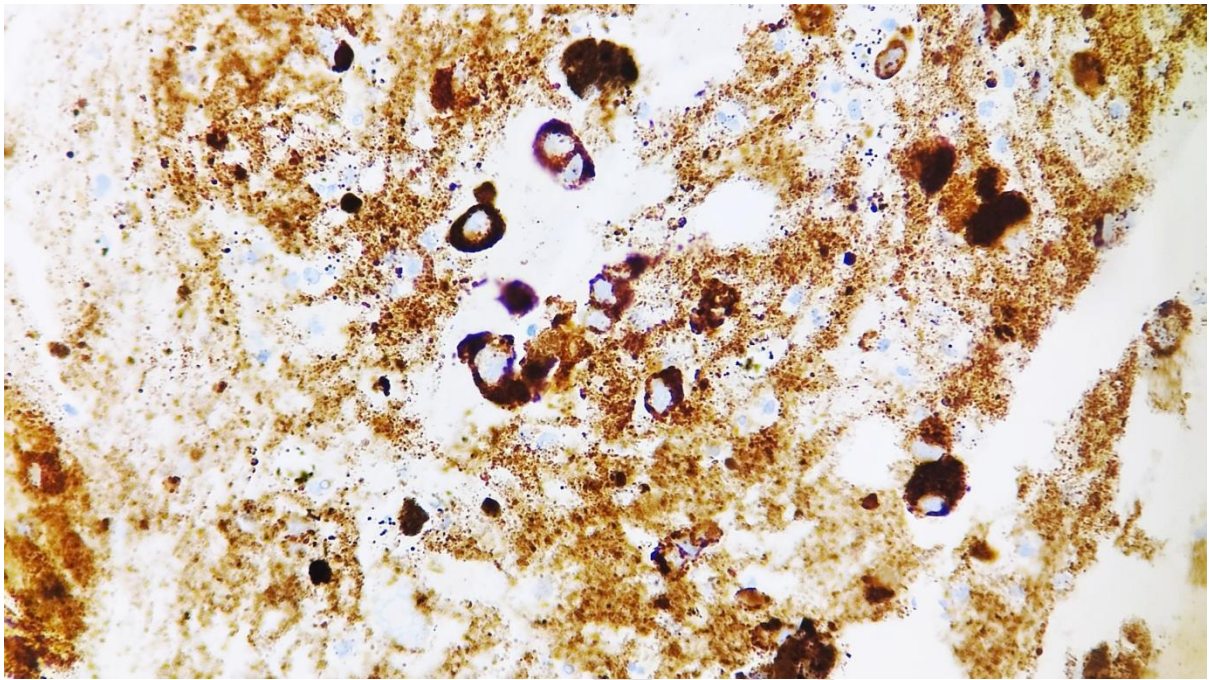


Figure 4: Pigmented cells show strong positivity for HMB45 (40x)

UNDER PEER REVIEW