

Primary Mucinous Adenocarcinoma of Renal Pelvis- A diagnostic dilemma

Abstract

Introduction:

Primary mucinous adenocarcinoma of the renal pelvis is extremely rare, with only ~100 cases reported till now. Its pathophysiology is thought to comprise glandular metaplasia of the urothelium of the calyces and pelvis, as well as malignant transformation of the metaplasia. Unfortunately, there are no distinguishing symptoms or radiological characteristics.

Case presentation:

A 75-year-old man presented with pain in his left flank and intermittent fever. A physical examination showed swelling in left flank on inspection which was soft, non-tender, and ballotable with no local rise of temperature. The results of most laboratory tests were within normal limits. Plain radiography of the kidneys, ureter, and urinary bladder showed a large radio-opaque mass in the left kidney. Abdominal computed tomography showed left kidney measuring 24.8 x 12.4 cm with gross hydronephrosis with severe cortical thinning with large calculus of 2.7 X 3.1 x 3.6cm in left pelviureteric junction. Diuretic-enhanced 99mTc DTPA renal scanning showed that the relative function of the left versus the right kidney was 11.19 versus 88.81 %. On the basis of the imaging findings, kidney dysfunction due to ureteropelvic junction stenosis with a large stone was initially diagnosed.

Although the cytopathology of gelatinous material was negative for malignancy, we could not rule out other disease, such as hidden malignancies of the kidney. As a result, we did a radical nephrectomy, and pathological investigation of the kidney revealed a mucinous adenocarcinoma in the renal pelvis. A bone scan and positron emission tomography revealed no additional malignancies, metastases, or remnant cancer.

Conclusions:

Primary mucinous adenocarcinomas of the renal pelvis are extremely rare, and the majority are discovered by post-operative examination of resected specimens. Despite the difficulty of preoperative diagnosis, urologists should evaluate the possibility of primary mucinous adenocarcinoma in patients with severe hydronephrosis, renal stones, and chronic inflammation.

Keywords: mucinous adenocarcinoma, metaplasia, pathophysiology

Introduction:

“Adenocarcinomas of the renal pelvis are rare and are classified as tubulovillous, mucinous, or papillary non-intestinal” [12].

Primary mucinous adenocarcinoma of the renal pelvis, first described in 1960 by Hasebe et al., is especially rare.

Unfortunately, it is difficult to diagnose preoperatively because there are no characteristic symptoms or laboratory and radiological findings.

Case Presentation:

- 75 years old male, resident of Shimoga, came with chief complaints of pain in abdomen since 2 years and intermittent fever since 1 week,
- No other abdominal or urinary complaints, No history of any surgery in the past. No comorbidities
- Known smoker and alcoholic for last 15 years.
- General examination – normal
- Genital examination – normal
- P/A examination:

Approximately 20 cm mass present in left flank and lumbar area.

Soft in consistency, ballotable, non-tender and no local rise of temperature.

All other quadrants were normal.

- Most laboratory tests were within normal limits except TLC counts of $14,000\text{cc}/\text{mm}^3$, creatinine - $2.2\text{mg}/\text{dl}$.

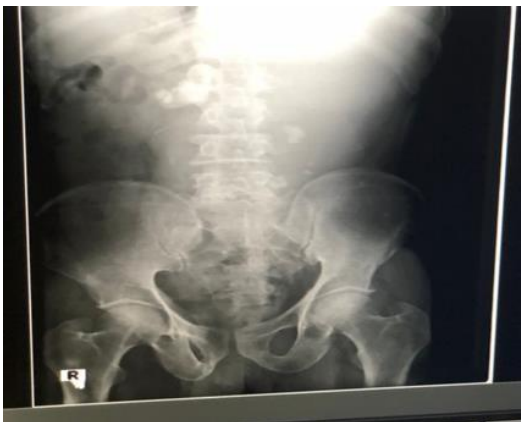

Figure 1: X-ray KUB showing left renal calculus

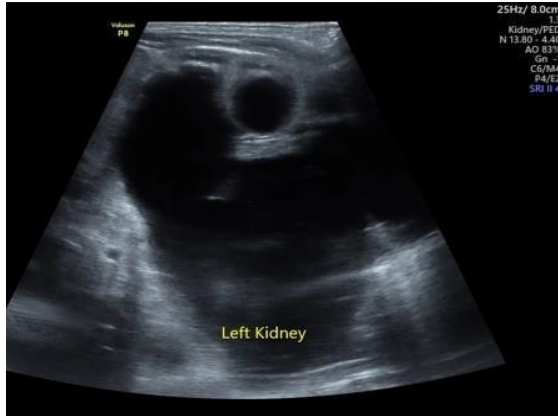

Figure 2: USG kub showing left gross Hun

NCCT KUB:

- Left kidney measuring 24.8 X 12.4 cm with gross HUN causing renal parenchymal thinning measuring 2 mm in upper, mid and lower pole. Corticomedullary differentiation is indistinct.
- large calculus of 2.7 X 3.1 x 3.6cm (1056 HU) in left pelviureteric junction

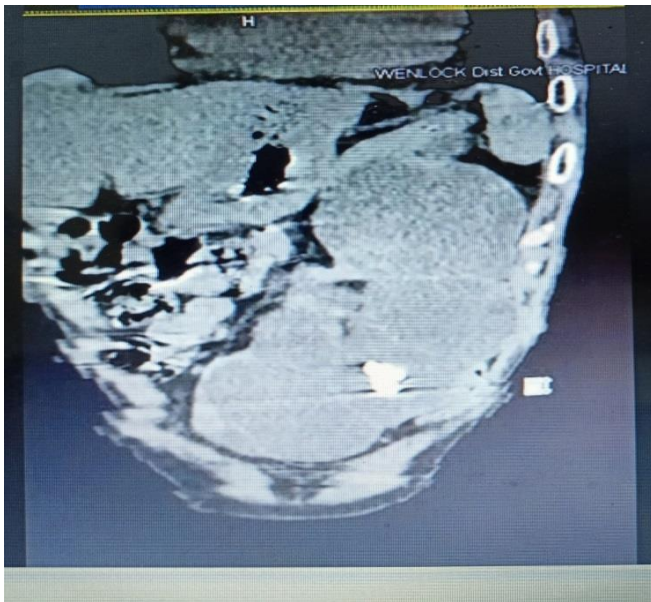

Figure 3: NCCT KUB

Table 1 Diuretic-enhanced ^{99m}Tc DTPA renal scanning

	left kidney	Right kidney
Uptake %	11.19	88.81
Peaking time(min)	8.85	4.6
T ½ from peaking time (min)	0.75	16.64
GFR (ml/min)	5.44	43.12

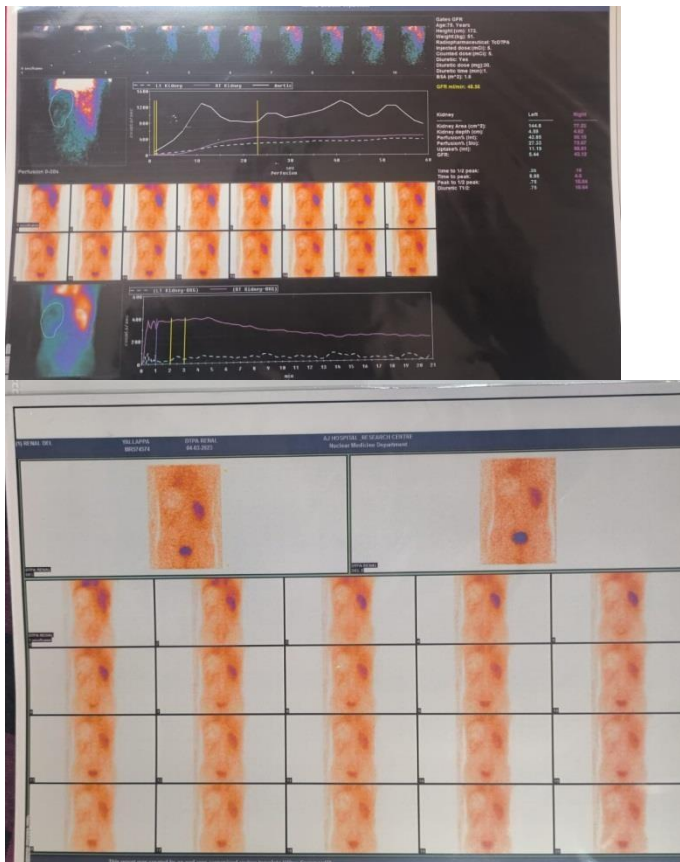


Figure 4: Result of pathological examination

- We therefore performed radical nephrectomy, and gelatinous material was aspirated intraoperatively for decompression of hydronephrosis. Although the cytopathology of gelatinous material was negative for malignancy, we could not rule out other disease, such as hidden malignancies of the kidney.

- “Pathological examination of the kidney uncovered a mucinous adenocarcinoma in the renal pelvis. A bone scan and positron emission tomography showed no evidence of other malignancies, metastasis, or remnant cancer” [12].

Histopathology findings:

- Tumor site : Renal pelvis, Tumor size: 16x10.5x4.5cm , Tumor focality: Unifocal
- Histology: Mucinous Adenocarcinoma, grade: High grade, Tumor necrosis: Present 60%, Tumor extensions: Limited to kidney
- Margins :- Uninvolved by invasive carcinoma - Per nephric fat margin, Renal sinus soft tissue margin, Gerota’s fascia margin , Renal vein margin, Ureteral margin, Closest margin: Renal sinus margin which is 1cm from tumor, Lymphovascular invasion: Not identified
- Pathologic stage classification(pTNM, AJCC 8th edition): pT1
- Additional pathologic findings: Renal calculi identified chronic pyelonephritis.

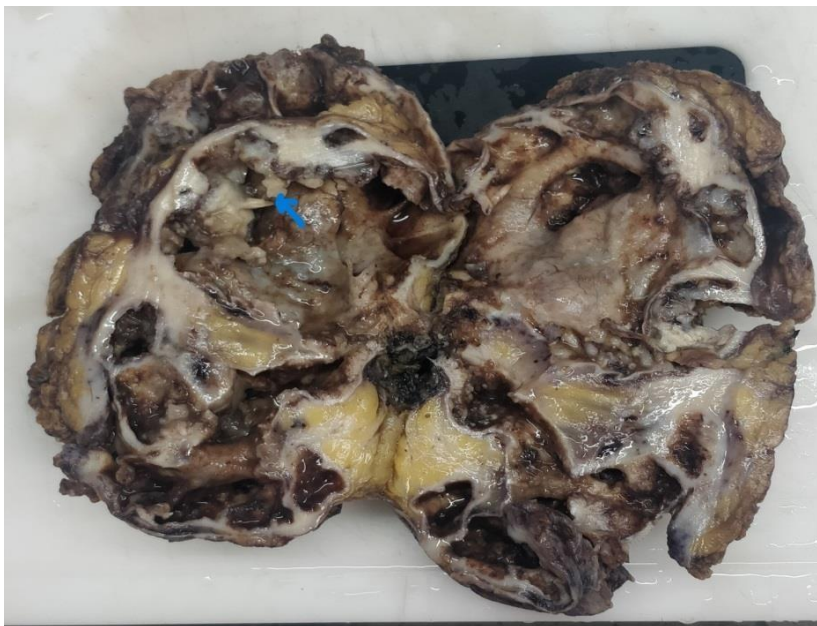

Figure 5: Image of cut surface of the kidney showing markedly dilated renal pelvis with foci of nodular excrescences(arrow) in the wall.

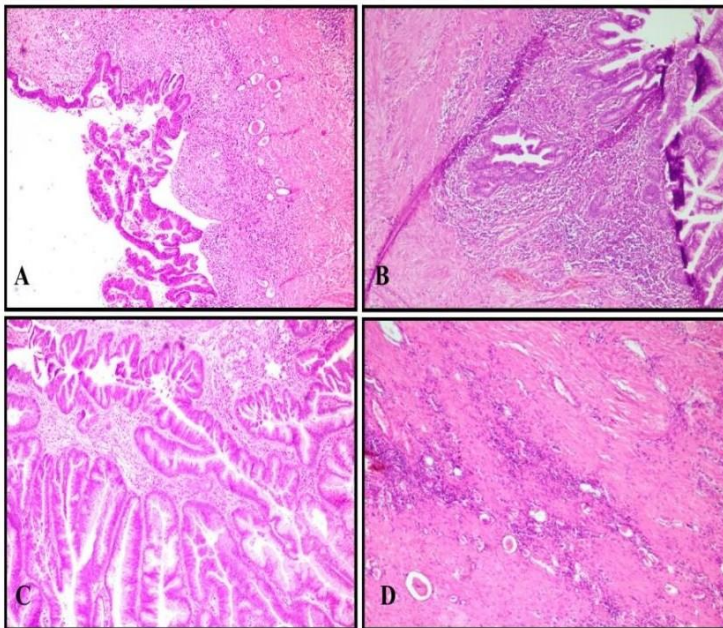


Figure 6: Photomicrographs showing A: tumour arranged in the form of glands and villi form architecture, B: tumour glands invading the lamina propria. C: columnar tumour cells containing mucin lining the glands and villi. D: adjacent compressed renal parenchyma showing atrophic tubules

Conclusion:

Mucinous adenocarcinoma of the renal pelvis is rare in cancer. The pathogenesis is considered to be associated with urolithiasis, long-standing infection and inflammation. Preoperative diagnosis is difficult, thus, urologist should still keep in mind this possibility when the patient has prolonged stone compaction with mucin discharge. Since adjuvant therapy has yet to be established, an early procedure is the most effective treatment. Although no chemotherapy plan has been identified, we can examine the regimen for colon cancer as an alternative choice when the renal tumor has a histological similarity to colon cancer. Mucinous adenocarcinoma is more aggressive and has a worse prognosis than urothelial carcinoma, hence early detection is critical. The prognostic factors include tumor size, stage, and grade. If we can approach these as early as possible, the tumor can be resected with negative margins.

Ethical Approval:

As per international standard or university standard written ethical approval has been collected and preserved by the author(s).

Consent

As per international standard or university standard, patient(s) written consent has been collected and preserved by the author(s).

References

1. Julian W, Kana A, Lee W. Primary mucinous adenocarcinoma of renal pelvis in Solitary pelvic kidney. *Urology* 1993;41:292e4.
2. Joshi K, Jain K, Mathur S, Mehrotra G. Mucinous adenocarcinoma of the renal Pelvis. *Postgrad Med J* 1980;56:442e4.
3. Chen CC, Kuo CL, Lin MS, Hsieh HL, Lin TC, Wu JCH. Mucinous adenocarcinoma of the renal pelvis: an analysis of 5 cases. *JTUA* 2007;18:219e24.
4. Huang KH, Lee WC, Chang SC, Lin BH, Chi HS. Primary mucinous adenocarcinoma of the renal pelvis: a case report. *JTUA* 2004;15:75e7.
5. Mehdi F, Afshin M, Kazem M. Primary mucinous cystadenocarcinoma of renal pelvis: a case report. *Cases J* 2009;2:93e5.
6. Harlan A, Thomas D, William T. Mucinous adenocarcinoma of renal pelvis. *Urology* 1982;20:94e5.
7. Vinaya BS, Gayathri PA, Jaya RD, Hemant B. Mucinous adenocarcinoma of the renal pelvis with pseudomyxoma peritonei. *Indian J Pathol Microbiol* 2008;51:536e7.
8. Kaur G, Naik VR, Rahman MNG. Mucinous adenocarcinoma of the renal pelvis associated with lithiasis and chronic gout. *Singapore Med J* 2004;45:125e6.
9. Kathryn JW, Margaret MS, Barry IS, Isaac RF. Squamous cell carcinoma of renal pelvis: case report emphasizing sonographic and CT appearance. *Urol Radiol* 1983;5:267e9.
10. Xu X, Shen W, Wang D, Li N, Huang Z, Sheng J, Rucker AJ, Mao W, Xu H, Cheng G. Clinical features and prognosis of resectable pulmonary primary invasive mucinous adenocarcinoma. *Translational Lung Cancer Research*. 2022 Mar;11(3):420.
11. Zeng H, Zhang M, Xie Y, Wang M, Dai J, Zhu X, Zeng Y, Xu N, Huang P, Zhao J, Sun G. Primary renal mucinous adenocarcinoma masquerading as a giant renal cyst: a case report. *Frontiers in Oncology*. 2023 May 8;13:1129680.
12. Han DS, Yuk SM, Youn CS, Park G, Sul HJ, Jang H. Primary mucinous cystadenocarcinoma of the renal pelvis misdiagnosed as ureteropelvic junction stenosis with renal pelvis stone: a case report and literature review. *World Journal of Surgical Oncology*. 2015 Dec;13(1):1-5.