

## Case report

# An impressive case report of pachyonychia congenita, and short literature review

### ABSTRACT

**Aims :** Pachyonychia congenita is a rare genodermatosis related to mutations in the genes encoding keratins. Illustrations of such a typical case of this uncommon condition have rarely been seen in the literature, hence the interest of our case report.

**Case report :** An 11-year-old girl with a history of parental inbreeding presented with painful bilateral plantar hyperkeratosis associated with significant pachyonychia of the 20 nails and other clinical signs supporting the diagnosis of pachyonychia congenita.

**Discussion :** Pachyonychia congenita is an autosomal dominant inherited dyskeratosis due to a mutation in the keratin genes k6a, k6b, k6c, k16 or k17. Clinical signs are dominated by pachonychia and painful palmoplantar keratoderma impacting patients' quality of life. The association with other disorders is possible. To date, treatment remains symptomatic.

**Conclusion :** The diagnosis of congenital pachyonychia is based on the genetic study of the mutations involved. Nevertheless, a clinical presentation as suggestive as ours allows the immediate diagnosis, thus making this article interesting.

*Keywords: Genodermatosis - Dyskératosis - Pachyonychia - Palmoplantar keratoderma - Child*

## 1. INTRODUCTION

Pachyonychia congenita is a very rare autosomal dominant hereditary disease, characterized mainly by hypertrophic onychodystrophy and palmoplantar keratoderma, responsible for an impaired quality of life. We report the case of an 11-year-old girl with a typical and impressive clinical presentation.

## 2. PRESENTATION OF THE CASE

We report the case of a young Mauritanian girl, 11 years old, born of a consanguineous marriage and second of three siblings. She was complaining of a bilateral plantar pain that was getting worse every year since she started walking. The

patient was otherwise completely free of systemic symptoms. She, and all other family members had no history of systemic or another skin diseases.

Clinical examination revealed, onychogryphosis of all her fingernails and toenails associated with a significant bilateral plantar keratoderma localized to the support areas (Figure 1A,B). She also had rough skin with small keratotic papules especially on the trunk, as well as thickening of the skin around her knees and elbows (Figure 2,3). On the tongue, there was a leukoplakia that could not be removed by scraping and on the face she had multiple small creamy and diffuse cystic formations of recent appearance (figure 4). Polarized dermoscopy of those cystic formations shows a central creamy glow with a pseudo-reticular pigmentary network around it, strongly suggestive of pilosebaceous cysts such as steatocystoma (Figure 5).

The diagnosis of pachyonychia congenita was made on the basis of the anamnesis reporting a notion of parental consanguinity and a very early onset of the symptoms, as well as on the very suggestive clinical association: pachyonychia of all 20 nails, keratoderma, follicular keratosis of the trunk, pilosebaceous cysts of the face, and lingual leukokeratosis.

A symptomatic treatment was prescribed to relieve the patient, based on emollient and keratolytic. She was also scheduled for a series of nail avulsion surgeries but did not return.

In addition, an ophthalmological and ENT examination and a chest X-ray, in order to look for possible associated abnormalities, were performed. All were normal.

### 3. DISCUSSION

Pachyonychia Congenita (PC) is a very rare autosomal dominant disorder of keratinization that mainly involves the skin and nails. This genodermatosis is related to mutations in one of five different keratin genes: KRT6A, KRT6B, KRT6C, KRT16, or KRT17 [1]. It is a very uncommon orphan disease with an estimated prevalence of 0.9 per 1 million individuals [2]. Over 45% of cases appear de novo, with no family history of PC [3]. Moreover, it occurs equally in both sexes. PC has been categorized into five types based on the mutation of the underlying keratin gene. In decreasing order of frequency, we find the subtype PC-K6A, then PC-K16, PC-K17, PC-K6B and finally the subtype PC-K6C [4].

Its clinical presentation is very variable, it usually manifests at a very early age with neonatal teeth. The main dermatological manifestations are pachyonychia, an usually painful palmoplantar keratoderma and blistering, pilosebaceous cysts including steatocystoma, oral leukokeratosis, keratosis of the trunk and friction zones as well as an inconstant hyperhidrosis [5]. Plantar pain, which is thought to be neuropathic or due to secondary blisters, represents the sign with the greatest impact on patients' quality of life [6].

In addition, deafness, corneal dyskeratosis, cataract, hoarseness, mental retardation and bronchial dilatation are described associations in the literature [7,8]. The genetic study, when available, allows the diagnosis of certainty and the classification of the type of PC.

This condition, of good prognosis, is responsible for an aesthetic prejudice that impacts the quality of life of affected patients. The treatment of plantar pain and nail hyperkeratosis are the priorities. Typical management strategies include mechanical treatments such as filing, grinding and cutting of nails, as well as systemic drugs in particular retinoids and topical agents such as keratolytics, emollients and dermocorticoids [9]. But to date, the treatment remains a real challenge as all proposed therapeutic options are unsatisfying.

Nevertheless, new therapeutic perspectives are being evaluated, such as small interfering RNA strategies, inhibitors of the mTOR, some statins and botulinum toxin injection [10].

### 4. CONCLUSION

Pachyonychia congenita is a rare hereditary dyskeratosis linked to mutations affecting keratins k6a, k6b, k6c, k16 or k17. The diagnosis is clinically evoked; It should be suspected in the presence of palmoplantar keratoderma and pachyonychia beginning in early childhood.

## CONSENT

All authors declare that written informed consent was obtained from the patient's parent (for publication of this case report and accompanying images). A copy of the written consent is available for review by the Editorial office/Chief Editor/Editorial Board members of this journal.

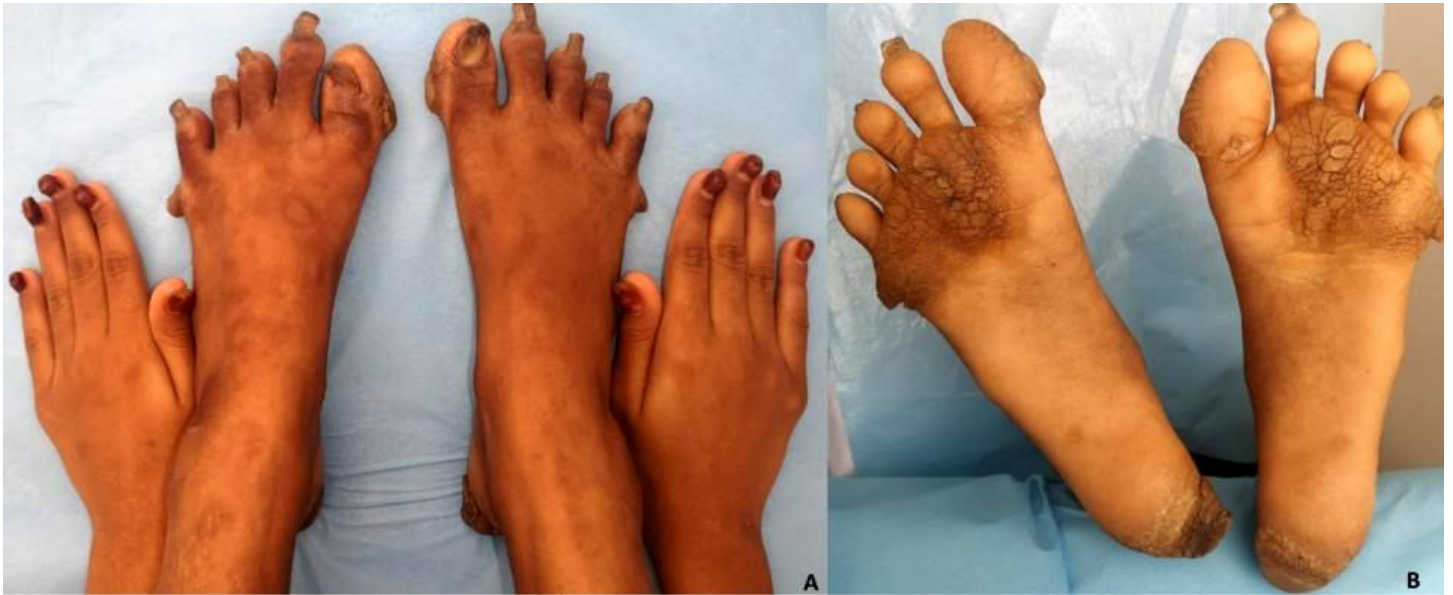## ETHICAL APPROVAL

All authors hereby declare that all experiments have been examined and approved by the appropriate ethics committee and have therefore been performed in accordance with the ethical standards laid down in the 1964 Declaration of Helsinki.

## REFERENCES

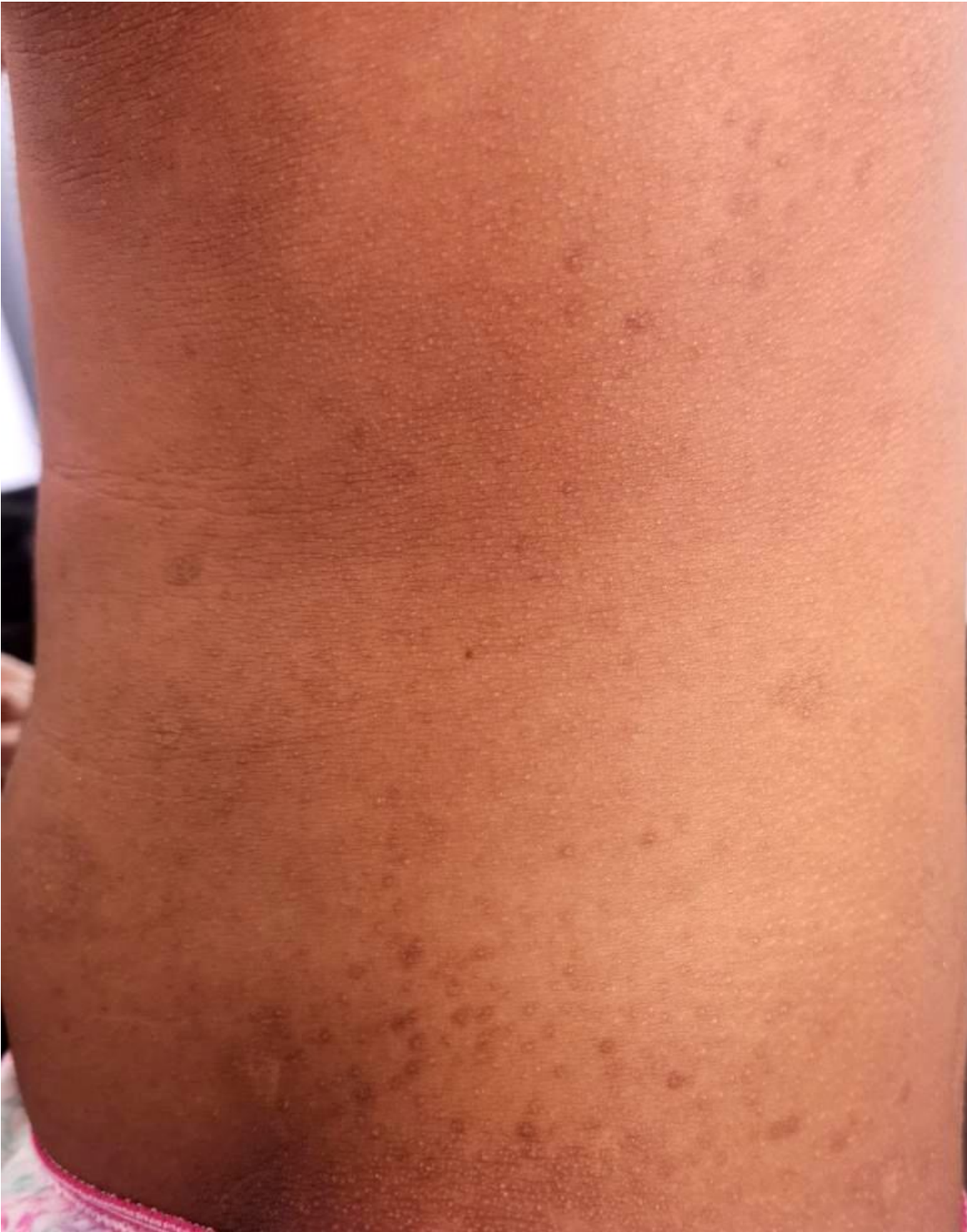1. Hur K, Ko JM, Mun J-H, Pachyonychia Congenita with a Novel Variant in the KRT16 Gene, c.348\_379delinsAA, *Ann Dermatol*. 2022 Dec; 34(6): 490–492 , <https://doi.org/10.5021/ad.20.248>
2. Samuelov L, Smith FJD, Hansen CD, Sprecher E. Revisiting pachyonychia congenita: a case–cohort study of 815 patients. *Br J Dermatol* 2020; 182:738–46
3. Prasad A.M, Inakanti Y, Kumar S, Jadassohn Lewandowsky Syndrome: A Rare Entity , *Indian J Dermatol*. 2015 Sep-Oct; 60(5): 524; <https://doi.org/10.4103/0019-5154.159665>.
4. Eliason MJ, Leachman SA, Feng BJ, Schwartz ME, Hansen CD, A review of the clinical phenotype of 254 patients with genetically confirmed pachyonychia congenita. *J Am Acad Dermatol*. 2012;67:680–686.
5. Smith F.J.D, Hansen D, Hull P.R, Kaspar R.L, McLean W.H.I, O'Toole E et al., Pachyonychia Congenita, GeneReviews® [Internet]. Seattle (WA): University of Washington, Seattle; Bookshelf ID: NBK1280.
6. Weinberg RL, Coulombe PA, Polydefkis M, Caterina MJ. Pain mechanisms in hereditary palmoplantar keratodermas. *Br J Dermatol* 2020; 182:543–51.
7. Feinstein A, Friedman J, Schewach-Millet M. Pachyonychia congenita. *J Am Acad Dermatol*. 1988 Oct;19(4):705-11. doi: 10.1016/s0190-9622(88)70226-1.
8. El Alaoui Ismaili F, Chemlal A, Karimi I, Benabdellah N, Bentata Y, Zizi N et al., Pachyonychie congénitale associée à une sténose de l'artère rénale et une dilatation des bronches, *Pan Afr Med J*. 2016; 24: 183.<https://doi.org/10.11604/pamj.2016.24.183.9284>
9. Goldberg I, Fruchter D, Meilick A, Schwartz ME, Sprecher E. Best treatment practices for pachyonychia congenita. *J Eur Acad Dermatol Venereol*. 2014;28:279–285.
10. Steele L, O'Toole E.A, Pachyonychia congenita, a paradigm for rare skin disorders, *Br J Dermatol*. 2020 Mar;182(3):521-522, <https://doi.org/10.1111/bjd.18817>.

## FIGURES

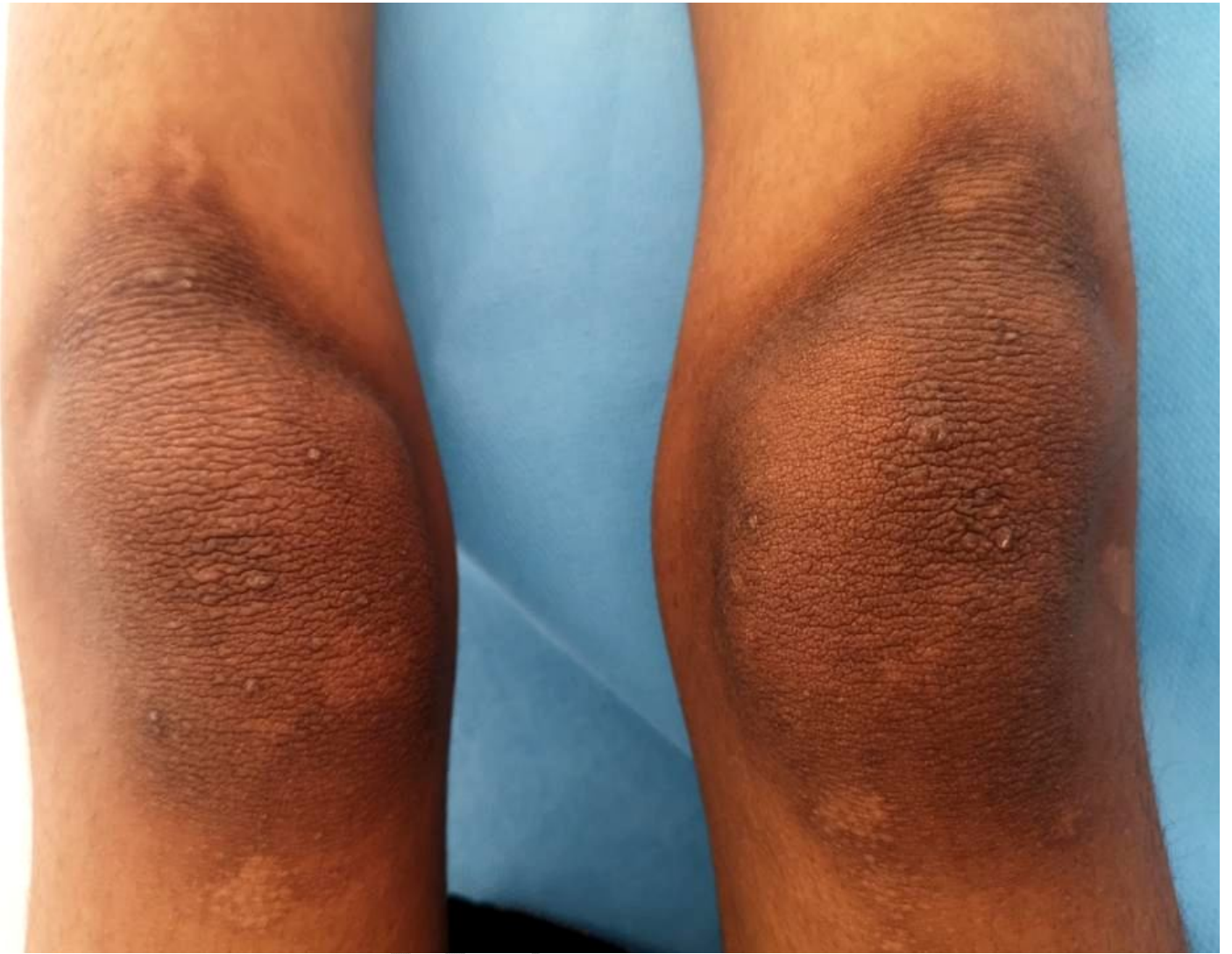


**Figure 1** : Pachyonychia of the 20 nails (A) with an important bilateral plantar hyperkeratosis at the support areas (B).

UNDER PEER

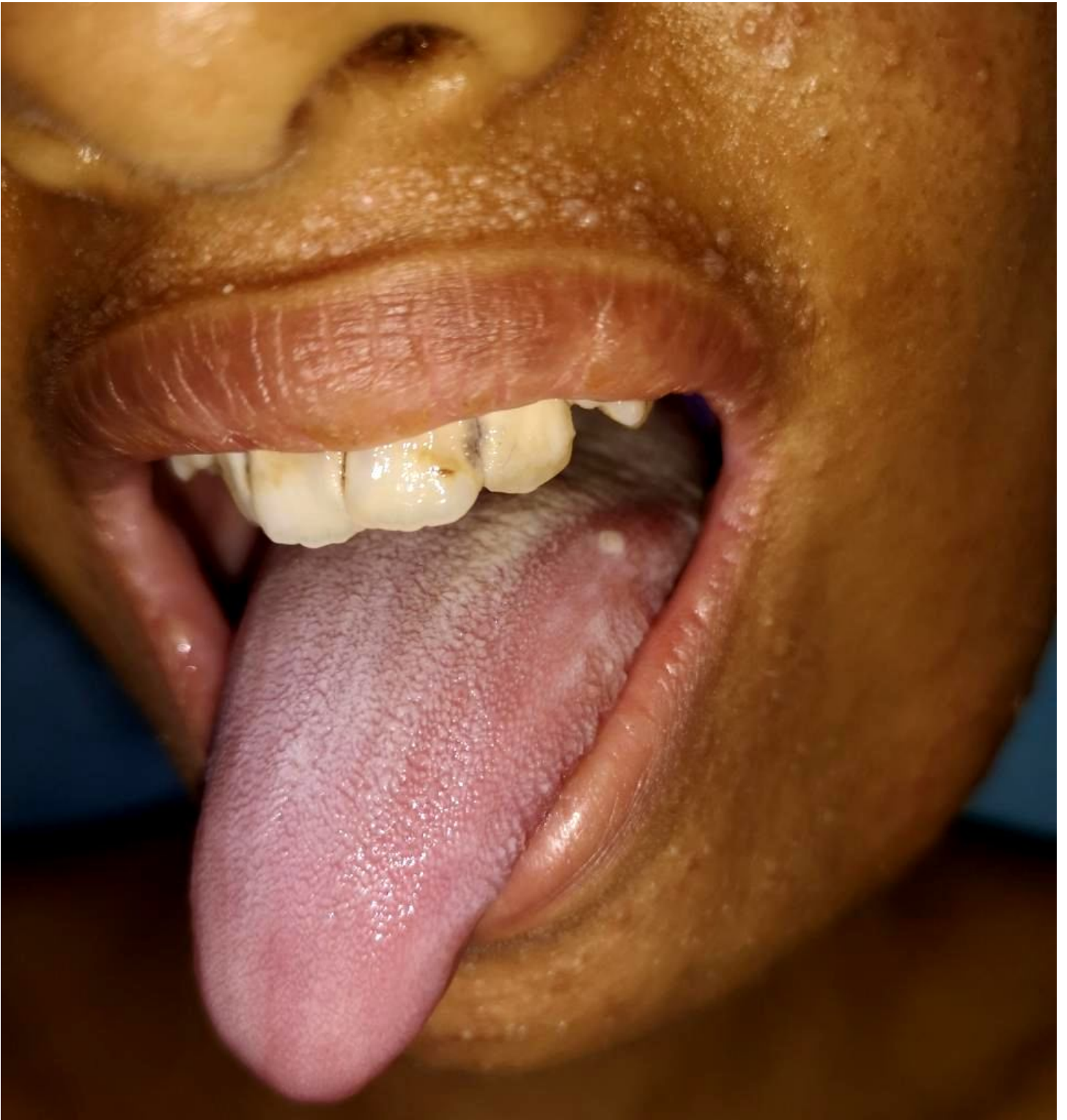


**Figure 2 :** Rough skin aspect with small keratotic papules spread all over the trunk.

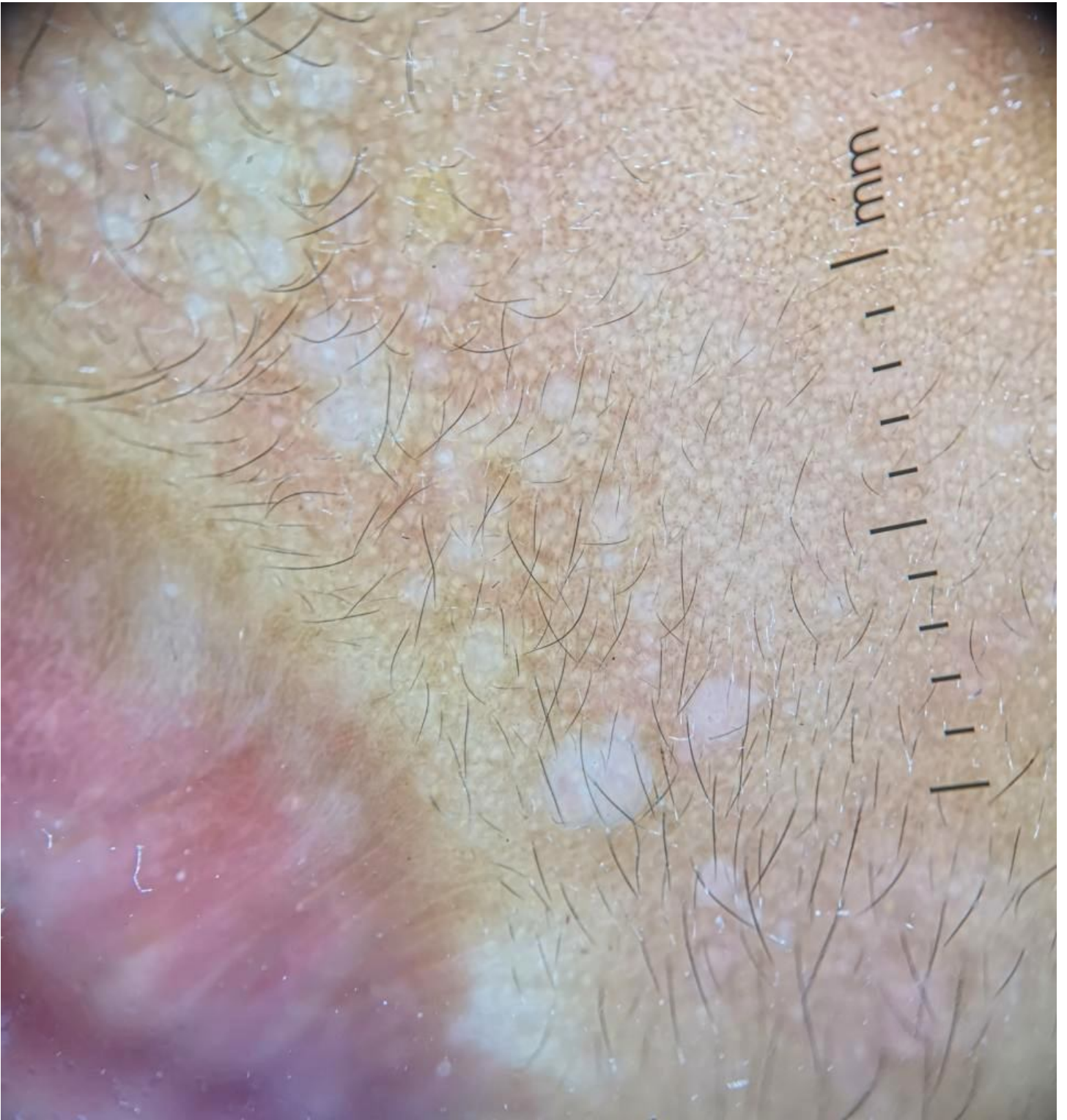


**Figure 3 :** Thickened and hyperpigmented skin around the knees.

UNDER



**Figure 4 :** Leukoplakia of the tongue with multiple small vesicles with clear material above the upper lip.



**Figure 5 :** Central creamy glow with a pseudo-reticular pigmentary network seen in polarized dermoscopy.