

AMELIORATIVE POTENTIALS AND TISSUE-PROTECTIVE EFFECTS OF METHANOLIC EXTRACT OF *PERSEA AMERICANA* SEEDS ON RENAL FUNCTION IN ALLOXAN-INDUCED DIABETIC WISTAR RATS

ABSTRACT

INTRODUCTION: Diabetic nephropathy is a leading cause of end-stage renal failure and chronic kidney disease throughout the globe. Despite the fact that much research has been conducted in both basic science and clinical therapeutics to better understanding of the biology of diabetic nephropathy and increase the number of potential medicines available, this research aimed to assess the ameliorative potentials and tissue-protective effects of *Persea Americana* Seeds aqueous extract on renal function in Alloxan-Induced Diabetic Wistar Rats. **MATERIALS AND METHODS** Methanol was used to remove the seeds of *Persea Americana*, which were then refrigerated until use. Thirty mature male Wistar rats were split into six groups of five. Group 2 to 6 rats were given a single intraperitoneal injection of alloxan (150 mg/kg) to cause diabetes. Normal and diabetic control groups are represented by groups 1 and 2, accordingly. *Persea Americana* Seeds extract was given to groups 3, 4, and 5 at doses of 120, 240, and 480 mg/kg/day, respectively, while metformin was given to group 6. After 14 days of treatment, the animals were sacrificed, blood samples were taken, and serum was centrifuged for biochemical analysis. The kidney were excised for histomorphological and biochemical analysis. The data were analyzed using the SPSS package, version 23, and the findings were expressed as Mean SEM. **RESULT** Significant decreases in blood glucose, urea, creatinine, and MDA levels were observed in all diabetic groups treated with the plant extract, but there was no significant change in potassium and bicarbonate ions. However, there was a significant increase in Na⁺ and Cl⁻, Catalase, and SOD activities in all diabetic treated rats. Following therapy, the kidney tissues of infected animals were found to be recovered from the toxic effects of alloxan induction. **CONCLUSION** *Persea Americana* seed has anti-diabetic, antioxidant properties, and can repair damage produced by alloxan toxicity.

Key Words: Alloxan, Diabetes Mellitus; Hypoglycemia, Nephropathy, Wistar rats,

INTRODUCTION

“Diabetic nephropathy (DN) is a long-term complication of diabetes that has become the leading cause of end-stage renal disease (ESRD) in many countries” (1). “It places a significant financial strain on health-care budgets (2), and it's linked to a drop-in health-related quality of life” (3). “Furthermore, diabetic nephropathy is linked to an increased risk of cardiovascular death in both type I and type II diabetic patients (4, 5), as well as a set of histological features proposed by the Renal Pathology Society” (4, 5, 6). “Diabetic nephropathy affects 30% of people with diabetes, and it frequently leads to end-stage renal failure” (5). “Diabetic nephropathy is defined by macro albuminuria (proteins especially albumin) of more than 300 mg in a 24-hour urine collection or macro albuminuria with impaired renal function as measured by serum creatinine and serum urea” (7). “The evaluation of a patient's renal function aids in the diagnosis of compromised renal function and the detection of progressive renal function loss” (7).

Proteinuria, a decrease in glomerular function rate (GFR), and hypertension are all signs of diabetic nephropathy, which carries a high risk of cardiovascular morbidity and mortality (8). “Furthermore, biomarkers such as serum urea and creatinine are known to be elevated with hyperglycemia in uncontrolled diabetes and usually correspond with the severity of kidney damage in diabetic nephropathy” (7). “Serum urea and creatinine measurements are readily available assays that can help detect and prevent diabetic kidney disease at an early stage, limiting the progression to end-stage renal

disease (ESRD)” (7- 9). The simplest technique to assess kidney function is to take blood tests for BUN and creatinine, which are common metabolic waste products that the kidneys expel (7). “While urea is a byproduct of protein breakdown, creatinine is the breakdown product of creatinine phosphate, which is generated at a constant rate from skeletal muscle” (10). “The glomerulus filters urea and creatinine, while the proximal tubule secretes a little amount into the glomerular filtrate” (7, 10, 11). “BUN levels should be between 7 and 20 mg/dL, whereas creatinine levels should be between 0.8 and 1.4 mg/dL” (12).

“Fluid and electrolyte balance are also critical for maintaining bodily homeostasis, as well as protecting cellular function, tissue perfusion, and acid-base balance” (13). The link between blood glucose and electrolytes is complicated, and electrolyte imbalance can have an impact on the progression of diabetes and how well it is managed (14). Renal tubules are responsible for maintaining the body's electrolyte balance, hence tubular malfunction leads to electrolyte imbalance (15). Because nephropathy is related with various micro-vascular complications (16), it is unknown when tubular dysfunction occurs in type 2 diabetics, therefore, early detection and treatment to rectify the electrolyte imbalance would result in a better prognosis for patients (1). Another aim that does not appear to be within reach in the near future is the development of regenerative medicine for the treatment of renal illness.

“According to the World Health Organization, traditional medicines are used by 80 percent of the world's population for health care” (17). “Several medicinal plants have been demonstrated to effectively help their therapeutic components in a variety of illnesses, prompting widespread testing. The quest for natural chemicals rich in antioxidant, anticancer, and antibacterial characteristics is rising today due to their therapeutic significance in regulating many related chronic conditions such as diabetes, cancer, and cardiovascular diseases. Antioxidants help to avoid oxidative stress in cells by scavenging excess free radicals in the body and are effective in the treatment of many human disorders, including diabetes” (3).

“Avocado pear (*Persea Americana*) is a tropical and temperate plant that thrives in both temperate and tropical climates. It is a member of the Lauraceae family and has long been used medicinally” (18, 19). *Persea Americana* seed and shoots have been demonstrated to have anti-cancer effects (19, 20). According to one report, the fruit of *Persea Americana* includes reductase and transferase enzymes, and the seed extract is erythroagglutinating (20). “Various portions of the *Persea Americana* plant have been used to treat anemia, exhaustion, hypercholesterolemia, hypertension, gastritis, and gastroduodenal ulcer” (19, 20). “The leaf is an important antitussive, antidiabetic, and arthritis pain reliever, according to traditional medicine practitioners of the Ibibio tribe in South Nigeria” (18). “Analgesic and anti-inflammatory properties of *Persea Americana* have also been discovered” (20).

MATERIALS AND METHODS

Chemicals and Drugs

Sodium Citrates (BDH chemicals LTD Pools England), Methanol, Guangdong Guanghua Sci-Tech Co., Ltd. Shatou, Guangdong, China, 515000, The alloxan (monohydrate) LR, $C_4H_2N_2O_4 \cdot H_2O$, product number: Allo108, Batch number CE102AK01) was purchased from Uche Scientific Co. Ltd. 21, Head bridge Market Onitcha, Anambra State, Nigeria and Metformin (Glucophage) Tablet. All the chemicals and drugs used were of analytical grade.

Collection of Plant

Avocado seeds were collected from their growing habitats in Ughoton, Okpe Local Government, Delta State, Nigeria, identified and authenticated by Mr. Namadi Sanusi in the Department of Biological Sciences, Ahmadu Bello University Zaria, Kaduna State, Nigeria, with Voucher Specimen No. ABU0992.

Preparation of Plant Extract

The avocado seed extract was made according to Ekam *et al.* (21)'s method, with minor changes made by Ojeh (3). The avocado seeds were washed, air-dried, and ground into fine powder. Fifty (50 g)

grams of powdered seed were cold macerated for 72 hours at room temperature (26 - 28°C) in 0.5 L of water containing 80 percent v/v methanol and filtered with Whatman filter paper No.1. The filtrate was evaporated to dryness in a water bath at 40°C, yielding 9g (18% w/w) of dark green semi-solid extract. The extract was placed in a sealed container and kept in the refrigerator at 4°C until it was used in the experiment.

Experimental Animal

Thirty (30) adult male Wistar rats weighing between 150 and 200 g were procured at Delta State University's Faculty of Basic Medical Sciences Animal Farm in Abraka, Nigeria. The animals were housed in metabolic cages. Top Feed Food Production in Sapele, Delta State, provided animal feed. They were fed daily on mash diet of animal feed growers, which included protein 17.0%, minimum fat 4.5 percent, minimum calcium 0.96 percent, minimum phosphorus 3.92 percent usable, 2450kcal capacity, and water ad libitum.

Acute Toxicity Study

Acute Toxicity Activity of *Persea Americana* was conducted by Eduardo *et al.* (22) to be 1200.75 mg/kg. So 1/10 of LD50 - 1200.75 mg/kg = 120mg/kg as the starting dose.

Chemical and Drug Preparation

Diabetic agent

To make 2 percent (2%) citrate buffer, two grams (2g) of sodium citrate was dissolved in 100ml of water, and 0.6g of Alloxan monohydrate was dissolved in the 2 percent (10ml) citrate buffer to make 150mg of stock solution.

Anti-diabetic drug

500mg of metformin (Glucophage) was dissolved in 10ml of distilled water to make an anti-diabetic drug solution.

Induction of Diabetes Mellitus

The rats were separated into six groups of five rats each and fasted for 18 to 24 hours. Diabetes was induced in groups 2 to 6 rats by a single intraperitoneal (I.P) injection of the freshly synthesized Diabetic agent at a dose of 150 mg/kg body weight, as assessed by a glucometer (Accu-Chek) and an electronic weighing scale, respectively.

Confirmation of Diabetes Mellitus

A glucometer (Accu-check active, Germany) was used to track the development of diabetes after 72 hours of DM induction, which was confirmed by raised fasting serum glucose levels above 200 mg/dL. (23, 24).

Experimental Design

During the study period,

Group 1 (n=5) – (Control Group) Wistar rats were not induced nor treated prior to sacrifice.

Group 2 (n=5) – Diabetic Wistar Rats were not treated prior to sacrifice

Group 3 (n=5) – Diabetic Wistar Rats received 120 mg/kg body weight of *Persea Americana* Seed Extract

Group 4 (n=5) – Diabetic Wistar Rats received 240 mg/kg body weight of *Persea Americana* Seed Extract

Group 5 (n=5) – Diabetic Wistar Rats received 480 mg/kg body weight of *Persea Americana* Seed Extract

Group 6 (n=5)–Diabetic Wister Rats were received 100 mg/kg body weight of metformin Glucophage

Sample Collection

After 14 days of extract administration, rats were placed on their dorsal surfaces, a laparotomy was performed to reveal internal organs, blood samples were collected by cardiac puncture using 5 ml syringes and 23 G needles in blood sample containers, centrifuged for 10 minutes at a rate of 4000 rpm, and serum was collected and stored in blood sample containers. The kidneys were harvested and studied histomorphologically and biochemically.

Preparation of Tissues for Microscopy

Methodology: “The process of preparation of the kidney for histological examination was carried out in stages: fixation, tissue processing, sectioning, mounting and staining” (25).

Materials: 10 % formal saline, kidney tissue, absolute alcohol, 95% alcohol, 70% alcohol, xylene, paraffin wax, oven, microtome, slides, borosilicate cover glass, microscope, digital microscope eyepiece.

Methodology: “The process of preparation of the liver for histological examination was carried out in stages: fixation, tissue processing, sectioning, mounting and staining” (25).

Fixation: The kidney was carefully removed whole and fixed in 10 % formal saline for 72 hours.

Tissue Processing: The kidney was cut along the coronal plane and processed using the automated tissue processor.

Sectioning and Mounting: Sections were cut using the Rotary microtome with size 10 micron. The cut sections were floated on hot water bath, picked and mounted on clean slides for staining.

Staining: The routine staining technique employed in this preparation was the Haematoxylin and Eosin (H & E).

Photomicrography

The stained tissue images were captured using Digital Microscope Eyepiece “SCOPETEK” DCM 500, 5.0 megapixel connected to USB 2.0 computer.

Biochemical Analysis

Determination of Body Weight and Organ Weight

Body weight of experimental animals was checked/determined at first week (before and after induction / before administration) and subsequent weeks and last day of experiment before sacrifice. Percentage weight change was later calculated as follows.

$$\text{Percentage weight change (\%)} = \frac{\text{final-bodyweight (g)} - \text{intialbodyweight (g)}}{\text{intialbodyweight (g)}} \times \frac{100}{1}$$

Assessment of Kidney Function

Urea

“Urea content of the serum samples was estimated by means of an automated analyzer, Blood Urea Analyzer, Beckman Coulter Inc., USA. The analysis procedure required a setup of reagents, Hichem kit of reagents for blood urea nitrogen analyzer. The kit was supplied by Elan Diagnostics, USA” (26).

Creatinine

“Creatinine Analyzer-2 (Beckman Coulter Inc., USA) in combination with a specific kit of reagents (Hichem Creatine Pak, Elan Diagnostics, USA) was employed to calculate creatinine content of the serum samples” (26).

Determination of Electrolytes Level

Sodium (Na)

The level of sodium ions was calculated using a method outlined by Grindler and Health, (27).

Potassium (K)

“The amount of potassium was determined by the method of Terri and Sesin, (28), by using sodium Tetrphenylboron in a specifically prepared mixture to produce a colloidal suspension. The turbidity of which is proportional to potassium concentration in the range of 2-7mEq/L”.

Determination of Antioxidants Biomarkers

Assay for Superoxide Dismutase (SOD)

The activity of SOD in the tissue homogenates was estimated spectrophotometrically using the method of Misra and Fredorich (29).

Assay for Catalase

The activity of catalase was determined in the tissue homogenates by the method of Cohen *et al.* (30).

Determination of Lipid Peroxidation

The thiobarbitoric acid reactive substance (TBARS), a breakdown product of lipid peroxidation, was detected in tissue homogenates using the Gutteridge and Wilkins method (31).

Statistical Analysis

After comparing the values for individual controls for different treatment groups, the results were expressed as mean values with standard mean error (Mean SEM). Using SPSS version 23 software, significant differences between control and experimental groups were examined using the student's t-test and ANOVA variance analysis, with P-values of less than 0.05 (P<0.05) being significant.

RESULTS

Microscopic Examination of Kidney tissues

In group I (control), the renal cortex shows histological features with the glomerulus (G), proximal (P) and distal convoluted (C) tubules appearing normal and the Bowman's space is well outlined.

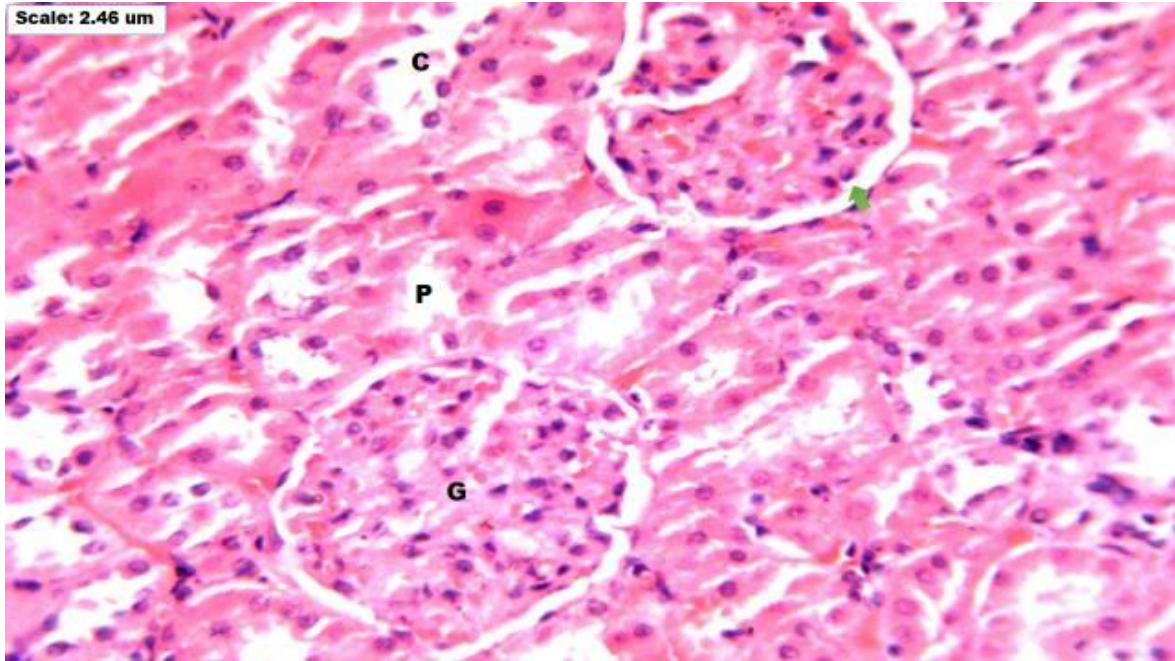


Plate 1: Photomicrograph of coronal section of kidneys of adult Wistar rats. Group I (control) H & E x250

Note: G - Glomerulus, P - Proximal convoluted tubule, C- Distal convoluted tubules

In group II that was induced with 150 mg of Alloxan intraperitoneally, the renal cortex shows hemorrhagic (H) renal corpuscle with apparently degenerated glomerular tuft (G), infiltrated with inflammatory cells (circles). Most of the tubular cells appear dilated with degeneration of vesicular nuclei (yellow arrow). There is dilatation of the Bowman's space.

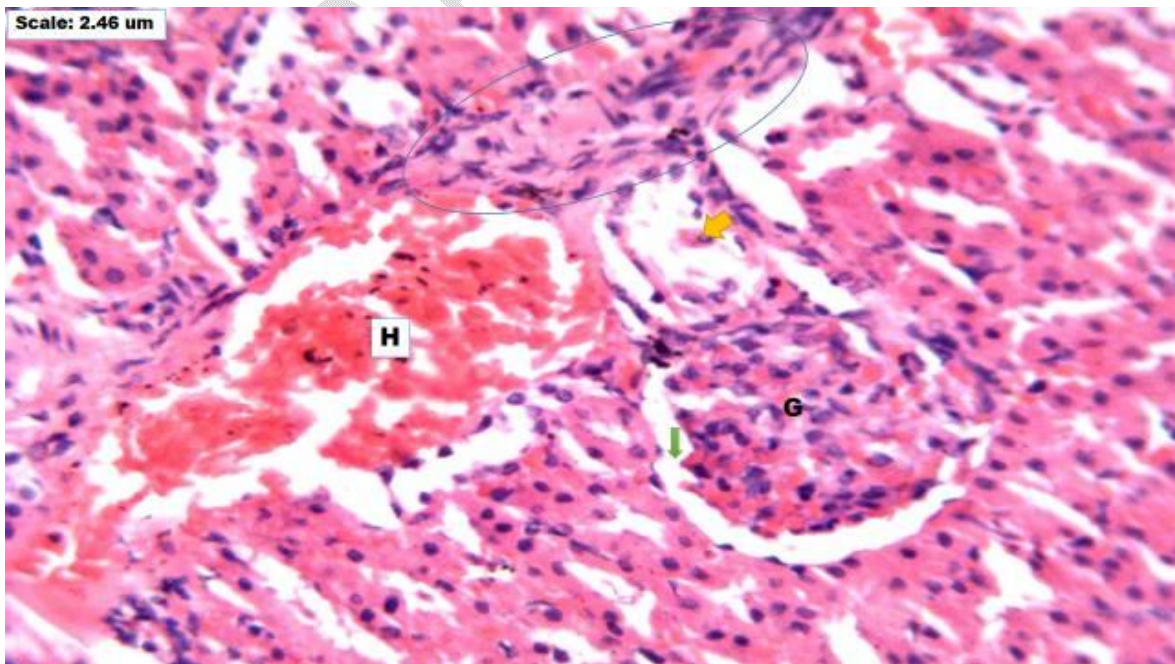


Plate 2: Photomicrograph of coronal section of kidneys of diabetic induced adult Wistar rats. Group II (Negative Control). H & E x250

Note: G-Glomerulus, H-Haemorrhagic area, Circle - inflammatory cells, Yellow arrow - degenerated vesicular nuclei

In group III, that had oral administration of 120 mg/kg bwt/day of *Persea Americana*, the renal cortex shows hemorrhagic (H) renal corpuscle with aggregation of inflammatory cells (circle). The bowman's space, (yellow arrow), proximal (P) and distal convoluted (D) tubules appear dilated.

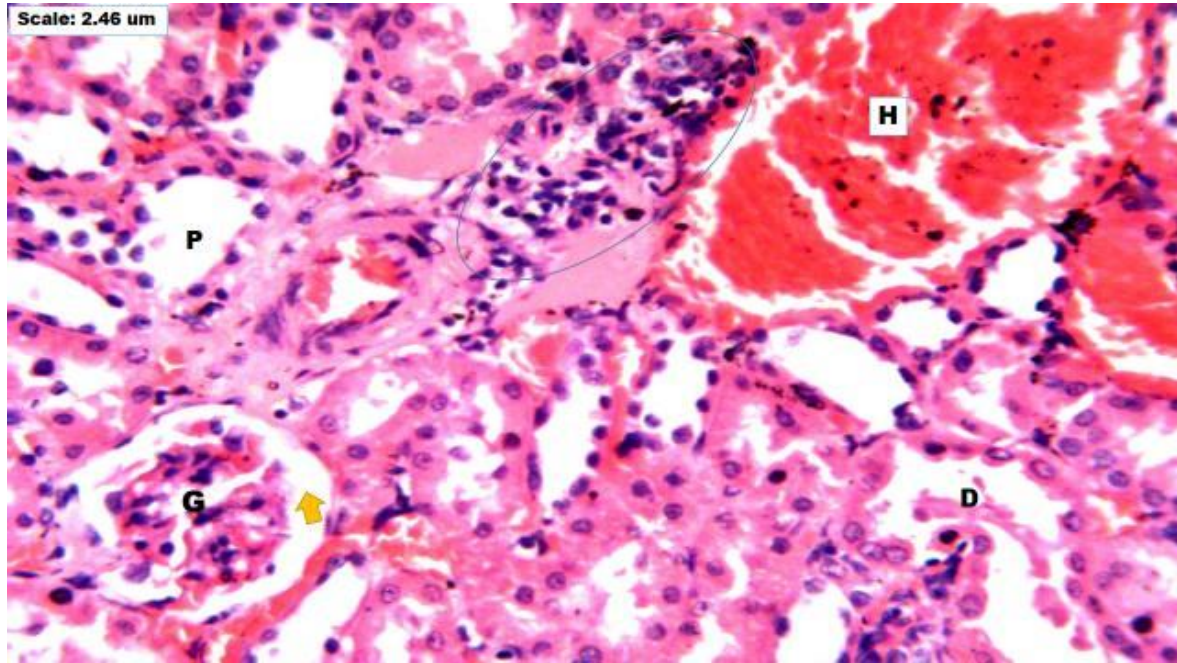


Plate 3: Photomicrograph of coronal section of kidneys of diabetic induced adult Wistar rats. Group 3 (Oral administration of 120 mg/kg bwt/day of *Persea Americana* for 14 days). H & E x250

Note: G-Glomerulus, H-Haemorrhagic renal corpuscle, Circle – Aggregation of inflammatory cells, Yellow arrow – Bowman's space, P – Proximal convoluted tubule, D- Distal convoluted tubule.

In group IV that had oral administration of 240 mg/kg bwt/day of *Persea Americana*, the renal cortex shows is haemorrhagic (H). There is aggregation of inflammatory cells (yellow arrow). Both proximal and distal convoluted tubules are degenerated and dilated (circle). There are evidences of regeneration of the glomerulus and tubules with their single cuboidal epithelial cells.

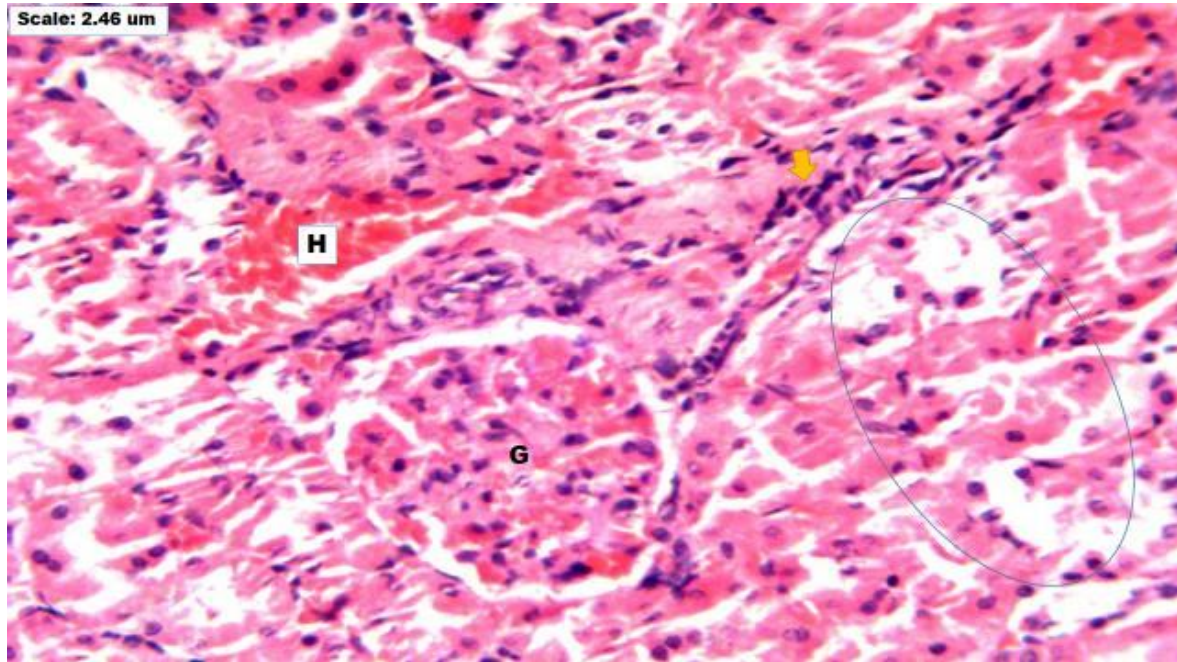


Plate 4: Photomicrograph of coronal section of kidneys of diabetic induced adult Wistar rats. Group 4 (Oral administration of 240 mg/kgbw/day of *Persea Americana* for 14 days). H & E x250

Note: G-Glomerulus, H-Haemorrhagic renal cortex, Circle – Dilated proximal and distal convoluted tubules, Yellow arrow – Aggregation of inflammatory cells.

In group V that had oral administration of 480 mg/kgbw/day of *Persea Americana*, the renal cortex shows sparsely distributed inflammatory cells (yellow arrow). Also the renal cortex is not haemorrhagic. There are regenerations of single cuboidal epithelial cells of the proximal and distal convoluted tubules with normal cellular structure. However, there are some degenerating tubules (circle).

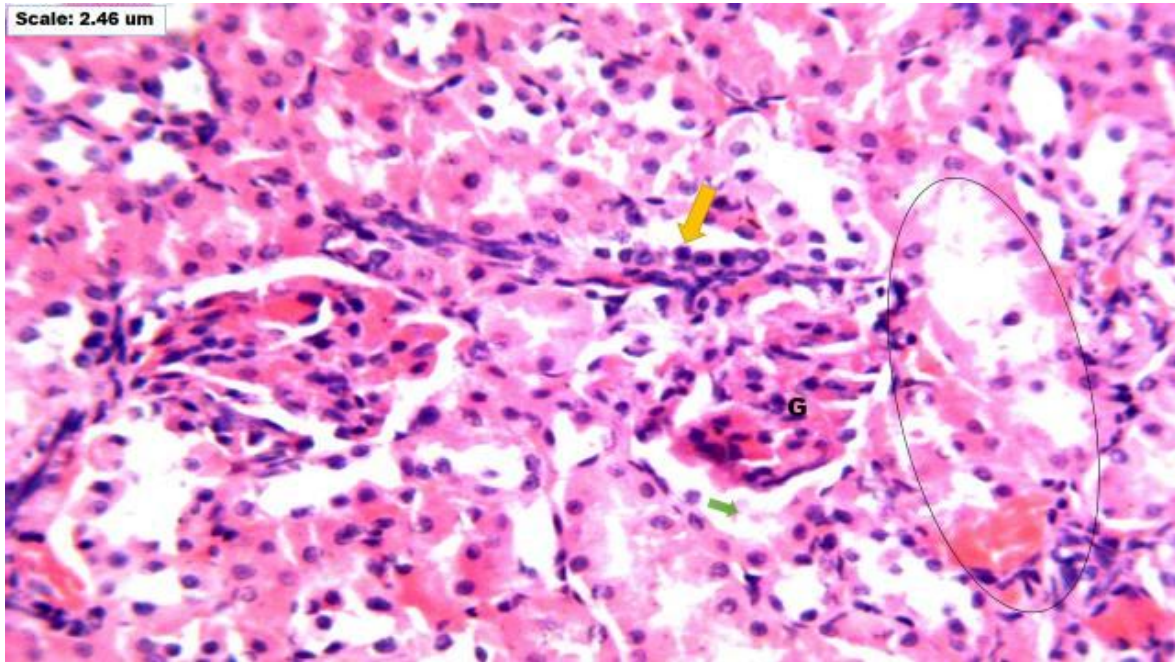


Plate 5: Photomicrograph of coronal section of kidneys of diabetic induced adult Wistar rats. Group 5 (Oral administration of 360 mg/kgbw/day of *Persea Americana* for 14 days). H & E x250

Note: G-Glomerulus, Circle – Dilated proximal and distal convoluted tubules, Yellow arrow – Aggregation of inflammatory cells, Green arrow – Bowman's space

In group VI that had oral administration of 100 mg/kgbw/day of *Metformin*, the renal cortex is markedly haemorrhagic (H) with congestion of blood vessels (green arrow). Notable is the aggregation of inflammatory cells (circle). The proximal and distal convoluted tubules are dilated but are lined with single cuboidal epithelial cells. The glomeruli are undergoing the process of regeneration.

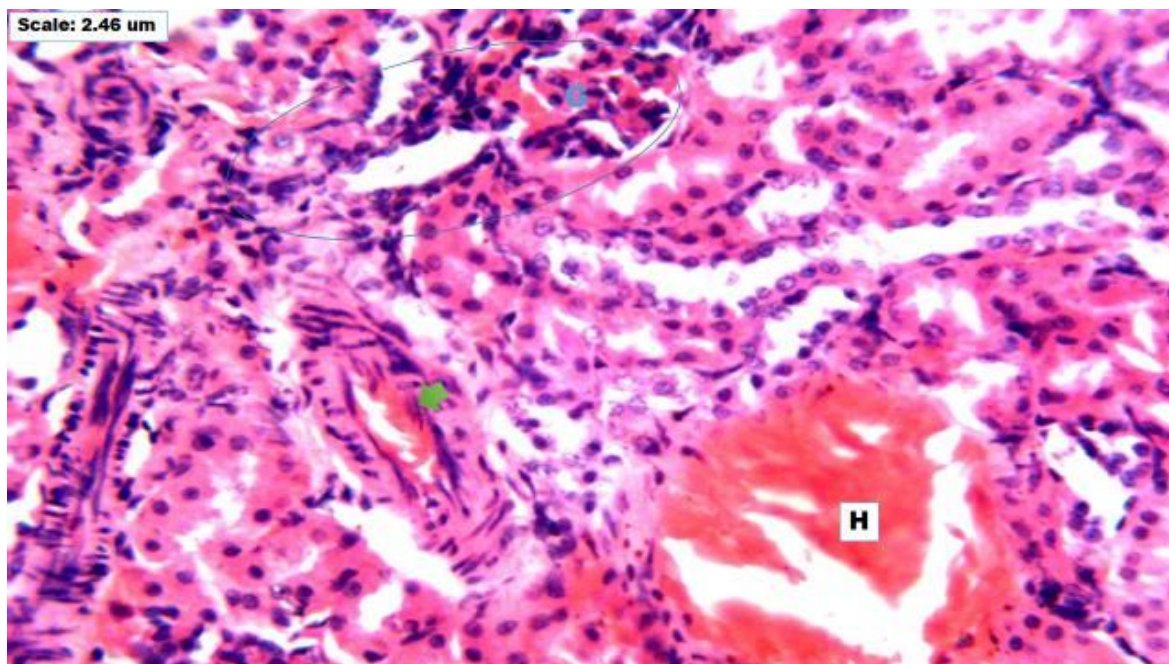


Plate 6: Photomicrograph of coronal section of kidneys of diabetic induced adult Wistar rats. Group 6 (Oral administration of 100 mg/kgbw/day of *Metformin* for 14 days). H & E x250

Note: H - Hemorrhagic congested tissues (H), Green arrow - Congested blood vessels. Circle - Aggregated inflammatory cells

Effect of *Persea Americana* Seed extract on body weight in alloxan induced diabetic male Wistar rats

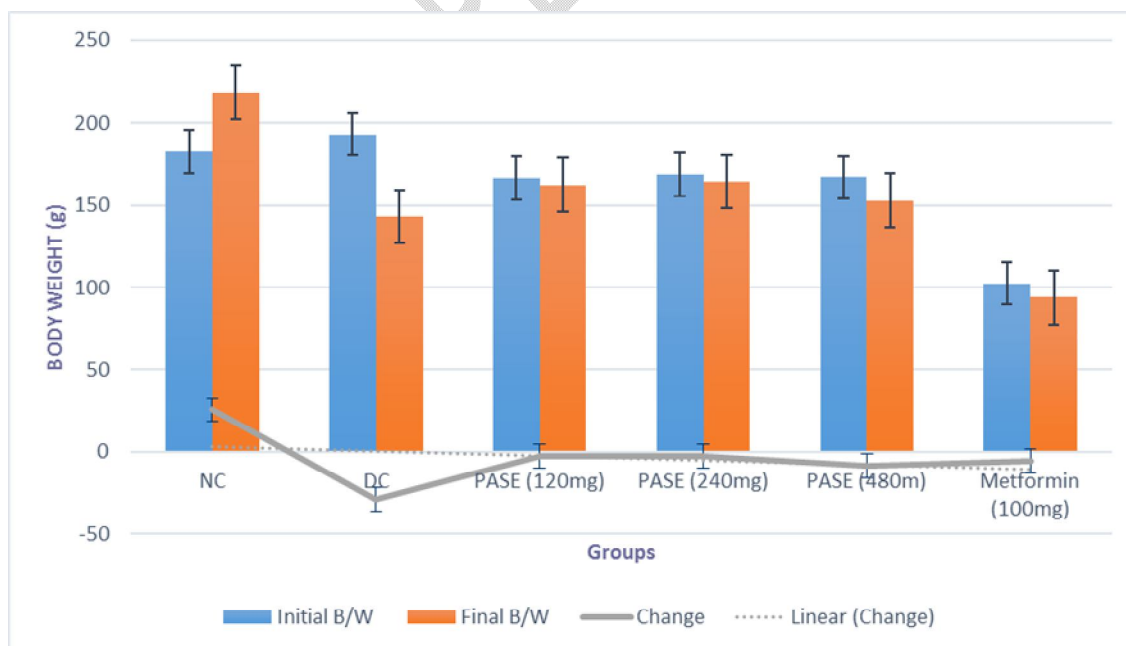


Fig. 1: Graph showing the effect of *Persea Americana* seed extract (120, 240, and 480 mg/kg) respectively and metformin (100 mg/kg) on the body weight in normal and alloxan-Induced diabetic male wistar rats.

Values are expressed as Mean \pm SEM, n=5. *P<0.05, final body weight compared to initial body weight

KEY: NU= Normal Control, DC= Diabetic Control, PASE= *Persea Americana* Seed Extract,

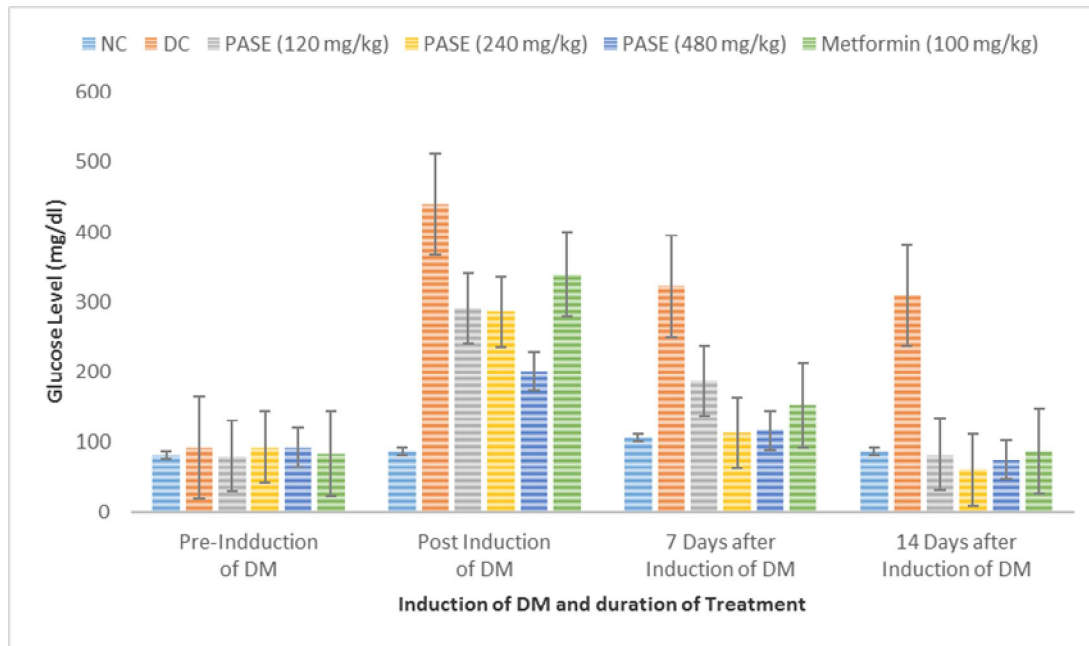


Fig. 2: Graph showing the Effect of *Persea Americana* Seed extract on blood glucose level in alloxan induced diabetic male Wistar rats.

Data are expressed in mean \pm SEM. (n=5).

KEY: NU= Normal Control, DC= Diabetic Control, PASE= *Persea Americana* Seed Extract,

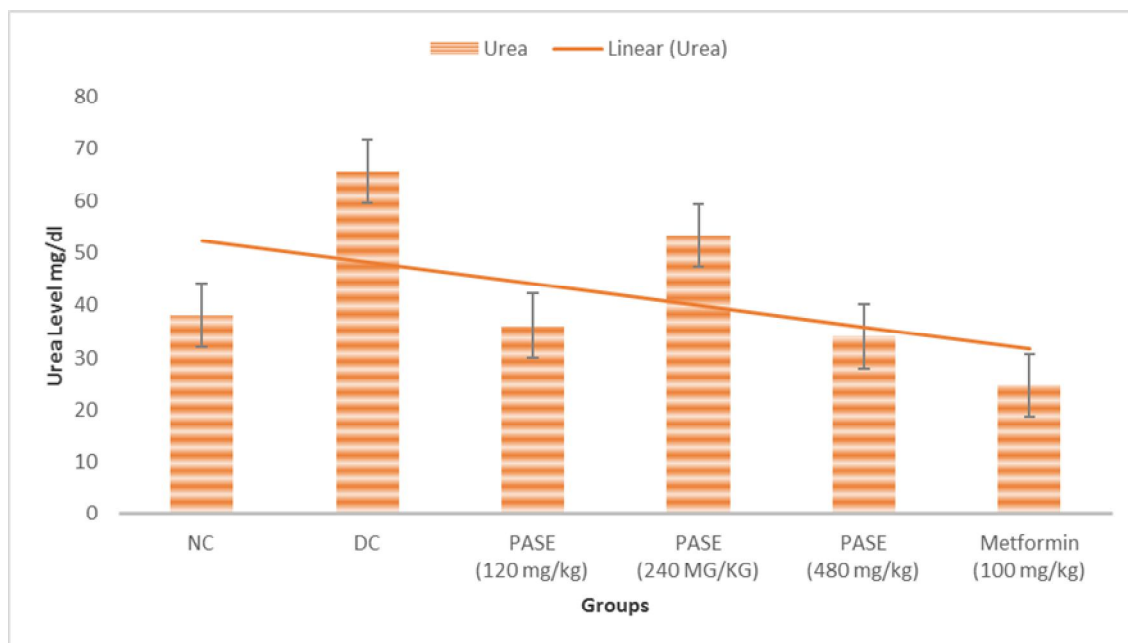


Fig. 3: Graph showing the Effect of *Persea Americana* Seed extract on Urea level in alloxan induced diabetic male Wistar rats.

Values are expressed as Mean \pm SEM, n=5. *P<0.05, non-diabetic control compared to other groups, +P<0.05, diabetic treated groups compared to diabetic control group

KEY: NU= Normal Control, DC= Diabetic Control, PASE= Persea Americana Seed Extract,

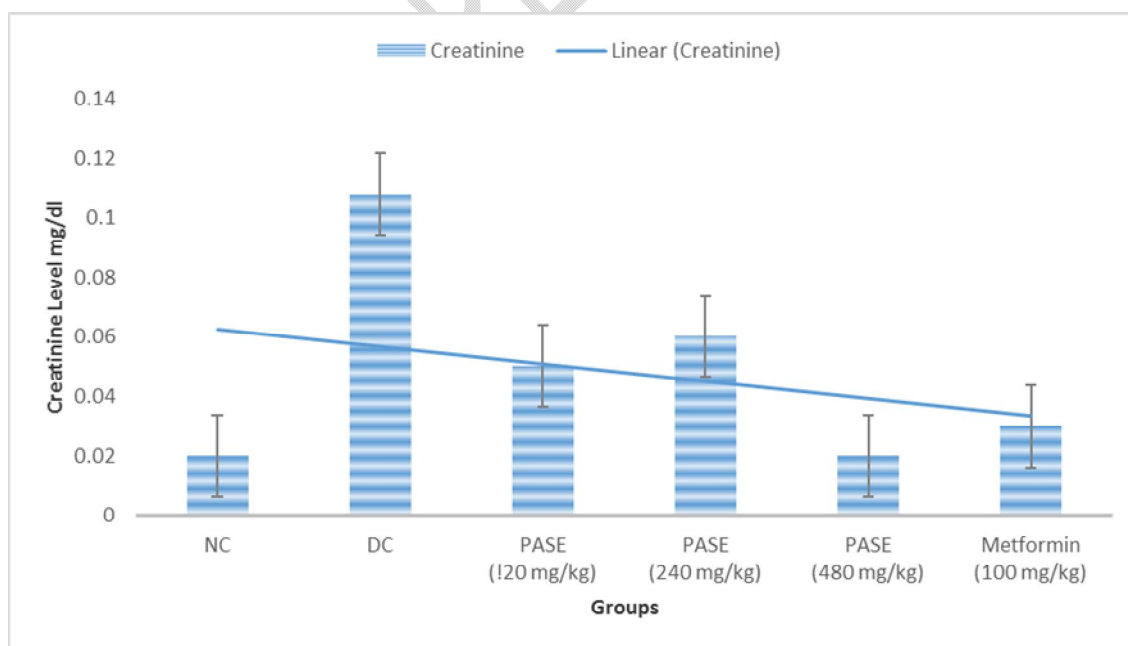


Fig. 4: Graph showing the Effect of *Persea Americana* Seed extract on Creatinine level in alloxan induced diabetic male Wistar rats.

Values are expressed as Mean \pm SEM, n=5. *P<0.05, non-diabetic control compared to other groups, +P<0.05, diabetic treated groups compared to diabetic control group

KEY: NU= Normal Control, DC= Diabetic Control, PASE= Persea Americana Seed Extract,

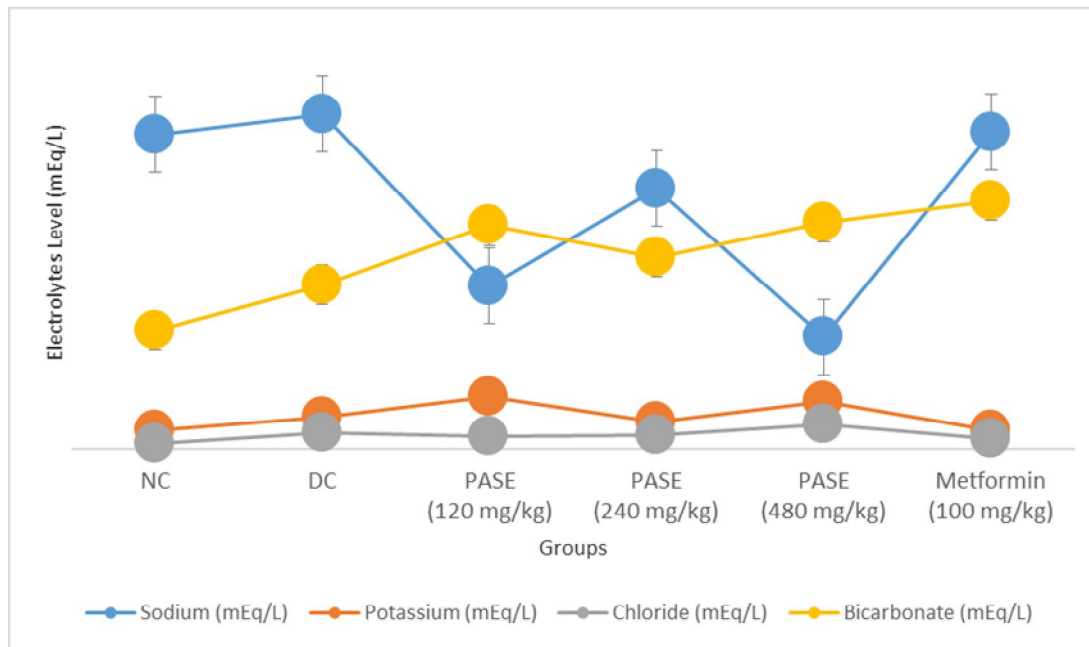


Fig. 5: Graph showing the Effect of *Persea Americana* Seed extract on Electrolytes level in alloxan-Induced diabetic male Wistar rats.

Values are expressed as Mean \pm SEM, n=5. *P<0.05, non-diabetic control compared to other groups, +P<0.05, diabetic treated groups compared to diabetic control group

KEY: NU= Normal Control, DC= Diabetic Control, PASE= Persea Americana Seed Extract,

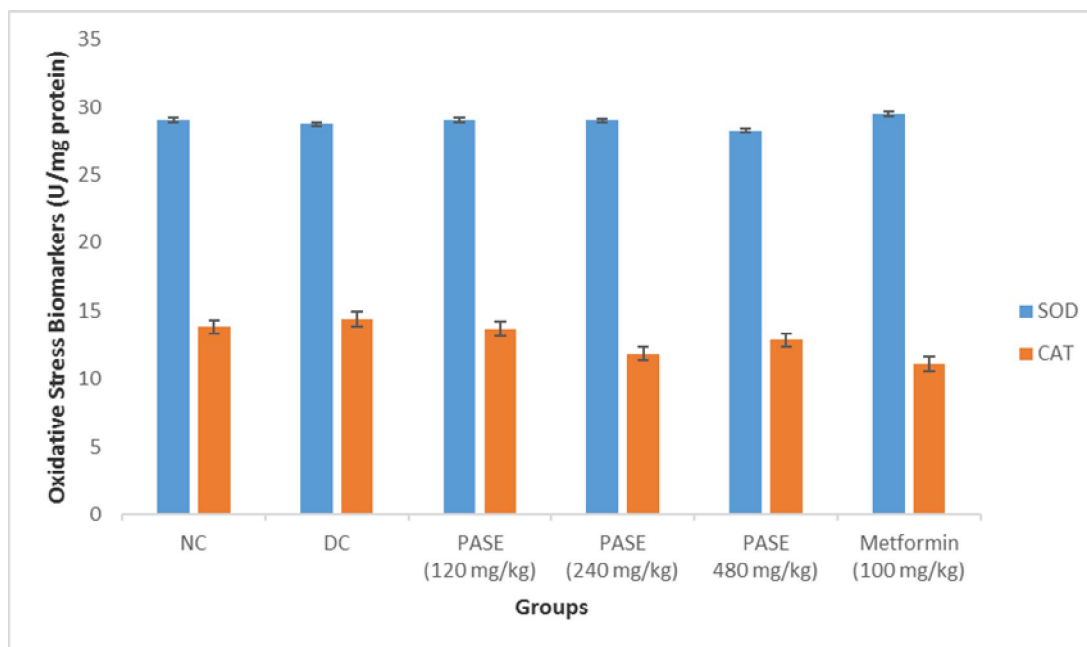


Fig. 6: Graph showing the Effect of *Persea Americana* Seed extract on Oxidative Stress Biomarkers (SOD and Catalase) level in alloxan-Induced diabetic male Wistar rats.

Values are expressed as Mean \pm SEM, n=5. *P<0.05, non-diabetic control compared to other groups, +P<0.05, diabetic treated groups compared to diabetic control group

KEY: NU= Normal Control, DC= Diabetic Control, PASE= Persea Americana Seed Extract,

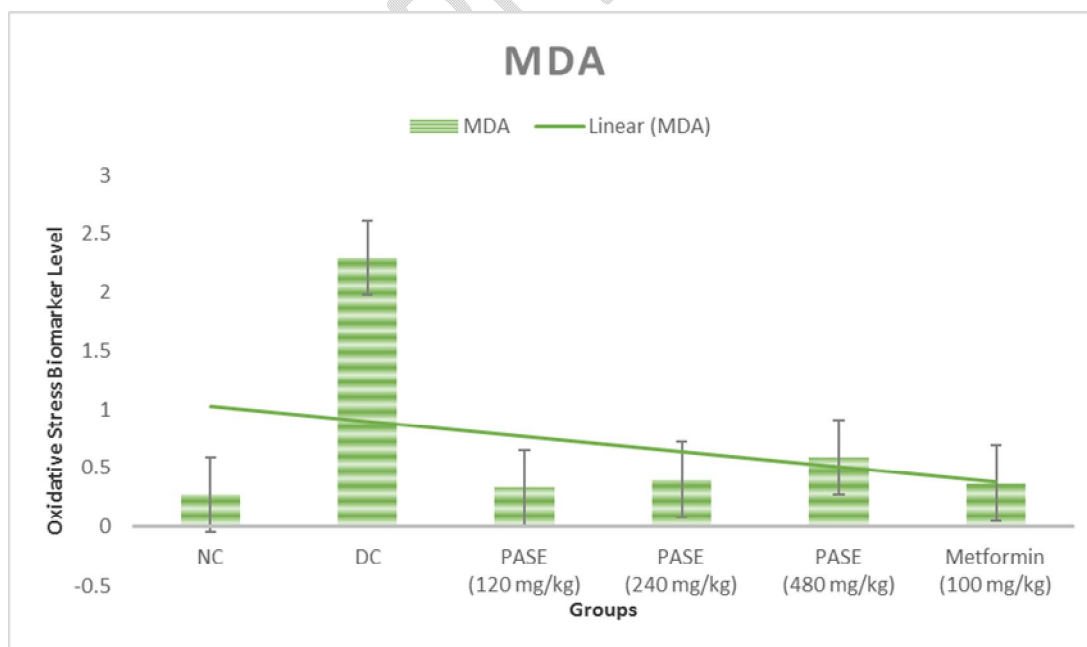


Fig. 7: Graph showing the Effect of *Persea Americana* Seed extract on Oxidative Stress Biomarker (MDA) level in alloxan-Induced diabetic male Wistar rats.

Values are expressed as Mean \pm SEM, n=5. *P<0.05, non-diabetic control compared to other groups, +P<0.05, diabetic treated groups compared to diabetic control group

KEY: NU= Normal Control, DC= Diabetic Control, PASE= Persea Americana Seed Extract,

DISCUSSION

Over the course of the experiment, there was no significant change in food consumption across the groups. The body weights of each group were monitored weekly as a general indicator of overall health. There was a considerable increase in the body weight of normal control rats as compared to their baseline (0 day) body weight. When compared to control rats, *Persea Americana* seed extract (120, 240, and 480 mg/kg) plus Metformin (100 mg/kg) significantly lowered body weight in diabetic rats (figure 1).

Figure 2 shows the blood glucose levels of diabetic animals, which demonstrated a considerable increase levels compared to normal control rats. The diabetic group demonstrated a substantial hypoglycaemic response after 14 days of therapy with *Persea Americana* seed extract (120, 240, and 480 mg/kg) and Metformin (100 mg/kg), with the 240 mg/kg dose having the greatest hypoglycaemic potential. The fact that a moderate dose of *Persea Americana* seed extract can produce hypoglycemia is clearly demonstrated, a report which confirms the findings of (19). Result from our findings confirms that *Persea Americana* has anti-diabetic effects similar to other anti-diabetic plants that have been previously reported (3, 19, 24). Pancreatic cell destruction, which can be managed by islet cell plus bone marrow cell transplantation via portal vein, as well as insulin resistance and inhibition of glucose metabolizing enzymes at cellular membranes, are all documented pathophysiology of diabetes mellitus (19, 24, 32-34).

Our study in figures 3 and 4 show that all diabetic animals have a considerable rise in urea and creatinine; however, the treatment of *Persea Americana* extract significantly reduced the levels of urea and creatinine. The considerable increase in serum urea and creatinine reported in all diabetic groups could be attributed to increased synthesis from injured pancreatic cells produced by alloxan injection rather than kidney injury (35). This is due to the fact that diabetic control rats that were not given the plant extract showed a similar increase in these serum metabolites.

Fluid balance, acid-base balance, neuronal and myocardial function modulation, oxygen delivery, and a number of other biological activities, all require electrolytes (36). Diabetic individuals are more prone to have electrolyte abnormalities, which is likely due to the difficulties they face and the medications they use (36).

In figure 5, there was no significant change in Potassium and bicarbonate ions in all the diabetic group treated with *Persea Americana* Methanolic seed extract, however, significant increase in Na⁺ and Cl⁻ of diabetic group treated with 240 mg/kg body weight of *Persea Americana* Methanolic seed extract and that of group 6 treated with metformin (100 mg/kg) was observed. The difference in serum electrolyte in the extract-treated animals compared to the control group suggests that the extract may have influenced renal function in the rats. Renal function impairment has been linked to changes in serum Na⁺ and K⁺ levels (35).

Figure 6 depicts the findings of this investigation, which revealed that hyperglycemia is associated with a decrease in SOD and catalase activity in renal tissues. Hypoglycemia kills non-enzymatic antioxidant defenses by allowing reactive oxygen species to harm cells and tissues (24). Alloxan's cytotoxicity is mostly due to DNA alkylation, which causes cell necrosis (37). According to the findings of this investigation, treatment with *Persea Americana* seed extract significantly enhances the Catalase and SOD enzymes, as shown in Figure 6. Previous research reports is in confirmation with the findings (38-40).

“Non-enzymatic glycosylation, auto-oxidative glycosylation, and metabolic stress are all mechanisms that lead to increased oxidative stress in diabetes” (41). Increased lipid peroxidation products have previously been observed in STZ-induced diabetic rat tissue, and hyperglycemia is known to enhance

lipid peroxidation, which can cause long-term tissue damage (42). Treatment with *Persea Americana* seed extract significantly decreases MDA concentrations in renal tissue of diabetic rats as shown in figure 7. Changes in antioxidant parameters status have been observed in the renal tissues of the diabetic animals, demonstrating the plant's potential.

Histomorphological features in Control group I, the renal cortex shows the glomerulus (G), proximal (P) and distal convoluted (C) tubules appearing normal and the Bowman's space is well outlined. In this study, group II (Diabetic Control) that was induced with 150 mg of Alloxan intraperitoneally, the renal cortex shows haemorrhagic (H) renal corpuscle with apparently degenerated glomerular tuft (G), infiltrated with inflammatory cells (circles). Most of the tubular cells appear dilated with degeneration of vesicular nuclei (yellow arrow) and there is dilatation of the Bowman's space. Group III which had oral administration of 120 mg/kgbw/day of *Persea Americana* seed extract, the renal cortex shows haemorrhagic renal corpuscle with aggregation of inflammatory cells. The Bowman's space, proximal and distal convoluted tubules appear dilated. Group IV (240mg/kg) of *Persea Americana*, the renal cortex display is haemorrhagic, there is aggregation of inflammatory cells, proximal and distal convoluted tubules are degenerated and dilated, regeneration of the glomerulus and tubules with their single cuboidal epithelial cells) and Group V (480mg/kg), the renal cortex shows sparsely distributed inflammatory cells, Also the renal cortex is not haemorrhagic. There are regenerations of single cuboidal epithelial cells of the proximal and distal convoluted tubules with normal cellular structure. However, there are some degenerating tubules. In group VI that had oral administration of 100 mg/kgbw/day of Metformin the renal cortex is markedly haemorrhagic with congestion of blood vessels. Noticeable is the aggregation of inflammatory cells. The proximal and distal convoluted tubules are dilated but are lined with single cuboidal epithelial cells and the glomeruli are undergoing the process of regeneration. These findings are in agreement with Collins *et al.* (43), who stated that treatment of diabetic induced Wistar rats with *Persea Americana* seed extract restored the histoarchitecture of the damaged kidney to normal as the control rats suggesting that *Persea Americana* extracts reversed the histopathological damage that occurred in alloxan-induced diabetic rats which may provide a pharmacological basis for the traditional use of *Persea Americana* seeds extracts in the management of Diabetes mellitus leading to its potential clinical benefit.

Contribution to Knowledge

1. In this paper, the hypoglycaemic effects of *Persea Americana* seed extract were confirmed.
2. *Persea Americana* seed extract has a strong antioxidant capacity, which may boost its anti-diabetic benefits.
3. Infected animals' kidney tissues were observed to be recovered from the harmful effects of alloxan induction (the administration of Metformin (100mg/kg) and *Persea Americana* seed extract 120, 240, and 480mg/kg, respectively).
4. The structural abnormalities in the kidneys could be due to diabetic Rasch's altered metabolism, which has an effect on the raised renal threshold for hyperglycaemia. There are regenerations of glomeruli and single cuboidal epithelial cells of the proximal and distal convoluted tubules with normal cellular structure in groups four and five that had 240mg/kg and 480mg/kg of *Persea Americana* respectively which may lead to potential clinical usefulness.

Conclusion

In diabetic treated animals, the methanolic seed extract of *Persea Americana* showed significant anti-diabetic activity by lowering blood glucose, urea, and creatinine levels, increasing Na and Cl ions levels, SOD and Catalase activities, decreasing MDA activities and regenerations of glomeruli and single cuboidal epithelial cells of the proximal and distal convoluted tubules with normal cellular structure of the kidney, with the group given 240 mg/kg of *Persea Americana* seed extract having the highest potency.

Ethical approval

Ethical approval was sought and obtained from the Ethics and Research Committee of the Department of Human Anatomy and Cell Biology, Faculty of Basic Medical Sciences, Delta State University, Abraka, Nigeria with Ref. No. DELSU/CHS/ANA/2020/55.

Recommendation

The outcomes of this study suggest that *Persea Americana* has significant anti-diabetic activity; nevertheless, electrolyte imbalances must be considered while treating diabetic patients, as early detection could reduce the chances of getting a variety of ailments. However, further research is needed to isolate and determine the specific chemicals found in *Persea Americana* seed extract that are responsible for these positive effects.

References

1. Andy KH Lim (2014). Diabetic nephropathy – complications and treatment. *Int J Nephrol Renovasc Dis.* 7: 361-381
2. Foley, R.N. and Collins, A.J. (2009). “The growing economic burden of diabetic kidney disease,” *Current Diabetes Reports*, 9 (6): 460–465.
3. Ojeh A.E. (2020). Evaluation of Antidiabetic and Antioxidant potential of *Nephrolepis unduranta* leaf extract in Streptozotocin Induced Diabetic Wistar Rats; *Int. J of Forensic Med Invest.*, 5 (1): 34-41.
4. Bruno, G., Merletti, F., Biggeri, A. (2005). “Fibrinogen and AER are major independent predictors of 11-year cardiovascular mortality in type 2 diabetes: the Casale Monferrato Study,” *Diabetologia*, 48(3): 427–434.
5. Allen, K.V and Walker, J.D. (2003). “Microalbuminuria and mortality in long-duration type 1 diabetes,” *Diabetes Care*, 26(8): 2389–2391.
6. Tervaert, T.W.C., Mooyaart, A.L., Amann, K. (2010). “Pathologic classification of diabetic nephropathy,” *Journal of the American Society of Nephrology*, 21(4): 556–563.
7. Pradeep Kumar Dabla (2010). Renal function in diabetic nephropathy. *World J Diabetes*, 1(2): 48–56.
8. United States Renal Data System. USRDS 2007 Annual Data Report. Bethesda, MD: National Institute of Diabetes and Digestive and Kidney Diseases, National Institutes of Health, U.S. Department of Health and Human Services. 2007
9. National Institute of Diabetes and Digestive and Kidney Diseases. National Diabetes Statistics, 2007. Bethesda, MD: National Institutes of Health, U.S. Department of Health and Human Services. 2008.
10. Ramachandran A. (2005). Epidemiology of diabetes in India--three decades of research. *J Assoc Physicians India*, 53:34–38.
11. Ramachandran A. (2007). Socio-economic burden of diabetes in India. *J Assoc Physicians India*, 55 (1):9–12.
12. Molitoris BA. (2007). Acute kidney injury. In Goldman L, Ausiello D, editors. *Cecil Medicine*. 23rd ed. Philadelphia, Pa: Saunders Elsevier; p. chap 121.
13. Guyton AC and Hall JE (2011); *Textbook of Medical Physiology*, 12th Edition, 2010 Elsevier, New Delhi, India: 971-976
14. Goldberg A, Hammerman H, Petcherski S, Zdorovyak A, Yalonetsky S, Kapeliovich M, Agmon Y, (2004). Prognostic importance of hyponatremia in acute ST-elevation myocardial infarction. *Am J Med*, 117(4):242-248.
15. George Liamis, Evangelos Liberopoulos, Fotios Barkas, and Moses Elisaf (2014). Diabetes mellitus and electrolyte disorders. *World J Clin Cases.*, 2(10): 488–496.

16. Liamis G, Kalogirou M, Saugos V, Elisaf M. (2006). Therapeutic approach in patients with dysnatraemias. *Nephrol Dial Transplant*, 21:1564–1569.
17. Wattieza, Stein, W. E.; Mannolini, F.; Hernick, L. V.; Landling, E.; Berry, C. M. (2007). "Giant cladoxypsid trees resolve the enigma of the Earth's earliest forest stumps at Gilboa". *Nature*. 446 (7138): 904–907.
18. Adeyemi OO, Okpo SO, Ogunti, OO. (2002). Analgesic and anti-inflammatory effects of some aqueous extracts of leaves of *Persea americana* Mill (Lauraceae). *Fitoterapia*; 73:375-380.
19. Wilson Josiah Iju; Ojeh Anthony Emeka; Ossai Nduka Richard; Nwogeze Bartholomew Chukwuebuka and Olise-Enewe Maryann (2021). Histomorphological, Hypoglycaemic and Hepatoprotective effects of acute administration of Methanolic extract of *Persea americana* seed in alloxan-induced Diabetic Wistar Rats. *Plant Cell Biotechnology and Molecular Biology* 22(41&42):247-260.
20. Muchandi, I.S. (2005). Hypoglycemic activity of aqueous leaf extract of *Persea americana* Mill. National Seminar on Emerging Trends in Ethnopharmacology. *Indian J Pharmacol*. 37(5):325-326
21. Ekam V. S., Ebong P. E., Johnson J. T., Dasofunjo, K (2013). Effect of Activity Directed Fractions of *Vernonia amygdalina* on Total Body Weight and Blood Glucose Levels of Diabetic Wistar Albino Rats. *International Journal of Science and Technology*2(1):153-157
22. Eduardo P-C, Moisés M-V, José Miguel F-F, and Socorro V-R (2013): Acute Toxicity and Genotoxic Activity of Avocado Seed Extract (*Persea americana* Mill., c.v. Hass). *The Scientific World Journal* Volume 2013, Article ID. 245828, [bhttp://dx.doi.org/10.1155/2013/245828](http://dx.doi.org/10.1155/2013/245828)
23. American Diabetes Association (2014). Diagnosis and Classification of Diabetes Mellitus. *Diabetes Care*; 37(1):S81-S91.
24. Ossai, NR; Ojeh, EA; Nwogeze, CB, Olowe, GT and Ajayi, ER (2021). Ameliorative Potentials of Methanolic Leaf Extract of *Nephrolepis undulate* in Streptozotocin-Induced Diabetic Wistar Rats. *Plant Cell Biotechnology and Molecular Biology* 22 (15 and 16):41-53.
25. Fischer AH, Jacobson KA, Jack R, Rolf Z. (2008): Hematoxylin and eosin staining of tissue and cell sections. PMID: 21356829 DOI: 10.1101/pdb.prot4986
26. Adekomi D. A., (2010) "Madagascar Periwinkle (*Catharanthus roseus*) Enhances Kidney and Liver Functions in Wistar Rats," *International Journal of Biomedical and Health Sciences*, 6(4):245-254.
27. Grindler, E and Health, D (1971); Determination of sodium in body fluid, *Clinical Chemistry*.17:662.
28. Terri, A.E. and Sesin, P.G. (1958). Determination of serum potassium by using sodium tetraphenylboron. *Am. J. Clin. Path.* 29:86- 90.
29. Misra HP and Fridovich I. (1972) The role of superoxide anion in the autoxidation of epinephrine and a simple assay for superoxide dismutase. *J Biol Chem.*; 247(10):3170–3175
30. Cohen G, Mimi K, Vivian O. (1996) a modified catalase assay suitable for a plate reader and for the analysis of brain cell cultures. *Journal of Neuroscience Methods*, 670(1): 53-56.
31. Gutteridge JM and Wilkins S. (1982). Copper-dependent hydroxyl radical damage to ascorbic acid: formation of a thiobarbituric acid-reactive product. *FEBS Lett.* 25; 137(2):327-330.
32. Ikebukuro K, Adachi Y, Yamada Y, Fujimoto S, Seino Y and Oyaizu H. (2002). "Treatment of streptozitocin-induced diabetes mellitus by transplantation of islet cells plus bone marrow cells via portal vein in rats. *Transplantation*, 73(4):512-518
33. Bhanderi MR, Jong-Anurakkun N, Hong G, Kawabata J. (2008). "Alpha-glucosidase and alpha-amylase inhibitory activities of Nepalese medicinal herb pakhanbhed (*Bergenia ciliata*; Haw). *Food Chemistry*, 106: 247-252.

34. Ibrahim MA, Koorbanaly NA, Islam MS. (2014). "Antioxidant activity and inhibition of key enzymes linked to type-2 diabetes (α -glucosidase and α -amylase), by Khaja Senegalensis. *Acta Pharmaceutica*, 64: 311-324.
35. Adesokan Ayoade A, Oyewole Oluwole and Turay Babara MS. (2009). Kidney and Liver Function Parameters in Alloxan-Induced Diabetic Rats Treated with Aloe Barbadensis Juice Extract. *Sierra Leone J Biomed Res*; **1** (1):33-37
36. Deepti, GN., Sumina, Cherian, Lakshmi, K. (2017). A comparative study of electrolyte imbalances in controlled and uncontrolled diabetes mellitus. *International Journal of Clinical Biochemistry and Research* 4(1):22-24
37. Ojeh, AE; Ugorji AE; Ovuakporaye IS; Ewhre OL; Ossai NR. (2016). "Comparative Evaluation of Hypoglycemic Properties of Raw and Boiled *Allium cepa* in Alloxan- Induced Diabetes Mellitus Rats. *UK Journal of Pharmaceutical and Biosciences*, 4(3), 38-44
38. Hsieh, C.W., J.Y. Cheng, T.H. Wang, H.J. Wang and W.J. Ho, (2014). Hypoglycaemic effects of *Ajuga* extract *in vitro* and *in vivo*. *J. Funct. Foods*, 6: 224-230.
39. Udoamaka F. Ezuruiken, Jose M. Prieto (2014). The use of plants in the traditional management of diabetes in Nigeria: Pharmacological and toxicological considerations. *Journal of Ethnopharmacology* 155:857-924.
40. Houda Ben Jemaa, Sarra Khelifi, Halima Ben Hmed, Inchirah Karmous, Anis Benzarti, Jalila Elati and Abdallah Aouidet (2015). Antidiabetic, Antihyperlipidemic and Antioxidant Effects of *Artemisia herba Alba* Extract on Experimental Diabetes *International Journal of Pharmacology*. 11 (6): 552-560.
41. Gandhi S, Sangeetha G, Ahmed N, Chaturvedi SK. (2014). Somatic symptoms, perceived stress and perceived job satisfaction among nurses working in an Indian psychiatric hospital. *Asian J Psychiatr.* 12:77-81.
42. Rahimi R, Nikfar S, Larijani B, Abdollahi M. (2005). A review on the role of antioxidants in the management of diabetes and its complications. *Biomedical Pharmacotherapy*.59:365-373
43. Collins N. Ejiofor, Ikechiowue Ezeagu, Moses Ayoola and Peter U. Acihukwu (2017). Histopathological effect of aqueous extract of *Persea Americana* seed on alloxan - induced diabetic rats. *Journal of pharmacognosy and phytochemistry* 7(1): 795-799.
44. Andrew H Fischer, Kenneth A Jacobson, Jack Rose, Rolf Zeller (2008): Hematoxylin and eosin staining of tissue and cell sections. PMID: 21356829 DOI: 10.1101/pdb.prot4986