

Original Research Article

ASSESSMENT OF THE EFFECT OF NEEM EXTRACT (*Azadirachta indica*) ON ALUMINIUM PHOSPHIDE INDUCED TOXICITY IN ADULT WISTAR RAT

Abstract

Aluminum phosphide (ALP) which is locally called rice tablet is a known fumigant used in grain storage facilities with a greenish-gray tablet that has a rotten fish or garlic odor. Rice tablets contain ALP, urea, and ammonium carbamate, which through contact with water, steam, and gastric acid produce phosphine gas (PH_3). This research was carried out to investigate the effect of neem extract on aluminum phosphide-induced toxicity in the liver of albino Wistar rats and also to evaluate the effect of neem leaf extract on hematological parameters in aluminum phosphide-induced toxicity in adult wistar rat. Thirty (30) adult male Wistar rats were grouped into five (5) groups (A-E). Group A served as the control group, Group B received aluminum phosphide only, Group C received aluminum phosphide and 200mg neem extract and Group D received aluminum phosphide and 400mg neem extract Group E neem extract only. Hematoxylin and Eosin staining technique was used to study the histological morphology of the liver. Hematological investigations were also carried out. From the result obtained, white blood cells neutrophils, hemoglobin and red blood cells were reduced while platelet and lymphocyte were increased. Result shows that the group which took a higher dose of neem extract had less damage to the liver cell compared to those that took a lesser dose and aluminium phosphide alone respectively. Hence, it can be inferred that neem extract does not completely ameliorate hepatotoxicity of aluminium phosphide.

INTRODUCTION

Aluminum phosphide (ALP) which is locally called rice tablet is a known fumigant used in grain storage facilities with a greenish-gray tablet that has a rotten fish or garlic odor. Rice tablets contain ALP, urea, and ammonium carbamate, which through contact with water, steam, and gastric acid produce phosphine gas (PH_3). Phosphine gas is highly toxic, flammable, and a protoplasmic poison (Dorooshiet *al.*, 2018). The lethal dose (LD_{50}) is 11.5 mg/kg and the estimated time intervals beginning from the ingestion of its tablet to death have approximately been reported as 3 hours, or on an average, between 1-48 hours, with the most common cause of death being cardiac arrhythmias. 95% of the patients die within 24 hours of ingestion of AIP (Chughet *al.*, 1993). Upon contact with moisture in the environment, ALP undergoes a chemical reaction yielding phosphine gas, which is an active pesticidal component. Phosphine inhibits

cellular oxygen utilization and can induce lipid peroxidation. This highly toxic chemical is cheap and usually formulated in tablets or pellets, granules, and dust. Upon contact with moisture in the environment, it undergoes a chemical reaction yielding phosphine gas, which is the active pesticidal component, (Sudakin, 2005). It emerges as a poison for suicidal deaths as this pesticide has no effective antidote and is freely available on the market, (Singh *et al.*, 2003). Aluminum phosphide poisoning is a common mode of suicide in the agricultural community in northern India, (Ranga *et al.*, 2004). It has currently aroused interest with an increasing number of cases in the past four decades due to increased use for agricultural and non-agricultural purposes, and also its easy availability has increased its misuse to commit suicide (Bajpai *et al.*, 2010) and (Ferrer *et al.*, 2009). Unfortunately, it is rapidly becoming a very commonly used agent for self-poisoning in Iran (Mehrpouret *et al.*, 2010; Shadniaet *et al.*, 2009; Soltaninejad *et al.*, 2007).

Also, in a 25-yearlong study reported by Singh *et al* (2003), a total of 5933 unnatural deaths by poisoning were reported in north-west India, and aluminium phosphide was found out to be a major cause (Berry *et al*, 2015).

Neem also called Neem, (*Azadirachta indica*) popularly known by the northerners as Dogon Yaro is a medicinal tree whose tree bark and leave are of medical and nutritional significance in the body, most frequently its root and flower, and fruits are also used. The fruit is used for intestinal worms, urinary tract disorders, the bark is for intestinal ulcers, skin disease, then the flower is used to reduce bile, etc. It is believed to be native to the Indian subcontinent (Girish and Shankara, 2008), Senegal (Orwaet *et al.*, 2009), in the tropical, semitropical region of India, Pakistan, Bangladesh, and Nepal has a therapeutic implication in disease cure (Brahmachariet *et al.*, 2004). The neem leaf has a botanical name called *Azadirachta Indica*, a member of the Meliaceae family. It has been reported to boost the immune system of humans, and several animals and fish species (Mukesh *et al.*, 2012; Kwawukume *et al.*, 2013; Shailenderet *et al.*, 2013). It's also reported that the neem plant has antibacterial, antifungal, antiviral, and pesticidal activities, while at the same time improving general growth and health performance, with no

toxic effect on vital organs (Harikrishnan *et al.*, 2003). The leaf constituent has been denoted to play a vital role in the scavenging of free radicals to rich source of antioxidants, also in the management of cancer through the regulation of cells signaling pathway, prevention of disease pathogenesis. It modulates the activities of various tumor suppressor genes e.g. p53, pTen, transcription factors e.g. NFkB, etc. Additional neem components that have been characterized show similar suppressive effects on the growth and proliferation of tumor cells. For example, treatment with NLE or neem-derived gedunin decreases proliferation of pancreatic or ovarian cancer cells, respectively (Kamath *et al.*, 2009). This leaf also plays a vital role in anti-inflammation, via the regulation of proinflammatory enzyme activities including cyclooxygenase (COX), and lipoxygenase (LOX) enzymes, (Liaw *et al.*, 1997). Some of the components of the neem leaf are; protein 71%, carbohydrate 22.9%, minerals, calcium, phosphorous, vitamin c, carotene, etc. But also include; glutamic acid, tyrosine, glutamine, aspartic acid, alanine, amino acid, and several fatty acids (Maramba, 2011). According to the studies from ethnomedicine, combination of neem and tulsi commonly known as holy basil similar to neem. It's beneficial to lower blood pressure levels due to their active compounds, (Kalaivani, 2009). The leaves are loaded with Flavonoid, Triterpenoid, Anti-viral compounds, and Glycosides, which may help manage blood sugar levels and ensure there is no surge in glucose, (Almeida, 2012).

This research was carried out to investigate the effect of neem extract on aluminum phosphide-induced toxicity in the liver of albino Wistar rats and also to evaluate the effect of neem leaf extract on hematological parameters in aluminum phosphide induced toxicity in adult Wistar rat

MATERIALS AND METHOD

Study Area

The study was conducted in the department of Medical Laboratory Science, Faculty of Basic Medical Sciences, College of Health Sciences, Niger Delta University, Wilberforce Island, Bayelsa State under the approval of the departmental ethics and research committee.

Substance of Study

Aluminum Phosphide

The aluminum phosphide tablets were purchased in the nearby market.

Neem Extraction

Neem was purchased commercially and identified in the pharmacognosy department of Niger Delta University. The leaf was assigned a voucher no PH/NDU/124 after successful identification and the specimen sample was deposited in the herbarium. The leaf of the plant was selected based on the research work by Liawet *al.*, 1997. The leaves were dried and ground into a powder of about 50g and mixed with 100ml of methanol. The mixture was filtered with Whitman's number 1 filter paper and Soxhlet extraction method was used for its extraction.

Vehicle

The vehicle used here was olive oil. It was used to dissolve the aluminum phosphide since water cannot be used to dissolve the aluminum phosphide because aluminum phosphide reacts with water to release phosphine gas. 2.1g of aluminum phosphide tablet was dissolved in 103ml of olive oil. (Eric E U et al., 2021)

Experimental Animals

Thirty (30) adult male Wistar rats weighing 80-160g were purchased from Daltom's animal farm, Swalli, Yenagoa, Bayelsa State and moved to the animal house of the department of Medical Laboratory Science, Niger Delta University, Amassoma, Bayelsa State, Nigeria where they were housed under a standard condition of temperature (27 ± 2 °C) with twelve hours light/dark periodicity in plastic cages. The rats were acclimatized to the environment for two

weeks and were fed on libitum during this period, with water and super starter feed. Animals were handled throughout the period of study according to institutions' guidelines for an experiment involving the use of laboratory animals.

Substance Administration

Animals were weighed and grouped into five (5) groups, with seven (6) rats in the group from groups A to E. All the groups were fed with feed (Super starter feed) Plus water was given ad libitum. However, group A (Control) received distilled water and feed (Super starter feed) only, and test Group B received a 14mg/kg dose of aluminum phosphide. Group C received a combination of 14mg/kg aluminum phosphide + 200mg/kg of Neem extract. Group D received a combination of 14mg/kg aluminum phosphide + 400mg Neem extract. Finally, Group E received 400mg/kg of Neem extract only as described by (Eric et al.,2021).

Route of administration

The oral route of drug administration was employed. Administration of the drug was done through the use of an Orogastric tube.

Sample Collection

At the end of three weeks of administration, the rats were sacrificed by administering chloroform as anesthesia. The rats were then dissected to harvest the stomach which was then fixed immediately in 10% neutral formalin.

Tissue Processing

This is a chain reaction where the tissue was allowed to pass through different changes of chemicalsto prepare the tissues for subsequent treatment. The fixed tissues were subjected to secondary fixation, dehydration, clearing, and impregnation steps. The process was aimed at the production of ultra-section.

Collection of blood samples

All experimental rat was sacrificed at the end of the experiment, by anesthetizing them with chloroform, and collection of blood samples were done using 5ml syringes with 21G needles. The samples were collected from the animals through the cardiac puncture into pre-labeled ethylenediaminetetracetate (EDTA) vials and gently agitated to ensure EDTA is spread uniformly after which the samples were immediately used for measurement of hematological parameters like the total Red blood cell count, hemoglobin concentration, packed cell volume (PCV), differential white blood cells, total WBC, MCH, MCV, and MCHC.

Measurements of hematological parameters

Hematological parameters were measured using an automated hematology analyzer (Coulter Electronics, Luton, Bedfordshire, UK) having standard calibrations in line with the instructions of the manufacturer. Parameters measured were: Red blood cell count, WBC count, differential WBC (lymphocytes count, eosinophils, basophils, and monocytes) count, PCV, MCV, MCH, MCHC, and platelet count.

Principle: The requisite condition for the cell counting method is the high dilution of the sample so that a minimal number of cells pass through the aperture at one point time. There are 2 electrodes on either side of the aperture; as the solution in which the cells are suspended in an electrolyte solution, an electric current is generated between the two electrodes. When a cell passes through this narrow aperture across which a current is flowing, a change in electric resistance (i.e. momentary interruption of electrical current between the two electrodes) occurs. A small pulse is generated due to a temporary increase in impedance. This pulse is amplified, measured, and counted.

An anticoagulated whole blood sample is aspirated into the system, divided into two portions, and mixed with the diluent. One dilution is passed to the red cell aperture bath (for red cell and platelet counting), and the other is delivered to the WBC aperture bath (where a reagent is added for lysis of red cells and release of hemoglobin; this portion is used for leukocyte counting followed by estimation of hemoglobin). Particles between 2-20 fl are counted as platelets, while those between 36-360 fl and counted as red cells.

Statistical Analysis

Results were expressed as mean \pm standard error of the mean (SEM). Computer software. SPSS (version 17.0) was used for data analysis. Statistical measures used were one-way analysis of variance (ANOVA) along with a post hoc multiple comparison test (least square difference procedure). Values of $p < 0.05$ were the criterion for statistical significance

RESULT AND DATA ANALYSIS

Table 1: Mean \pm Standard Deviation (SD) of the Red blood cell indices among the groups

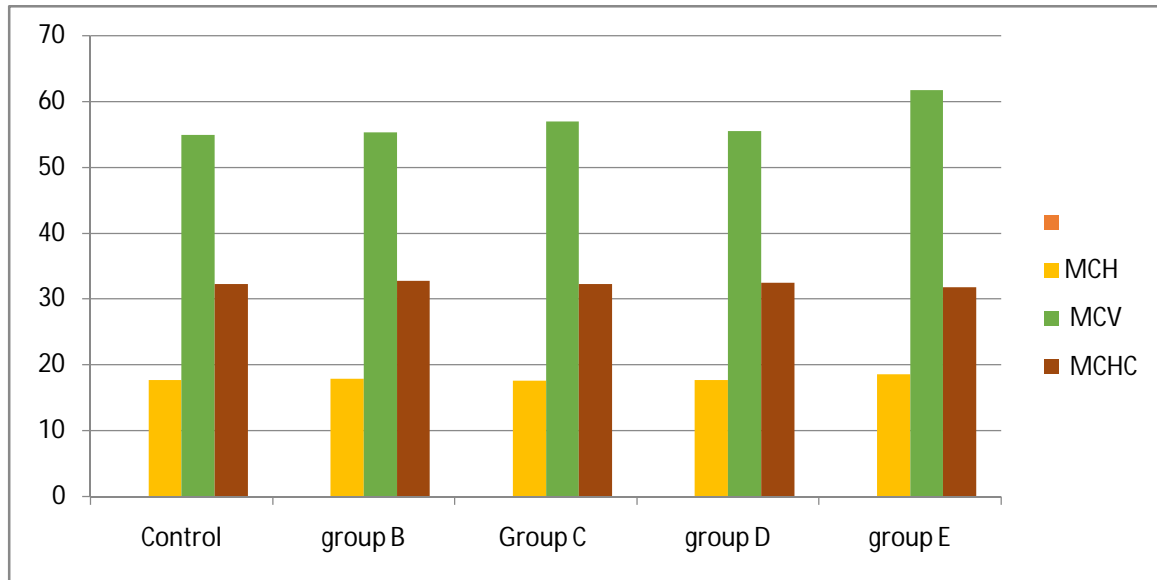
Parameters	Control	group B	group C	group D	Group E
	mean \pm SD	mean \pm SD	mean \pm SD	mean \pm SD	mean \pm SD
MCH	17.65 \pm 0.58	17.90 \pm 0.42	17.57 \pm 0.32	17.70 \pm 1.02	18.55 \pm 1.15
MCV	54.96 \pm 2.59	55.32 \pm 1.79	57.01 \pm 2.93	55.55 \pm 3.89	

	61.78 ± 3.78			
MCHC	32.28 ± 1.31	32.73 ± 0.95	32.23 ± 0.45	32.45 ± 1.05
	31.75 ± 0.99			

MEAN OF RED BLOOD CELL INDICES

Fig 1: Graph for the mean of Red Blood Cell indices among the groups

MEAN OF RED BLOOD CELL



RED BLOOD CELL INDICES

UNDER PEER REVIEW

Table 2: Mean \pm Standard Deviation (SD) of the white Blood cell parameters among the groups

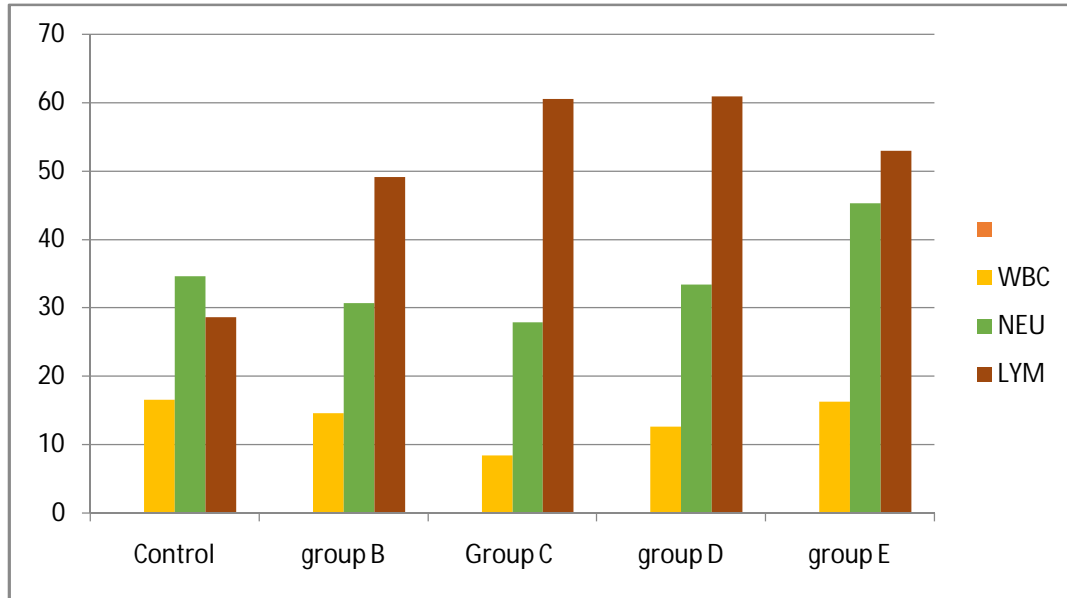
Parameters	Control	group B	group C	group D
Group E				
	mean \pm SD	mean \pm SD	mean \pm SD	mean \pm SD
mean \pm SD				
WBC	16.58 \pm 3.16	14.63 \pm 3.16	8.41 \pm 0.98	12.67 \pm 3.05
	16.28 \pm 1.57			
NEU	34.67 \pm 10.03	30.66 \pm 3.83	27.93 \pm 7.13	33.43 \pm 21.41
	45.32 \pm 11.87			
LYM	28.68 \pm 25.28	49.13 \pm 29.99	60.53 \pm 12.18	60.93 \pm 24.20
	52.95 \pm 10.51			
MONO	1.02 \pm 1.07	1.73 \pm 2.72	5.27 \pm 1.42	7.36 \pm 1.70
	7.25 \pm 2.97			
EOS	0.83 \pm 0.60	0.51 \pm 0.27	1.13 \pm 0.78	1.73 \pm 0.37
	1.30 \pm 0.70			
BASO	0.53 \pm 0.42	0.58 \pm 0.45	0.73 \pm 0.64	0.35 \pm 0.44
	0.93 \pm 0.12			

MEAN OF WHITE BLOOD CELL PARAMETERS

MEAN OF

Fig. 2: Graph for the mean for white Blood cell parameters among the groups

MEAN OF WHITE BLOOD CELL PARAMETERS



WHITE BLOOD CELL PARAMETERS

UNDER PEER REVIEW

Table 3: Mean \pm Standard Deviation (SD) of the Haematological parameters among the groups

Parameters	Control	group B	group C	group D	Group E
	mean \pm SD	mean \pm SD	mean \pm SD	mean \pm SD	mean \pm SD
HB	12.25 \pm 1.22	12.43 \pm 0.33	9.67 \pm 2.54	13.25 \pm 0.68	13.15 \pm 1.51
PCV	34.83 \pm 3.21	39.10 \pm 1.33	34.27 \pm 2.54	37.80 \pm 3.66	42.08 \pm 4.97
RBC	6.39 \pm 0.87	7.02 \pm 0.07	5.57 \pm 1.71	7.18 \pm 0.57	7.28 \pm 1.06
PLT	603.17 \pm 115.13	811.00 \pm 87.84	605.00 \pm 209.42	953.25 \pm 118.94	748.50 \pm 75.91

MEAN OF HAEMATOLOGICAL PARAMETERS

Fig 3: Graph for the mean of haematological parameters among the groups

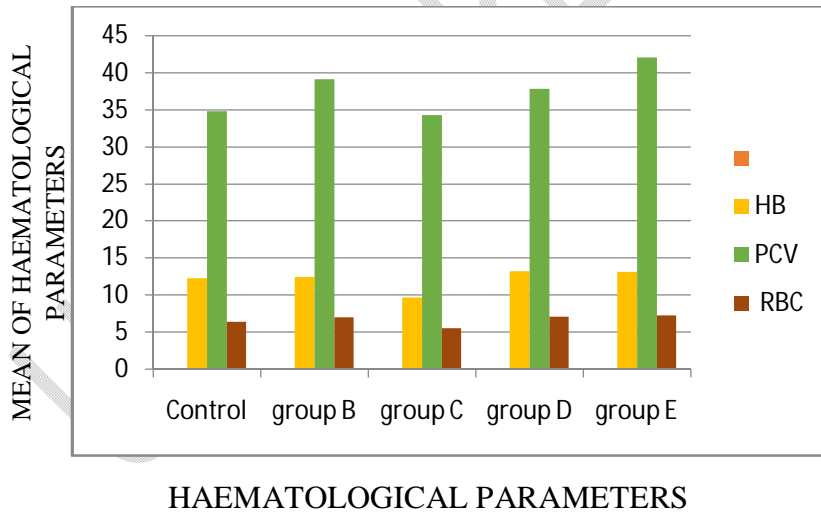
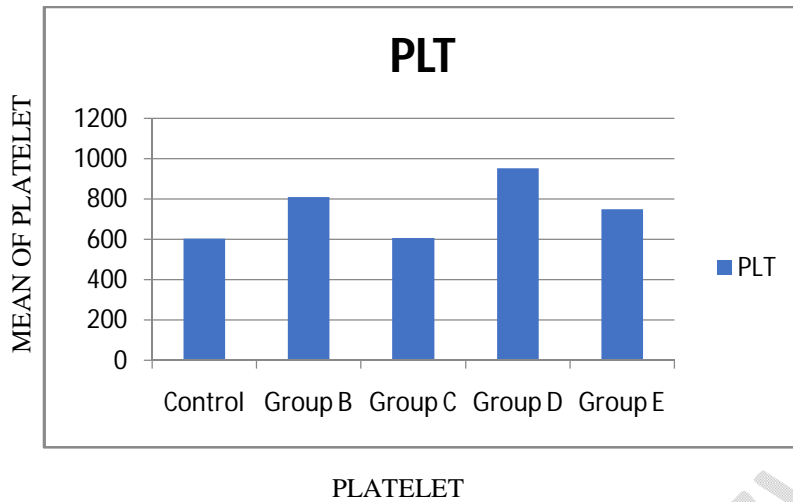


Fig 4.: Graph for mean of platelet count



Plates

Plate 1 which is labeled Group A (Control group) shows the morphology of the liver after administration of normal feed and water for twenty one (21) days. The slide shows the normal hepatic cells that are consistent with normal histology.

PLATE 2: Group B Shows the morphology of the liver after the administration of aluminium phosphide treatment for 21 days. Slide shows congestion of the central vein (CV), areas of focal necrosis (arrow), occlusion of sinusoidal space with marked presence of Kupffer cells (K).

PLATE 3: Group C Shows the morphology of the liver after the administration of aluminium phosphide and neem extract for 21 days. Slide shows central vein congestion (CV) with hepatocytes showing balloon degeneration (B), occluded sinusoidal space and presence of Kupffer cells (K).

PLATE 4: Group D Shows the morphology of the liver after the administration of aluminium phosphide and neem extract for 21 days. Slide shows central vein congestion (C) with occluded sinusoidal space (S), presence of Kupffer cells (K).

PLATE 5: Group E Shows the morphology of the liver after the administration of neem extract for 21 days. Slide shows normal morphology of the liver, central vein (CV), hepatocytes with intact sinusoidal spaces (S) (X40).

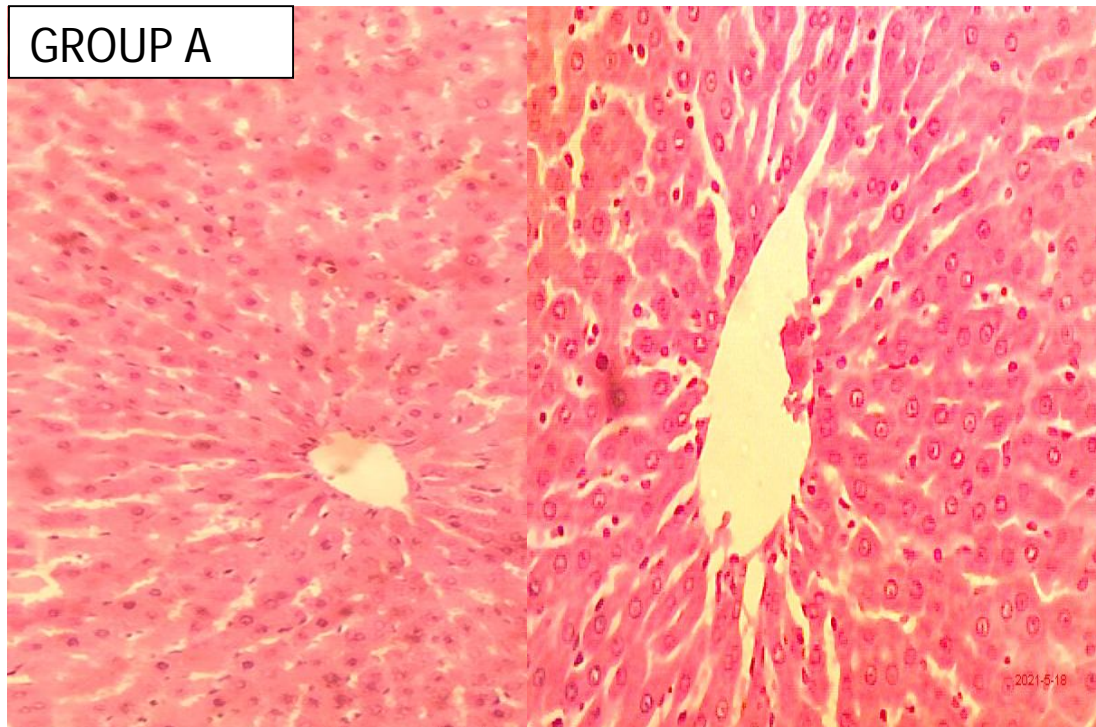


PLATE 1: Shows the morphology of the liver after the administration of the various treatments for 21 days. Slide shows normal morphology of the liver, central vein (CV), hepatocytes (H) with intact sinusoidal space (S) (X10)(X40)H&E

GROUP B

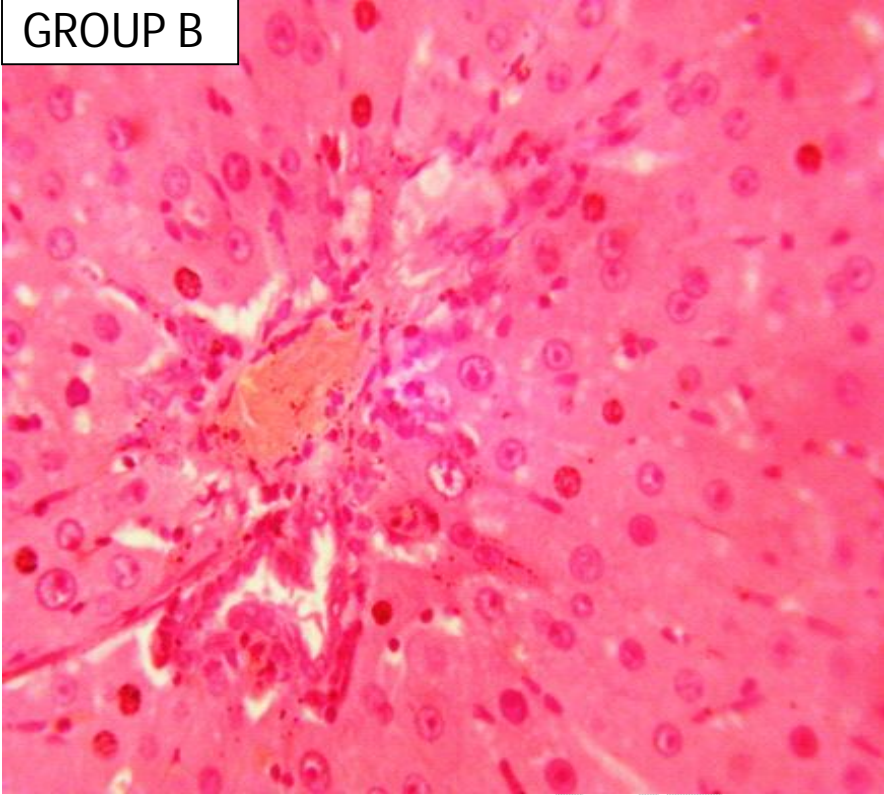


PLATE 2: Shows the morphology of the liver after the administration of the various treatments for 21 days. The slide shows congestion of the central vein (CV), areas of focal necrosis (arrow), occlusion of sinusoidal space with marked presence of Kupffer cells (K) (X40) H&E.

GROUP C

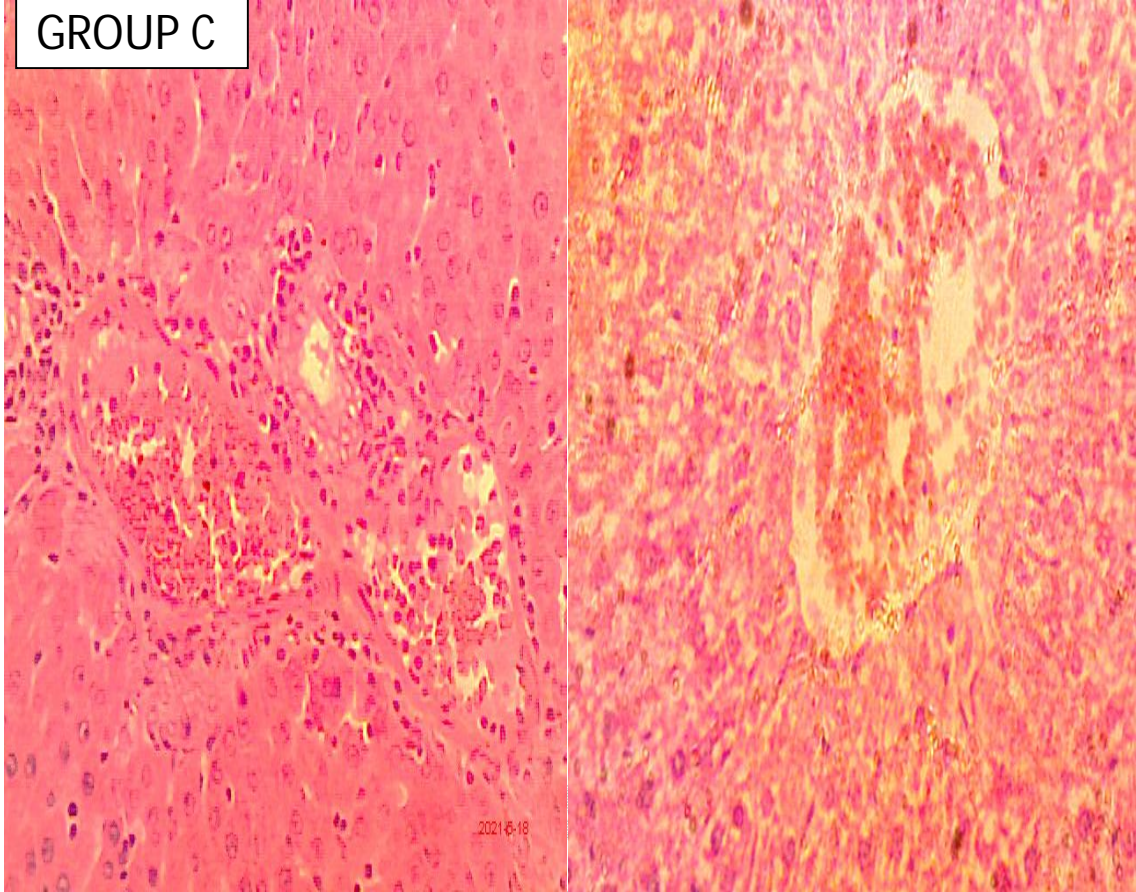


PLATE 3: Shows the morphology of the liver after the administration of the various treatments for 21 days. The slide shows central vein congestion (CV) with hepatocytes showing balloon degeneration(B), occluded sinusoidal space, and presence of Kupffer cells(K) (X40) H&E.

GROUP D

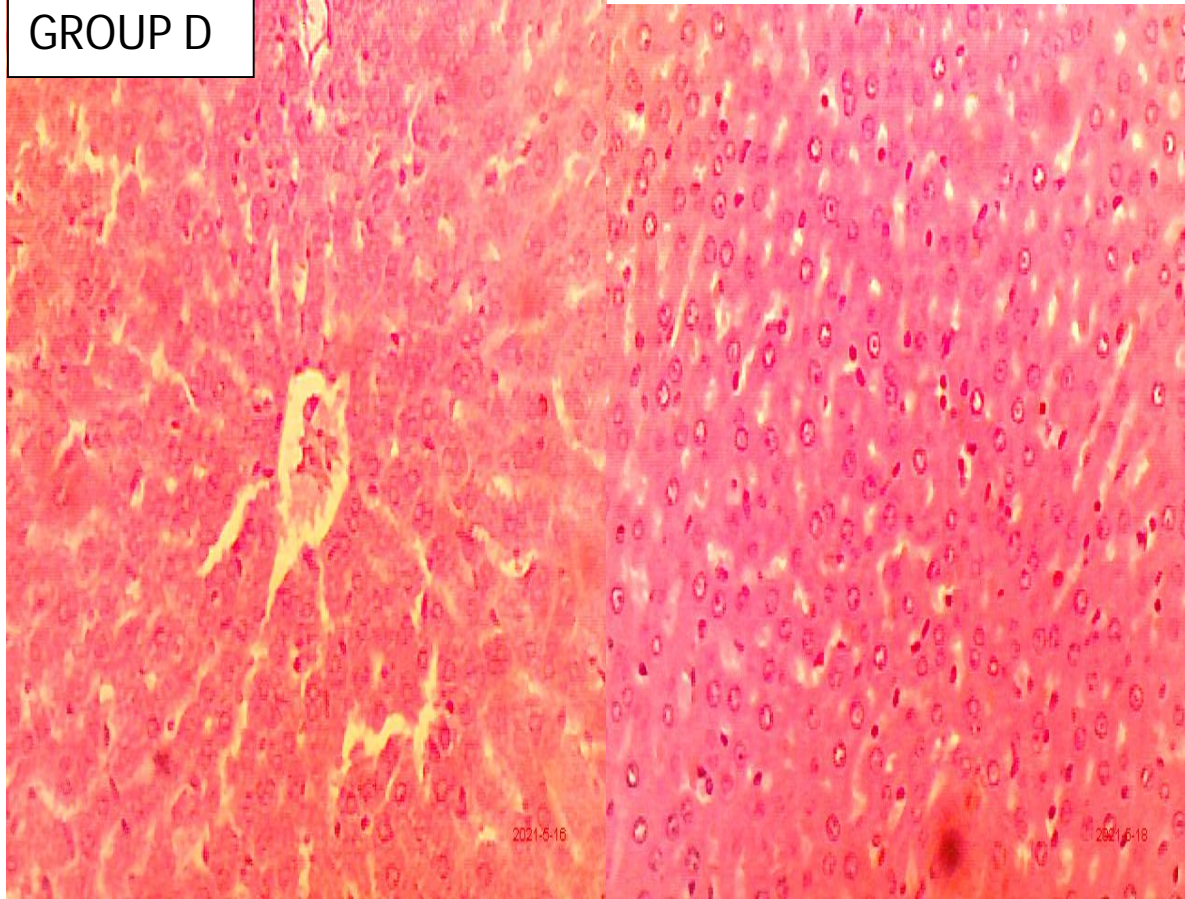


PLATE 4: Shows the morphology of the liver after the administration of the various treatments for 21 days. The slide shows central vein congestion (C) with occluded sinusoidal space (S), and the presence of Kupffer cells (K)(X10,X40).

GROUP E

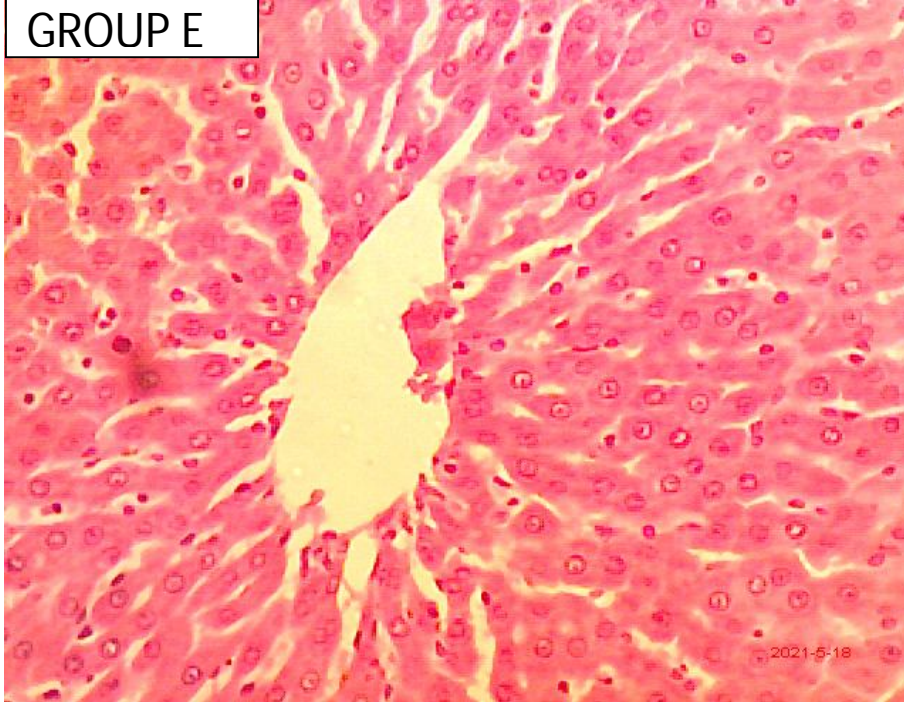

PLATE 5: Shows the morphology of the liver after the administration of the various treatments for 21 days. Slide shows normal morphology of the liver, central vein (CV), hepatocytes with intact sinusoidal spaces (S) (X40)

Discussion

The study was carried out to ascertain whether there'll be any significant change in the hematological parameters of neem extract on aluminumphosphide-inducedWistarrats. Neem extract has been proven in other studies to have anti-toxicity, anti-inflammatory, antipyretic, and anti-microbial properties, according to Ganong, 2005. Table 1 shows the red cell indices of animals in group B (Aluminium phosphide only), the result for this study revealed no significant change or increase in the red cell indices (MCV,MCH and MCHC) as compared with the value from the control group, $p>0.05$. Table 3 shows an increase in the RBC which is indicative ofaluminum phosphide-induced polycythemia in rats, $p>0.05$. Other blood parameters were also determined (Hb, PCV, PLT, WBC, NEU, BAS, EOS, MONO, AND LYMP), where Haemoglobin had no significant change, $p>0.05$ as compared to the control group,and a significant change in PCV and platelet with $p<0.05$. Lymphocyte, monocyte, and basophil had no significant increase observed, $p>0.05$. On the other hand WBC, neutrophil, and eosinophil were decreased significantly, $p<0.05$ There was no significant change in the PCV, Rbc, mch, mchc, mcv, eosinophil, and basophil, $p>0.05$. Group C and D had a significant difference in mcv and plt respectively, $p<0.05$ Lastly, those in group E given just feed and the extract had no significant change in Hb, Rbc, Mch, Mchc, Wbc, neutrophil, PCV, plt, and lymphocyte, $p>0.05$.

Shakeriet *al* revealed a significant increase in the mch, mchc and mcv of the rat induced with aluminum phosphide, and a significant reduction in the Rbc. (Shakeriet *al.*, 2014).

Similar work done by Okoliet *al* reveals significant increase in the WBC using neem seed extract and carried out their research for 63 days (Okoliet *al.*, 2002). Ntelioset *al.*, (2013), observed that leucopenia in animals may be due to depression of leucopoiesis, alteration in the cell membrane or integration in the cell membrane, or disintegration of WBC. Those treated with the leaf extract (groups C and D) had inconsistencies in certain blood parameters. In the presence of aluminum phosphide cellular superoxide and peroxide radicals are generated with subsequent cellular damage by lipid peroxidase, (Almasiehet *al.*, 2011; Hsu *et al.*, 1998; Lievanet *al.*, 2007; Nguyen *et al.*, 2003), which is a chain of reaction of oxidative degradation of lipid. Process where free radicals 'steals' electron from the lipids in the cell membrane resulting in cell damage. It was also found to decrease serum levels of biochemical parameters, (Chughet *al.*, 1996). On the other hand, neem extract has been found out to have compounds which help inhibits oxidation, chemical reactions that can produce free radicals leading to a chain reaction that may damage the cells. It deactivates free radicals before they attack the biological cell, (Silva, 2012), and also plays role in the activation of oxidative enzymes that controls damage caused by free radicals (Rahmani, 2015). From this study neem leaf extract has no effect on the haematological parameters of the rats when taken or administered independently according to dosage utilized in this work.

The plates labeled 1-5 shows the photomicrograph of the liver of the animals used in this study.

A research by Iniobong et al, 2020 reported that ingestion of aluminium phosphide can result to increase cellular superoxide and peroxide radicals which are generated, with subsequent cellular damage caused by lipid peroxidation . Also Eric et al .,(2021) concluded that the oral ingestion of Aluminium Phosphide induces hepatotoxicity and inflammation of the liver and kidney(Eric et al.,2021).This must have been due to the fact that aluminum phosphide causes oxidative damage in cells and tissues by enhancing lipid peroxidation (Gurer *et al.*, 1999). Lipid peroxidation renders cell constituents inactive through oxidation (oxidative stress) by undergoing radical chain reaction, leading to loss of membrane integrity (Abdel-Wahhab and Aly, 2005).

Cellular reactive oxygen species (ROS), produced mainly through mitochondrial respiratory chain reactions, serve as an important signaling molecule in modulation of cell proliferation and survival (Sena& Chandel,2012;Cui,2012 ;Nogueira & Hay 2013). However, excessive cellular ROS damage the cellular macromolecules such as protein, lipid, and DNA. Increased ROS production beyond physiological level can be caused by deregulated metabolism and mitochondrial dysfunction, and is associated with aging and chronic diseases like cancer (Sena&Chandel,2012 ;Wallace,2012). Therefore, control of cellular ROS levels and redox balance effectively prevents oxidative stress-induced damage and decreases cancer incidence (Ray et al.,2012;Lenaz,2012). Dietary supplement of neem flowers in rats represses most phase I reactions, especially those involved in the metabolic activation of carcinogens, and increases the activity of phase II enzyme glutathione-S-transferase (GST) . GST is one of the most important anti-oxidant phase II enzyme families, and it conjugates the substrate with reductive glutathione and reduces the cellular oxidative levels. In contrast to neem flowers, NLE shows no significant effect on phase I enzymes but only induces a number of antioxidant phase II enzymes in treated mice. *In vitro* treatment with neem extract induces the expression of glutathione S-transferase-pi (GSTPi) in tumor cell lines as well as in human peripheral blood lymphocytes. The levels of glutathione in liver and extrahepatic organs have been found elevated by NLE treatment (Subapriya et al.,2005)

From this study there was gross hepatotoxic effect produced after the administration of aluminium phosphide, although neem extract was given but no appreciable ameliorative effect. This is because ingestion, aluminium phosphide, it is rapidly absorbed through the gastrointestinal tract and it is partly carried to the liver by the portal vein. This can cause liver dysfunction, especially after the first day of poisoning (Salekiet *al*, 2007). According to a report carried out by Hossain *et al.*, (2013) that neem leave at a dose of 200mg/kg taken orally showed anti-inflammatory activity. The morphology of plate 4 is an indication of aluminium phosphide treatment which induces oxidative reaction leading to cell damage Aluminium phosphide promotes protein denaturation that results in breakdown of integrity of cell (Mehrpour *et al.*, 2012). A study result has confirmed that extract of *A. indica* leaves at a dose of 200mg/kg,p.o.,showed significant anti-inflammatory activity in cotton pellet granuloma assay in rats (Hossain *et al*, 2013). This explains the mild dysfunction seen in the plates..

The ingestion of neem extract does not result to hepatotoxic effect, it correlates with the protective effect of active constituent of neem such as nimbolide against carbon tetrachloride (CCl₄) induced liver toxicity in rats and results suggest that nimbolide possesses hepatoprotective effect against CCl₄ induced liver damage (Baligare *et al*, 2014). An important study based on rats model showed that neem extract did not show toxicity even at 5g/kg body weight (Schumache *et al.*,2011).

CONCLUSION

Aluminium phosphide poisoning related death is common in developing countries especially in Asia and Africa. This research work is intended to ascertain the ameliorative effect of neem extract on aluminium phosphide induced toxicity using adult wistar rats. From the results obtained, it shows the hepatotoxic effect of aluminium phosphide with diffuse increase in the liver aminotransferases (aspartate aminotransferase and alanne aminotransferase). Histological evaluation also showed congested hepatocytes, occlusion of sinusoid and presence of kupffer cell which are indicative of hepatic dysfunction. Meanwhile, neem extract was administered during the 21 days treatment with varying doses. Result shows that the group which took a higher dose of neem extract had less damage to the liver cell compared to those that took a lesser dose and aluminium phosphide alone. Hence, it can be inferred that neem extract does not completely ameliorate hepatotoxicity of aluminium phosphide.

Recommendation

Neem extract does not completely ameliorate the effect of aluminum phosphide on the liver of albino Wistar rats. However due to our findings during the course of this study, the following recommendations are made;

- Further study on the anti-toxicity of neem should be carried out
- Further study on the effect on neem on aluminum phosphide using higher dose should be carried out.

REFERENCE

Chugh, SN., Kishore, K., Aggarwal, N., Attri, S. (2000) Hypoglycemia in acute aluminium phosphide poisoning. *Journal Association Physicians India.*;48:855–6.

Sudakin, DL. Occupational exposure to aluminium phosphide and phosphine gas? (2005)A suspected case report and review of the literature. *Hum Export Toxicology.*;24:27–33.

Singh, P., Priya, E., and Balakrishnan, S. (2016). Nimbolide inhibits androgen independent prostate cancer cells survival and proliferation by modulating multiple pro-survival signaling pathways. *Biomedicine & Pharmacotherapy.* **84**, 1623-1634.

Ranga, G.S., Dwivedi, S., Agarwal, M., and Kumar, D. (2004). Aluminium phosphide poisoning in a young adult: a suicidal cardiotoxin simulating myocardial ischaemia. *JournalofIndianAcademyofClinicalMedicine.* **5**:369.

Bajpai, S.R. (2010). Aluminium phosphide poisoning: management and prevention. *Journal of Indian Academy of Forensic Medicine.*32:352–354

Ferrer, M.I., Alvarez, Li F. and Cepero, R.A. (2009). Suicide by ingestion of aluminum phosphide: a case report. *Emergencias*. **21**:228–231

Mehrpour, O., Jafarzadeh, M., and Abdollahi, M. (2012). A systematic review of aluminium phosphide poisoning. *Archives of Industrial Hygiene and Toxicology*. **63**(1): 61-73.

Kamath SG, Chen N, Xiong Y, Wenham R, Apte S, Humphrey M, Cragun J, Lancaster JM. Gedunin, a novel natural substance, inhibits ovarian cancer cell proliferation. *Int. J. Gynecol. Cancer*. 2009;19:1564–1569. [[PubMed](#)] [[Google Scholar](#)]

Shadnia, S., Sasanian, G. and Allami, P. (2009). A retrospective 7-years study of aluminum phosphide poisoning in Tehran: opportunities for prevention. *Human and Experimental Toxicology*. **28**:209–213.

Baeri, M., Shariatpanahi, M., Baghaei, A., Ghasemi-Niri, S.F., Mohammadi, H., and Mohammadirad, A. (2013) On the benefit of magnetic magnesium nanocarrier in cardiovascular toxicity of aluminum phosphide. *Toxicology and Industrial Health journal*. **29**(2):126-135.

Balachandran, P. and Govindarajan, R., (2005). Cancer- an ayurvedic perspective. *Pharmacological Research*. **51**:19-30.

Eric, E. U., Boloya, V. E., &Osuamkpe, A. E. (2021). Aggravation of Aluminum Phosphide Induced Liver Damage and Hematotoxicity in Adult Wistar Rat: The Role of

Allium Sativum. *European Journal of Biology and Biotechnology*, 2(2), 51–59.

<https://doi.org/10.24018/ejbio.2021.2.2.176>

Da Silva V.C., de França Silva F.M., Meunier I.M., Da Silva T.M., da Silva Júnior V.A., Maia F.C. Post-natal development of rats' offspring treated with the ethanol extract of Neem leaves (*Azadirachta indica* A. Juss) during pregnancy and lactation. *Acta Sci. Biol. Sci.* 2012 and 2015;37:219–224.

Brahmachari, 2004. G. Brahmachari. Neem—An omnipotent plant: A retrospection *Chembiochem*, 5 (4) (2004), pp. 408-421.

Hossain et al., 2013 M.A. Hossain, W.A.S. Al-Toubi, A.M. Weli, Q.A. Al-Riyami, J.N. Al-Sabahi Identification and characterization of chemical compounds in different crude extracts from leaves of Omani neem *Journal of Taibah University for Science*, 7 (4) (2013), pp. 181-188.

Schumacher et al., 2011 M. Schumacher, C. Cerella, S. Reuter, M. Dicato, M. Diederich Anti-inflammatory, pro-apoptotic, and anti-proliferative effects of a methanolic neem (*Azadirachta indica*) leaf extract are mediated via modulation of the nuclear factor- κ B pathway, *Genes and Nutrition*, 6 (2) (2011), pp. 149-160, 10.1007/s12263-010-0194-6.

Rahmani A., Almatroudi A., Alrumaihi F., Khan A. Pharmacological and therapeutic potential of neem (*Azadirachta indica*) *Pharmacognosy Reviews*. 2015:2018;12(24):250–255.

Liaw D., et al. PTEN, a putative protein tyrosine phosphatase gene mutated in human brain, breast, and prostate cancer. *Science*. 1997;275(5308):1943–1947.

Mehrpour O, Shakeri S. Aluminum phosphide poisoning in animals. *Int J Med Toxicol Forensic Med* 2014; 5: 81–97

Harikushnan, Kariman H, Heydari K, Fakhri M, et al. Aluminium phosphide poisoning and oxidative stress. *J Med Toxicol* 2012; 8: 281–284.

Abdel- Wahhab, Aly, Abdel-Raheem IT, Abdel-Ghany AA. Hesperidin alleviates doxorubicin-induced cardiotoxicity in rats. *J Egypt Natl Canc Inst* 2009; 21: 175–184.

Hsu CH, Chi BC, Liu MY, et al. Phosphine-induced oxidative damage in rats: role of glutathione. *Toxicology* 2002; 179: 1–8.

Hsu CH, Quistad GB, Casida JE (1998) Phosphine-induced oxidative stress in hepa 1c1c7 cells. *Toxicol Sci* 46(1):204–210

Singh, S. and Shivay, Y.S. (2003) Coating of prilled urea with eco-friendly neem (*Azadirachta indica* A. Juss.) formulations for efficient nitrogen use in hybrid rice. *Acta Agron. Hungarica* 51:53-59.

Benelli, G., Bedini, S., Cosci, F., Toniolo, C., Conti, B., Nicoletti, M., 2014. Larvicidal and ovideterrent properties of neem oil and fractions against the filariasis vector *Aedes albopictus* (Diptera: Culicidae): a bioactivity survey across production sites. *Parasitol Res* 114, 227–236. doi:10.1007/s00436-014-4183-3

Girish K. Antimicrobial activities of *Lantana camara* Linn. *Asian J Pharm Clin Res* 2017;10:57-67.

Shankar SS, Rai A, Ahmad A, Sastry M. Rapid synthesis of Au, Ag, and bimetallic Au core-Ag shell nanoparticles using neem (*Azadirachta indica*) leaf broth. *J Colloid Interface Sci* 2004;275:496-502.

Girish K, Shankara Bhat. Neem-a green treasure. *Electron J Biol* 2008;4:102-11.

Y Mukesh, P Savitri, R Kaushik, NP Singh - *Journal of Environmental ...*, 2014 - jeb.co.in

MUKESH, K. B., K. J. JITENDER, Y. SATYANARAYANA, A. DEVIVARAPRASADREDDY (2012): Animal and plant originated immunostimulants used in aquaculture. *J. Nat. Prod. Plant Resour.* 2, 397-400.

KWAWUKUME, A. A., K. G. ANING, J. A. AWUNI, H. OTSYINA, B. A. WUMBILA (2013): The effects of *Azadirachta indica* (Neem) leaf extract on white blood cell count and the immune response of chickens vaccinated with newcastle disease vaccine. *Int. J. Curr. Sci.* 2013, 7:23-31.

SHAILENDER, M., C. H. SURESH-BABU, R. S. RAJAGOPAL (2013): Toxic effect of Neem, Azadirachta indica plant bark on growth and survival of freshwater catfish, Pangasius hypophthalmus. *Int. J. Toxicol. Appl. Pharmacol.* 3, 39-43

HARIKRISHNAN, R., M. N. RANI, C. BALASUNDARAM (2003): Hematological and biochemical parameters in common carp, Cyprinus carpio, following herbal treatment for Aeromonas hydrophila infection. *Aquaculture* 221, 41-50. DOI: 10.1016/S0044-8486(03)00023-1

Sena LA, Chandel NS. Physiological roles of mitochondrial reactive oxygen species. *Mol. Cell.* 2012;48:158–167. [[PMC free article](#)] [[PubMed](#)] [[Google Scholar](#)]

Cui X. Reactive oxygen species: the Achilles' heel of cancer cells? *Antioxid. Redox Signal.* 2012;16:1212–1214. [[PMC free article](#)] [[PubMed](#)] [[Google Scholar](#)]

Nogueira V, Hay N. Molecular pathways: reactive oxygen species homeostasis in cancer cells and implications for cancer therapy. *Clin. Cancer Res.* 2013;19:4309–4314. [[PMC free article](#)] [[PubMed](#)] [[Google Scholar](#)]

Wallace DC. Mitochondria and cancer. *Nat. Rev. Cancer.* 2012;12:685–698. [[PMC free article](#)] [[PubMed](#)] [[Google Scholar](#)]

Ray PD, Huang BW, Tsuji Y. Reactive oxygen species (ROS) homeostasis and redox regulation in cellular signaling. *Cell. Signal.* 2012;24:981–990. [[PMC free article](#)] [[PubMed](#)] [[Google Scholar](#)]

Lenaz G. Mitochondria and reactive oxygen species. Which role in physiology and pathology? *Adv. Exp. Med. Biol.* 2012;942:93–136. [[PubMed](#)] [[Google Scholar](#)]

Niture SK, Rao US, Srivenugopal KS. Chemopreventative strategies targeting the MGMT repair protein: augmented expression in human lymphocytes and tumor cells by ethanolic and aqueous extracts of several Indian medicinal plants. *Int. J. Oncol.* 2006;29:1269–1278. [[PubMed](#)] [[Google Scholar](#)]

Subapriya R, Kumaraguruparan R, Abraham SK, Nagini S. Protective effects of ethanolic neem leaf extract on DMBA-induced genotoxicity and oxidative stress in mice. *J. Herb. Pharmacother.* 2005;5:39–50. [[PubMed](#)] [[Google Scholar](#)]