

Case report

A Rare Case of Ovarian Ectopic Pregnancy

ABSTRACT

Aims: The present case report aimed to report a rare case of ovarian ectopic pregnancy. The prevalence of ovarian ectopic pregnancy, a rare type of non-tubal ectopic pregnancy that accounts for less than 3% of all ectopic cases, is believed to range from 1:7000 to 1:70,000. It often ruptures prior to the end of the first trimester. Here, we discuss one such rare case of ovarian ectopic pregnancy.

Presentation of Case: Our patient, a 26-year-old woman, arrived with excruciating pain in the abdomen. Right ovarian ectopic pregnancy was discovered during laparotomy evaluation, but there was no evidence of embryonic cardiac activity. Only the ovary was surgically removed. A small 4cm * 4 cm ovarian mass with impending rupture was found and removed, leaving the right ovary intact. Histopathological examination confirmed it to be an ovarian ectopic pregnancy.

Conclusion: Ovarian ectopic pregnancy is a rare variant of ectopic gestation. Diagnosis is made often at surgery and requires histologic confirmation.

Keywords: Ovarian pregnancy, Ectopic pregnancy, Laparotomy

1. INTRODUCTION

“Ectopic pregnancy is a known pregnancy complication in women of reproductive age that, if undiagnosed and untreated, can result in a high incidence of morbidity and mortality. It is the leading cause of maternal death in early pregnancy”. [1]

When a fertilised ovum settles outside of the typical uterine cavity, an ectopic pregnancy results.[2-4] The majority of ectopic conceptions, or tubal pregnancies, (97%) take place in the fallopian tube. However, implantation can also take place on the cervix, ovaries, caesarean scar, peritoneal cavity, uterine scars, or inside the abdomen.[6] Any location where an ectopic pregnancy is developing causes the tissue to vascularize, become friable, and ultimately rupture, resulting in internal bleeding. The situation should be handled as a medical emergency because it may endanger life. Early identification is therefore crucial and imperative.

“The estimated prevalence of primary ovarian ectopic pregnancy, a rare form of non-tubal ectopic pregnancy that accounts for less than 3% of all ectopic cases, ranges from 1:7000 to 1:70,000”. [7] Numerous cases have been documented in the literature since St. Maurice's initial case report in 1689. According to Heartig, ovarian pregnancy happens in one in every 25,000 to 40,000 births.[8] The diagnosis of ovarian ectopic pregnancy is challenging for practising clinicians and is dependent on surgical/emergency laparotomies and histopathological observations.[9] “Due to the increased vascularization of the ovarian tissue, it typically ends in a rupture in the first trimester and can cause internal bleeding and hypovolemic shock state”. [10]

Findings are likely to look similar to those of a tubal pregnancy or a leaking corpus luteum. About one-third of situations involve serious bleeding. Early ovarian pregnancies will

probably be treated during operation as a corpus luteum cyst or a bleeding corpus luteum. Unruptured ovarian births are now more frequently diagnosed thanks to the use of transvaginal sonography.[11]

Diagnosis of the ectopic ovarian pregnancy is made using the Spiegelberg criteria [12] which includes:

- a. The gestational sac should be located in the region of the ovary.
- b. The ectopic pregnancy should be attached to the uterus by the ovarian ligament.
- c. Histologically, Ovarian tissue in the wall of the gestational sac should be proved.
- d. The fallopian tube on the involved side should be intact.

“The most prevalent form of ectopic pregnancy is a tubal pregnancy, followed by ovarian pregnancies. Intrauterine implants frequently cause ovarian pregnancies (IUDs). While using an IUD appears to be disproportionately associated with ovarian ectopic pregnancy risk, traditional risk factors for tubal pregnancy are comparable to those for ovarian ectopic pregnancy”.[13] Results are probably going to look similar to those of a tubal pregnancy or a leaking corpus luteum. About one-third of instances involve serious bleeding. Early ovarian pregnancies will probably be treated during operation as a corpus luteum cyst or a bleeding corpus luteum. Unruptured ovarian births are now more frequently diagnosed thanks to the use of transvaginal sonography.[9] Ectopic ovarian pregnancies carry a significant risk of maternal morbidity and death. Traditionally, medical intervention has been used to treat ovarian pregnancies. Ovarian wedge resection or cystectomy have been used to treat early haemorrhage from small lesions. The most common treatment for bigger lesions is ovariectomy, though laparoscopy has also been used for laser ablation or resection. Finally, unruptured ovarian cysts have been effectively treated with methotrexate.[14]

We, herereported a case of a 26-year-old patient who was successfully treated for Ectopic Ovarian by laparotomy in emergency department of Obstetrics & Gynecology at MGM Medical College and MYH Hospital, Indore

2. PRESENTATION OF CASE

A 26-year-old female primigravida patients reported to Department of Obstetrics & Gynecology, MGM Hospital & MYH Hospital, Indore with chief complain of severe lower abdominal pain & spotting for 14 days. She was recommended from the Department of Surgery and had a history of amenorrhea lasting 9 weeks and 2 days. Her last period was regular, with a typical flow and no dysmenorrhea. During the examination, the right iliac fossa was tender, there was no pallor, and the heart rate was 104/minute. She had no medical, surgical or family history. She was conscious and her vitals were stable. Per abdominal examination was found to be soft. Per vaginal examination showed normal uterine size and no cervical motion tenderness, fullness was present in right side fornix and slight bleeding was present. Culdocentesis was negative. All blood investigations were normal. Her serum beta hCG was 6588 units. On Transvaginal sonography (TVS) a gestational sac and a right sided ectopic ovarian pregnancy with no embryonic cardiac activity present within was seen. No obvious sign of rupture of ectopic pregnancy were present. (Figure 1)

Ectopic pregnancy with no rupture was the preliminary diagnosis. Patient was admitted and urgent laparotomy was planned. Diagnosis of ovarian pregnancy was confirmed by intraoperatively by performing laparotomy. A 4 cm * 4 cm ovarian mass with impending rupture was found and removed, leaving the right ovary intact. A rent was present in broad ligament which was repaired. Haemostasis was achieved. Patient was successfully discharged from hospital after 4 days. Diagnosis of ovarian pregnancy was confirmed histologically. A primary ovarian pregnancy was confirmed by the presence of trophoblastic villi and corpus luteum on histopathological inspection of the ovarian tissue. (Figure 2).

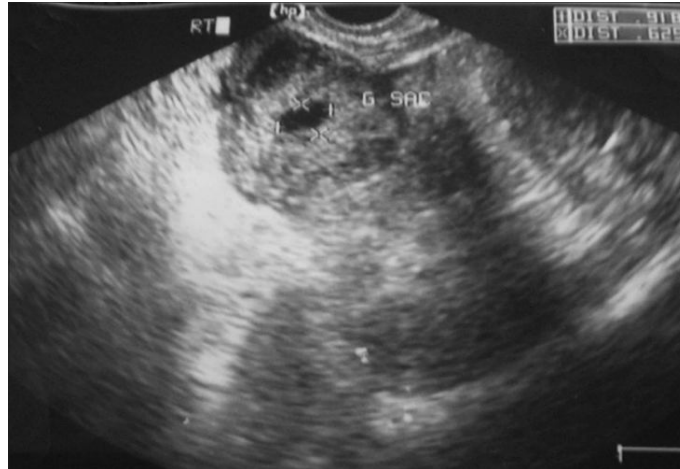

Figure 1: TVS ultrasonography showing ectopic gestation

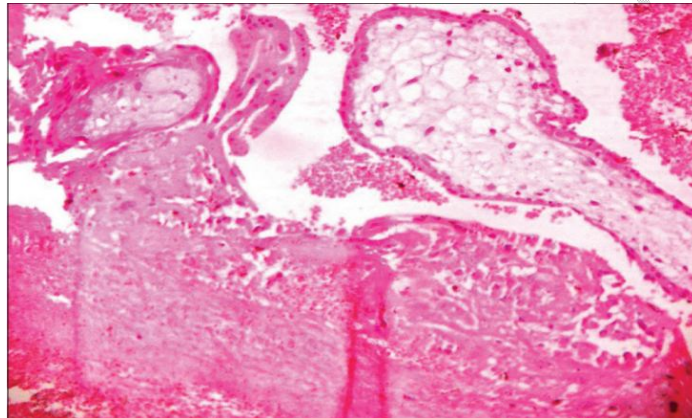


Figure 2: Histopathology slide demonstrating corpus luteum and trophoblastic villi imbedded in ovarian tissue.

3. DISCUSSION

“One of the rarest types of extra-uterine pregnancy is primary ovarian pregnancy. With few instances, the four Spiegelberg criteria are used to determine the final diagnosis, which is only based on histopathology, to determine that the pregnancy is restricted to the ovary and excludes the tube”. [12]

“The underlying cause of primary ovarian pregnancy is still obscure. Borrow came to the conclusion that ovarian pregnancies could be explained by coincidence”. [15] Other theories include tube dysfunction, inflammation-induced tunica albugenia thickening, and interference with ovum discharge from the ruptured follicle. Another factor could be the intrauterine control method currently being used. “Primary ovarian pregnancy may also result from the condition known as empty follicle syndrome, which occurs when no oocytes are extracted from mature ovarian follicles despite their appearing normal follicular development and estradiol levels following controlled ovarian hyperstimulation for an assisted reproductive technology cycle”. [16]

The signs and symptoms of ovarian pregnancy are analogous to those of disrupted tubal pregnancy, which are most frequently misdiagnosed as chocolate cyst, hemorrhagic corpus luteum, or tubal ectopic pregnancy. An ectopic ovarian pregnancy by the rule ruptures in the first trimester although in some the pregnancy may advance to full term. [17] Ovarian pregnancy can now be identified before surgery thanks to advancements in ultrasonographic

technique and equipment, particularly the use of vaginal probes.[18] Contrary to 15% of tubal pregnancies, no cases of repeated ovary pregnancy have been documented.[19] Even in patients with early onset, the final diagnosis is made surgically and histopathologically, so surgical interventions serve both diagnostic and therapeutic purposes. The patient's age, fertility, desire for additional pregnancies, the size of the mass, and the fact that oophorectomy is a radical operation should all be taken into account; wedge resection is another surgical option. In recent years, medical and cautious therapies have also been developed to stop ovarian tissue loss, pelvic adhesions, and to maintain the patient's fertility. These include administering mifepristone to patients with conditions identified by transvaginal USG, administering injectable prostaglandin F2a, and administering MTX to patients with non-ruptured conditions identified by laparoscopy. Pagidas and Frishman successfully treated ovarian ectopic patients identified by transvaginal USG with MTX. They emphasised that transvaginal USG-diagnosed early-stage cases can profit from MTX treatment.[20] A 37-year-old woman with a history of two prior caesarean sections and IUD use was treated with multidose MTX successfully by Di Luigi et al.; she was identified as having an ectopic ovarian pregnancy at six weeks by transvaginal USG. They emphasised that early-stage ovarian ectopic cases can be medically managed, preserving the normal anatomy necessary for fertility, by carefully evaluating the patient and performing a transvaginal exam. Reviewing the data reveals that MTX treatment is selected following the establishment of a precise diagnosis and the localization of ectopic cases by laparoscopy, which justifies the designation of laparoscopy as a supporting diagnostic procedure. "The use of MTX treatment is recommended in particular and is preferable to surgery in situations where the gestational sac is less than 30 millimeters, without foetal cardiac activity, and less than six weeks old because it does not affect fertility. With a beta hCG level between 10,000 and 14,999 mIU/mL, methotrexate treatment has an 82% success rate in women with tubal ectopic pregnancy; however, the American Society of Reproductive Medicine guidelines state that a beta hCG level greater than 5000 mIU is a relative contraindication to medical therapy".[21] As in the case discussed, the patient was a primigravida with a history of amenorrhea of 9 week and 2 days, hemodynamic stability, no cardiac activity and no hemoperitoneum. Patient was admitted in the hospital and urgent laparotomy was planned. Diagnosis of ovarian ectopic pregnancy was confirmed intraoperatively by performing laparotomy.

4. CONCLUSION

Even though ovarian ectopic pregnancy is an uncommon condition, when choosing a medical treatment, especially for young patients, it is important to consider the preservation of fertility. Ovarian pregnancy can be hard to diagnose. It thus continues to present difficulties for practicing doctors. It can now be detected early thanks to advancements in ultrasonography, which allows for conservative therapy and preservation surgery. The diagnosis must have histologic confirmation and is frequently confirmed during surgery. It is best to avoid using an IUD that contains copper or levonorgestrel if the user has a history of ectopic pregnancies.

CONSENT

All authors declare that 'written informed consent was obtained from the patient (or other approved parties) for publication of this case report and accompanying images.

Ethical Approval:

As per international standard or university standard written ethical approval has been collected and preserved by the author(s).

REFERENCES

1. AllMummert T, Gnugnoli DM. Ectopic Pregnancy. [Updated 2022 Aug 8]. In: StatPearls [Internet]. Treasure Island (FL): StatPearls Publishing; 2023 Jan-.
2. Walker JJ. Ectopic pregnancy. *Clin Obstet Gynecol*. 2007;50:89–99.
3. Della-Giustina D, Denny M. Ectopic pregnancy. *Emerg Med Clin North Am*. 2003;21:565–584.
4. Varma R, Gupta J. Tubal ectopic pregnancy. *Clin Evid (Online)* 2009;2009:1406.
5. Cecchino GN, Araujo Júnior E, Elito Júnior J (September 2014). "Methotrexate for ectopic pregnancy: when and how". *Archives of Gynecology and Obstetrics*. 290 (3): 417–23.
6. Crochet JR, Bastian LA, Chireau MV (April 2013). "Does this woman have an ectopic pregnancy?: the rational clinical examination systematic review". *JAMA*. 309 (16): 1722–9.
7. Marcus SM, Brinsden PR. Primary ovarian pregnancy after in vitro fertilization and embryo transfer: report of seven cases. *FertilSteril*. 1993;60:167–70
8. Hertig AT. Discussion of Gerin-Lojoie L. Ovarian pregnancy. *Am J Obstet and Gynecol*1951;62:920.
9. H.G. Tehrani, Z. Hamoush, M. Ghasemi, L. Hashemi, Ovarian ectopic pregnancy: a rare case, *Iran. J. Reprod. Med*. 12 (4) (2014) 281.
10. Birge, O., Erkan, M.M., Ozbey, E.G. *et al*. Medical management of an ovarian ectopic pregnancy: a case report. *J Med Case Reports* 9, 290 (2015).
11. Cunningham FG, Leveno KJ, Bloom SL, Hauth JC, Rouse DJ, Spong CY. Ectopic pregnancy. *Williams Obstetrics*. 23rd Ed. Mc Graw Hill; 2010: 251.
12. Gerin-Lajoie L. Ovarian pregnancy. *Am J Obstet Gynecol*. 1951;62:920–9
13. Bouab M, Touimi AB, Jalal M, Lamrissi A, Fichtali K, Bouhya S. Diagnosis and management of ectopic ovarian pregnancy: a rare case report. *Int J Surg Case Rep*. 2022 Feb;91:106742.
14. Hegazy A. *Clinical embryology for medical students and postgraduate doctors*. Lap Lambert Academic Publishing; Berlin, 2014.
15. Borrow RC, McElin TW, West RH, Buckingham JC. Ovarian pregnancy; Report of four cases and a thirteen-year survey of the English literature. *Am J ObstetGynecol*1965;91:1095-6.
16. Qublan H, Tahat Y, Al-Masri A. Primary ovarian pregnancy after the empty follicle syndrome: A case report. *J ObstetGynaecol Res* 2008;34:422-4.
17. Darbar RD, Reddy CC, Despande NR, Nagalotimath SJ. Primary Ovarian Pregnancy (a case report). *J ObstetGynecol India* 1976;28:310.
18. Russel JB, Cutler LR. Transvaginal ultrasonographic detection of primary ovarian pregnancy with laparoscopic removal. *FertilSteril*1989;51:1055.
19. Sergent F, Mauger-Tinlot F, Gravier A, Verspyck E, Marpeau L. Ovarian pregnancies: Revaluation of diagnostic criteria. *J GynecolObstet Biol Reprod*2002;31:741-6.
20. Pagidas K, Frishman GN. Nonsurgical management of primary ovarian pregnancy with transvaginal ultrasound-guided local administration of methotrexate. *J Minim Invasive Gynecol*. 2013;20(2):252–4.
21. Medical treatment of ectopic pregnancy: The practice committee of the American society of reproductive medicine. *FertilSteril* 2008;90:S206-12