

Case report

A Rare Case of Ovarian Pregnancy

ABSTRACT

Aims: The present case report aimed to report a case of ovarian pregnancy. Ovarian ectopic pregnancy is a rare form of the non-tubal ectopic pregnancy which has an estimated prevalence ranging from 1:7000 to 1:70,000 accounting for almost 3 % of all ectopic cases. It often ends with rupture before the end of the first trimester. This case shows that early diagnosis is very important particularly in developing countries like India.

Presentation of Case: We report here one such uncommon case of ovarian ectopic pregnancy. Our patient is a 26 years old woman who presented with severe abdominal pain. During laparotomy examination, right ovarian ectopic pregnancy was diagnosed with no embryonic cardiac activity, and resection of the ovary was only done. 4cm * 4 cm ovarian mass with impending rupture was found and removed, leaving the right ovary intact. Histopathological examination confirmed it to be an ovarian ectopic pregnancy.

Conclusion: Ovarian ectopic pregnancy is a rare variant of ectopic gestation. Diagnosis is made often at surgery and requires histologic confirmation.

Keywords: Ovarian pregnancy, Ectopic pregnancy, Laparotomy

1. INTRODUCTION

Ectopic pregnancy is a known complication of pregnancy in women of reproductive age that can carry a high rate of morbidity and mortality when not recognized and treated promptly. It is the leading cause of maternal death in early pregnancy. [1]

An ectopic pregnancy occurs when a fertilized ovum implants outside the normal uterine cavity.[2-4] Most ectopic pregnancies (97%) occur in the fallopian tube, which are known as tubal pregnancies.[5] but implantation can also occur on the cervix, ovaries, caesarean scar, peritoneal cavity, uterine scars or within the abdomen ,also referred as non-tubal pregnancy.[6] A growing ectopic pregnancy in any location cause the tissue to become vascular, friable and eventually rupture to cause internal bleeding. The situation can be life threatening and needs to be treated as medical emergency. Thus, early diagnosis is very important and imperative.

Primary ovarian ectopic pregnancy is a rare type of non-tubal ectopic pregnancy which has an estimated prevalence ranging from 1:7000 to 1:70,000 accounting for almost 3 % of all ectopic cases.[7] Since the first case reported by St. Maurice in 1689, many cases have been reported in the literature. Heartig estimated that ovarian pregnancy occurs in one in 25,000-40,000 pregnancies.[8] The diagnosis of ovarian ectopic pregnancy is intricate and is based on surgical/ emergency laparotomies and histopathological observations and continues to challenge the practicing clinicians.[9] It is usually terminated by a rupture in the first trimester and because of the increased vascularization of the ovarian tissue it leads to internal hemorrhage and hypovolemic shock status. [10]

Findings are likely to mimic those of a tubal pregnancy or a bleeding corpus luteum. Serious bleeding is seen in approximately one third of cases. At surgery, early ovarian pregnancies

Comment [AH1]: Please, delete this sentence. It may be a conclusion.

Comment [AH2]: Please, transfer this sentence to the end of paragraph of Aims.

Comment [AH3]: was

Comment [AH4]: A small (4cm * 4 cm)

Comment [AH5]: can lead

are likely to be considered corpus luteum cyst or a bleeding corpus luteum. Use of transvaginal sonography has resulted in a more frequent diagnosis of unruptured ovarian pregnancies.[11]

Diagnosis is made using the Spiegelberg criteria [12] which include:

- a. The gestational sac is located in the region of the ovary.
- b. The ectopic pregnancy is attached to the uterus by the ovarian ligament.
- c. Ovarian tissue in the wall of the gestational sac is proved histologically.
- d. The tube on the involved side is intact.

Non-tubal pregnancies are the most common type of ectopic pregnancy and ovarian pregnancies are the second most common type. Ovarian pregnancies are very common with intrauterine devices (IUDs). Traditional risk factors for ovarian ectopic pregnancy are similar to those for tubal pregnancy, but use of an IUD seems to be disproportionately associated.[13] Findings are likely to mimic those of a tubal pregnancy or a bleeding corpus luteum. Serious bleeding is seen in approximately one third of cases. At surgery, early ovarian pregnancies are likely to be considered corpus luteum cyst or a bleeding corpus luteum. Use of transvaginal sonography has resulted in a more frequent diagnosis of unruptured ovarian pregnancies.[9]

Ovarian ectopic pregnancies are associated to a high-risk of maternal morbidity and mortality. The classical management for ovarian pregnancies has been surgical. Early bleeding for small lesion has been managed by ovarian wedge resection or cystectomy. With larger lesions ovariectomy is most often performed and laparoscopy has been used to resect or to perform laser ablation. Finally, methotrexate has been used successfully to treat unruptured ovarian.[14]

We in the present research paper presented a case report of a 26-year-old patient with an aim to study a case ectopic ovarian pregnancy which was successfully treated by laparotomy in emergency Obstetrical Department in MGM Medical College and MYH Hospital, Indore

2. PRESENTATION OF CASE

A 26-year-old female primigravida patients reported to Department of Obstetrics & Gynecology, MGM Hospital & MYH Hospital, Indore with chief complain of severe lower abdominal pain and spotting for 14 days. She had a history of 9 week and 2 days amenorrhea and was referred from the Department of Surgery. Her previous menstrual cycle was regular: average flow and no dysmenorrhea. On examination, no pallor, pulse 104/min, BP 100/70 mmHg and tenderness in the right iliac fossa were observed. She had no medical, surgical or family history. She was conscious and her vitals were stable. Per abdominal examination was found to be soft. Per vaginal examination showed normal uterine size and no cervical motion tenderness, fullness was present in right side fornix and slight bleeding was present. Culdocentesis was negative. All blood investigations were normal. Her serum beta hCG was 6588 units. On Transvaginal sonography (TVS) a gestational sac and a right sided ectopic ovarian pregnancy with no embryonic cardiac activity present within was seen. No obvious sign of rupture of ectopic pregnancy were present. (Figure 1)

Provisional diagnosis was unruptured ectopic pregnancy. Patient was admitted and urgent laparotomy was planned. Diagnosis of ovarian pregnancy was confirmed by intraoperatively by performing laparotomy. A 4 cm * 4 cm ovarian mass with impending rupture was found and removed, leaving the right ovary intact. A rent was present in broad ligament which was repaired. Haemostasis was achieved. Patient was successfully discharged from hospital after 4 days. Diagnosis of ovarian pregnancy was confirmed histologically. On

Comment [AH6]: Tubal

Comment [AH7]: Ovarian

Comment [AH8]: Please, add this reference for this sentence.

Hegazy A. Clinical embryology for medical students and postgraduate doctors. Lap Lambert Academic Publishing; Berlin, 2014.

Comment [AH9]: ?? Please add an ovarian cyst or what do you mean?

Comment [AH10]:

Comment [AH11]: Delete it. This is not research but a case report.

Comment [AH12]:

Comment [AH13]: reporting a case

histopathological examination, trophoblastic villi and corpus luteum embedded in the ovarian tissue were seen, which were confirmatory of primary ovarian pregnancy (Figure 2).

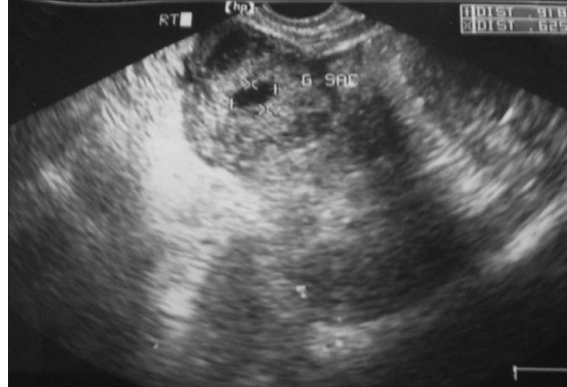

Figure 1: TVS Ultrasonogram showing ectopic gestation

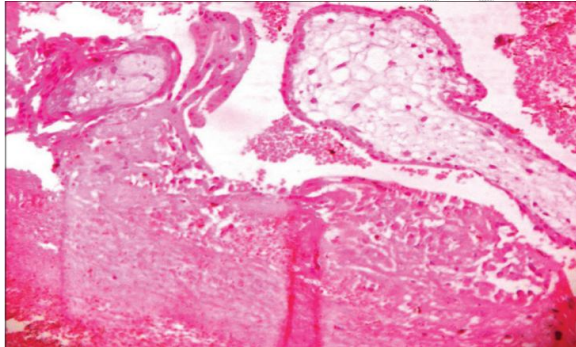


Figure 2: Histopathology slide showing trophoblastic villi and corpus luteum embedded in ovarian tissue

Comment [AH14]: please, add here the stain & magnification of the section.

3. DISCUSSION

Primary ovarian pregnancy is one of the rarest types of extra-uterine pregnancy. With few exceptions, the initial diagnosis is made on the operating table and the final diagnosis only on histopathology on the basis of the four Spigelberg criteria, establishing that the pregnancy is limited to the ovary and does not involve the tube.[12]

The cause of primary ovarian pregnancy remains obscure. Borrow concluded that chance is a reasonable explanation of ovarian pregnancies.[15] Other hypotheses have suggested interference in the release of the ovum from the ruptured follicle, malfunction of the tubes and inflammatory thickening of the tunica albugenia. Current intra uterine contraceptive device used may also be a cause. The entity, empty follicle syndrome, where no oocytes are retrieved from the mature ovarian follicles with apparently normal follicular development and estradiol levels, after controlled ovarian hyperstimulation for an assisted reproductive technology cycle, despite repeated aspiration and flushing, can also be a cause for primary ovarian pregnancy.[16]

The signs and symptoms of ovarian pregnancy are similar to disturbed tubal pregnancy, conditions most commonly confused with ruptured hemorrhagic corpus luteum and chocolate cyst or tubal ectopic pregnancy. Rupture in the first trimester is the usual rule in an

ovarian ectopy, but the pregnancy may advance to full term.[17] With the improvement in the ultrasonographic skill and instrumentation, especially with the use of vaginal probe, ovarian pregnancy can be diagnosed pre-operatively.[18] No case of repeat ovarian pregnancy has been reported in contrast to approximately 15% recurrent tubal pregnancy.[19]

As the definitive diagnosis is made surgically and histopathologically even in patients with early onset, surgical interventions have both a diagnostic and a therapeutic value. Because oophorectomy is a radical procedure for ovarian ectopic pregnancy, consideration should be given to the patient's age, fertility, her desire to have further pregnancies, and the size of the mass; wedge resection can also be another surgical option. Medical and conservative treatments have also been introduced in recent years to prevent ovarian tissue loss, pelvic adhesions and to preserve the patient's fertility. These include administration of mifepristone for patients diagnosed using a transvaginal USG, parenteral prostaglandin F_{2a} and MTX treatment for non-ruptured cases detected with laparoscopy. Pagidas and Frishman performed MTX treatment for ovarian ectopic cases diagnosed using transvaginal USG and achieved healing. They emphasized that early staged cases diagnosed by transvaginal USG, can benefit from MTX treatment.[20] Di Luigi et al. also performed and succeeded with multidose MTX treatment which they administered to a 37-year-old patient with a history of two previous cesarean sections and IUD usage; she was diagnosed at 6 weeks of ectopic ovarian pregnancy by use of a transvaginal USG. They emphasized that with careful clinical evaluation and transvaginal examination early staged ovarian ectopic cases can be treated medically which preserves the normal anatomy crucial for fertility. A review of the data shows that MTX treatment is chosen after a clear diagnosis and detection of the localization of ectopic cases by laparoscopy and therefore laparoscopy is declared to be a supporting diagnostic procedure. In cases in which the gestational sac is lower than 30 mm, without fetal cardiac activity, and less than 6-weeks old, MTX treatment is supported in particular and is superior to surgery because it does not disturb fertility. Methotrexate treatment in women with tubal ectopic pregnancy shows a success rate of 82%, with the beta hCG level between 10,000 and 14,999 mIU/mL, but according to the American Society of Reproductive Medicine guidelines, a beta hCG level more than 5000 mIU is a relative contraindication to medical therapy.[21]

As in our case, the woman was a primigravida with a history of 9 week and 2 days amenorrhea, no cardiac activity, hemodynamic stability and no hemoperitonium. Patient was admitted and urgent laparotomy was planned. Diagnosis of ovarian pregnancy was confirmed by intraoperatively by performing laparotomy.

4. CONCLUSION

Although ovarian ectopic pregnancy is a rare condition, after careful evaluation, the selection of medical procedures should take into consideration the preservation of fertility particularly for young patients. The diagnosis of ovarian pregnancy is difficult. Thus, it continues to challenge the practicing clinicians. Now, with ultrasonographic advances, it can be diagnosed early, leading to conservative treatment and preservative surgery. The diagnosis is made often at surgery and requires histologic confirmation. For a woman with a previous history of ectopic pregnancy, it is better not to use a copper or levonorgestrol containing IUD.

CONSENT (WHERE EVER APPLICABLE)

"All authors declare that 'written informed consent was obtained from the patient (or other approved parties) for publication of this case report and accompanying images. A copy of the written consent is available for review by the Editorial office/Chief Editor/Editorial Board members of this journal."

REFERENCES

1. AllMummert T, Gnugnoli DM. Ectopic Pregnancy. [Updated 2022 Aug 8]. In: StatPearls [Internet]. Treasure Island (FL): StatPearls Publishing; 2023 Jan-.
2. Walker JJ. Ectopic pregnancy. *Clin Obstet Gynecol.* 2007;50:89–99.
3. Della-Giustina D, Denny M. Ectopic pregnancy. *Emerg Med Clin North Am.* 2003;21:565–584.
4. Varma R, Gupta J. Tubal ectopic pregnancy. *Clin Evid (Online)* 2009;2009:1406.
5. Cecchino GN, Araujo Júnior E, Elito Júnior J (September 2014). "Methotrexate for ectopic pregnancy: when and how". *Archives of Gynecology and Obstetrics.* 290 (3): 417–23.
6. Crochet JR, Bastian LA, Chireau MV (April 2013). "Does this woman have an ectopic pregnancy?: the rational clinical examination systematic review". *JAMA.* 309 (16): 1722–9.
7. Marcus SM, Brinsden PR. Primary ovarian pregnancy after in vitro fertilization and embryo transfer: report of seven cases. *FertilSteril.* 1993;60:167–70
8. Hertig AT. Discussion of Gerin-Lojoie L. Ovarian pregnancy. *Am J Obstet and Gynecol*1951;62:920.
9. H.G. Tehrani, Z. Hamoush, M. Ghasemi, L. Hashemi, Ovarian ectopic pregnancy: a rare case, *Iran. J. Reprod. Med.* 12 (4) (2014) 281.
10. Birge, O., Erkan, M.M., Ozbey, E.G. *et al.* Medical management of an ovarian ectopic pregnancy: a case report. *J Med Case Reports* 9, 290 (2015).
11. Cunningham FG, Leveno KJ, Bloom SL, Hauth JC, Rouse DJ, Spong CY. Ectopic pregnancy. *Williams Obstetrics.* 23rd Ed. Mc Graw Hill; 2010: 251.
12. Gerin-Lajoie L. Ovarian pregnancy. *Am J Obstet Gynecol.* 1951;62:920–9
13. Bouab M, Touimi AB, Jalal M, Lamrissi A, Fichtali K, Bouhya S. Diagnosis and management of ectopic ovarian pregnancy: a rare case report. *Int J Surg Case Rep.* 2022 Feb;91:106742.
14. Kamrava M, editor. Ectopic Pregnancy - Modern Diagnosis and Management [Internet]. InTech; 2011. Available from: <http://dx.doi.org/10.5772/646>
15. Borrow RC, McElin TW, West RH, Buckingham JC. Ovarian pregnancy; Report of four cases and a thirteen-year survey of the English literature. *Am J ObstetGynecol*1965;91:1095-6.
16. Qublan H, Tahat Y, Al-Masri A. Primary ovarian pregnancy after the empty follicle syndrome: A case report. *J ObstetGynaecol Res* 2008;34:422-4.
17. Darbar RD, Reddy CC, Despande NR, Nagalotimath SJ. Primary Ovarian Pregnancy (a case report). *J ObstetGynecol India* 1976;28:310.
18. Russel JB, Cutler LR. Transvaginal ultrasonographic detection of primary ovarian pregnancy with laparoscopic removal. *FertilSteril*1989;51:1055.
19. Sergent F, Mauger-Tinlot F, Gravier A, Verspyck E, Marpeau L. Ovarian pregnancies: Reevaluation of diagnostic criteria. *J GynecolObstet Biol Reprod*2002;31:741-6.

20. Pagidas K, Frishman GN. Nonsurgical management of primary ovarian pregnancy with transvaginal ultrasound-guided local administration of methotrexate. *J Minim Invasive Gynecol.* 2013;20(2):252-4.
21. Medical treatment of ectopic pregnancy: The practice committee of the American society of reproductive medicine. *FertilSteril* 2008;90:S206-12

UNDER PEER REVIEW