

## Original Research Article

# Histopathological Profile of Obese Zebrafish Liver After Administration of Red Spinach (*Amaranthus tricolor* L.)

### ABSTRACT

**Aims:** Obesity is a non-communicable disease whose prevalence continues to increase every year throughout the world. Obesity contributes to the emergence of several diseases such as type-2 diabetes mellitus, hypertension, cardiovascular disorders, cancer, and non-alcoholic fatty liver. A number of studies report that natural ingredients have the potential to be used as a treatment for obesity while reducing a fatty liver. The aim of this research is to evaluate the activity of red spinach ethanol extract in reducing the accumulation of fatty liver in diet-induced obese zebrafish based on its histopathological profile.

**Methodology:** Zebrafish must be adapted for 2 weeks. After 2 weeks, the zebrafish were divided into 6 groups which included: the normal group (or negative control); the obesity group (positive control group); the standard drug (orlistat with dose 4.5 µg/ml); the EERS group (dose of 50 µg/ml); the EERS group (dose of 100 µg/ml); and the EERS group (dose of 200 µg/ml). For a period of 4 weeks, the normal group received a standard diet. A positive control group received Artemia. The treated group received Artemia which was combined with the administration of red spinach (preventive method). The obese group and extract-treated group were given 60 mg/group/fish in the experimental diet.

**Results:** The results showed that EERS at a dose of 100 µg/ml did not show any fatty liver based on their histopathological profile. The EERS dose of 200 µg/ml is more effective in reducing fatty liver when compared to doses of 50 µg/ml and 100 µg/ml on obese zebrafish.

**Conclusion:** Based on the results of the study, it can be concluded that EERS is very prospective for further research and development as a drug for treating obesity and reducing fatty liver.

*Keywords: Histopathological, Obese, Red Spinach, Zebrafish.*

## 1. INTRODUCTION

The prevalence of obesity in the world will continue to increase. The increasing prevalence of obesity contributes to the high rates of morbidity and mortality in the world [1]. The pathophysiology of obesity is an imbalance between energy intake and expenditure [2]. Obesity has a relationship with metabolic syndromes, such as type two diabetes mellitus (T2DM), hypertension, lipid disorders, cancer, and non-alcoholic fatty liver disease (NAFLD) [3],[4].

Non-alcoholic fatty liver disease or NAFLD is a condition when there is excessive accumulation of fat in the liver [5]. This build-up of fat is not caused by heavy alcohol use. The fat accumulation, especially in the form of triglycerides in the hepatocytes [6]. Two types of NAFLD are non-alcoholic fatty liver (NAFL) and non-alcoholic steatohepatitis (NASH) [7]. NAFL is a form of NAFLD in which you have fat in your liver but little or no necroinflammation or liver damage. NAFL typically does not progress to cause liver damage or complications. However, NAFL can cause pain from enlargement of the liver. NASH is the form of NAFLD in which you have inflammation of the liver and liver damage, in addition to fat in

your liver. The inflammation and liver damage of NASH can cause fibrosis, or scarring, of the liver. NASH may lead to cirrhosis, in which the liver is scarred and permanently damaged. Cirrhosis can lead to liver cancer [8].

As explained above, obesity has a relationship with the occurrence of NAFLD, it is necessary to carry out further research and development regarding natural-based drugs that have the potential to act as anti-obesity and at the same time have the capability to reduce fatty liver, considering that Indonesia is one of the countries in Southeast Asia and in a world that has many kinds of medicinal plants. One of the plants that have the potential to be used and developed as medicine is red spinach.

Red spinach (*Amaranthus tricolor* L.) is a red-purple vegetable with many pharmacological activities. Red spinach's pharmacological activities include antiviral, anti-inflammatory, antioxidant, antibacterial, hepatoprotective, diuretic, and hypolipidemic [9]. Studies on the use of red spinach in reducing fatty liver (NAFLD) have been reported before [10]. Therefore, the purpose of this study was to further investigate the activity of red spinach ethanol extract in reducing the accumulation of fatty liver in diet-induced obese zebrafish based on its histopathological profile.

## **2. MATERIAL AND METHODS**

### **2.1 Plant Material and Identification**

The red spinach leaves used in this study were obtained from BALITTRO, Bogor, West Java, Indonesia. The plant identification was performed at the Indonesian Institute of Sciences (LIPI), Jakarta, Indonesia.

### **2.2 Extraction Process**

Red spinach leaves were extracted with 96% ethanol by maceration method and then evaporated through a rotary evaporator. The extract obtained was used for *in vivo* studies using zebrafish.

### **2.3 Experimental Animals**

In this study, the zebrafish used was of the male sex. All zebrafish used in this study must be in a controlled environment (referring to zebrafish guidelines) [11]. Research on zebrafish was conducted at the Faculty of Pharmacy, Bhakti Kencana University, Bandung, Indonesia.

### **2.4 Experimental design**

Because this research is part of previous research (Yuniarto et al., 2020) [12], the research design used also refers to previous methods which can be explained as follows. Before being used for research, zebrafish must be adapted for 2 weeks. After 2 weeks of adaptation, the zebrafish were divided into 6 groups (each group consisted of 10 fish) which included: the normal group (or negative control); the obesity group (positive control group); the standard drug (orlistat with dose 4.5 µg/ml); the EERS group (dose of 50 µg/ml); the EERS group (dose of 100 µg/ml); and the EERS group (dose of 200 µg/ml). EERS is an ethanolic extract of red spinach. EERS is an ethanol extract from red spinach.

### **2.5 Histopathology of Liver**

Zebrafish that have been given treatment are then sacrificed and their liver organs are removed. The stain used in the histopathological analysis of the liver is Hematoxylin and Eosin (HE).

## **3. RESULTS AND DISCUSSION**

As mentioned above, this research is part of a previous study conducted by Yuniarto et al. (2020) using red spinach ethanol extract as an anti-obesity agent in zebrafish (*Danio rerio*) [12]. This study will focus more on the effect of red spinach ethanol extract in reducing fatty liver in zebrafish. The results showed that cells in the normal group (figure a) were generally normal with visible nuclear chromatin granules and pink cytoplasm (black arrows). However, a few cells experience death in the form of karyolysis where the cells do not have a nucleus (red arrows).

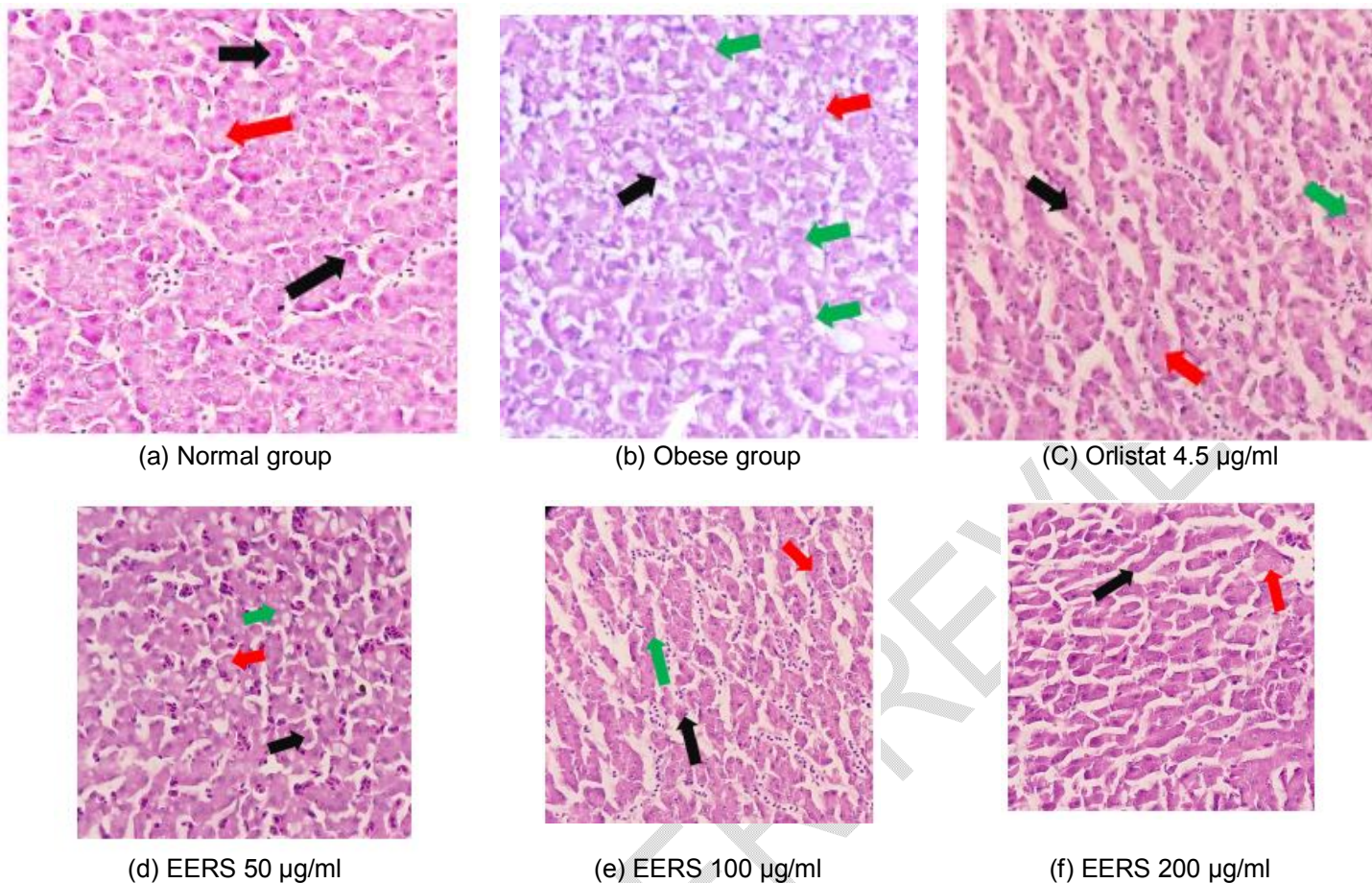


Figure 1. Histopathological liver of Zebrafish (*Danio rerio*) (HE, x400).

In figure b, the obese group can be seen the cells are generally normal with visible nuclear chromatin granules and pink cytoplasm (black arrows), the presence of fatty liver / hydroptic degeneration is indicated by green arrows, and death in the form of karyolysis where the cells do not have a nucleus (red arrows). Meanwhile, in figure c, which is the standard drug group (orlistat 4.5 µg/ml), it can be seen that the cells are generally normal with visible nuclear chromatin granules and pink cytoplasm (black arrows), and death in the form of karyolysis was found in which the cells did not have a nucleus (red arrows) in a very small number. In this group, fat accumulation was not seen in histology.

The results also showed that at the EERS 50 µg/ml and 100 µg/ml (figure d and e) the cells were generally normal with visible nuclear chromatin granules and pink cytoplasm (black arrows). However, there are still many cells that experience adaptation in the form of hydroptic degeneration (fatty) (green arrows) and death in the form of karyolysis where the cells do not have a nucleus (red arrows).

EERS dose of 200 µg/ml (shown in figure f) the cells are generally normal with visible nuclear chromatin granules and pink cytoplasm (black arrow). A few cells experience death in the form of karyolysis where the cells do not have a nucleus (red arrows). In this group, no fatty or hydroptic degeneration was found. Based on the histopathological profile of the liver, in the normal group, the obese group, the orlistat group, and the extract group (at doses of 50 µg/ml, 100 µg/ml, and 200 µg/ml) almost all had normal cells and karyolysis occurred (as indicated by red arrow). Karyolysis is one of the characteristics of necrosis. Necrosis is the death of cells or tissues caused by an irreversible degeneration process. In the liver, necrosis often occurs due to several external factors such as poison, infection, trauma, ischemia, and drug metabolites [13]. It is not yet fully known why, according to histopathological results, the entire experimental group experienced karyolysis.

The occurrence of hydroptic degeneration (shown by green arrows) was shown in the obese group, and the EERS group at doses of 50 µg/ml, and 100 µg/ml. Meanwhile, no hydroptic degeneration was found in the EERS group at a dose of 200 µg/ml. Hydroptic degeneration is an early manifestation of hepatocyte damage. Hydroptic degeneration occurs because cells are unable to maintain ion and fluid homeostasis, resulting in the loss of function of energy-dependent ion pumps in the plasma membrane. These morphological changes are easier to observe when extensive damage to the liver can cause paleness, increased turgor, and increased liver weight. Hydroptic degeneration on microscopic examination is seen

as small clear vacuoles in the cytoplasm. The results showed that a dose of 200 µg/ml of EERS was effective in reducing fatty liver when compared to doses of 50 µg/ml and 100 µg/ml.

#### 4. CONCLUSION

Based on the results of the study, it can be concluded that the EERS dose of 200 µg/ml is more effective in reducing fatty liver when compared to doses of 50 µg/ml and 100 µg/ml. This explains that EERS is very prospective for further research and development as a drug for treating obesity and reducing a fatty liver.

#### CONSENT (WHERE EVER APPLICABLE)

It is not applicable.

#### ETHICAL APPROVAL (WHERE EVER APPLICABLE)

ALL WERE ACCEPTED BY THE ANIMAL ETHICS COMMITTEE OF PADJADJARAN UNIVERSITY, BANDUNG, INDONESIA (NO. 561/UN6.KEP/EC/2020).

#### REFERENCES

- [1] Rulkiewicz, A., Pilchowska, I., Lisik, W., Pruszczyk, P., and Domienik-Karłowicz, J., 2022, Prevalence of Cigarette Smoking among Professionally Active Adult Population in Poland and Its Strong Relationship with Cardiovascular Co-Morbidities-POL-O-CARIA 2021 Study, *J. Clin. Med.*, 11, 3720.
- [2] Gadde, K. M., Martin, C. K., Berthoud, H. R., and Heymsfield, S. B., 2018, Obesity: Pathophysiology and Management, *J. Am. Coll. Cardiol.*, 71 (1), 69–84.
- [3] Fahed, G., Aoun, L., Zerdan, M. B., Allam, S., Zerdan, M. B., Bouferraa, Y., and Assi, H. I., 2022, Metabolic Syndrome: Updates on Pathophysiology and Management in 2021, *Int. J. Mol. Sci.*, 23 (2), .
- [4] Godoy-Matos, A. F., Silva Júnior, W. S., and Valerio, C. M., 2020, NAFLD as a continuum: From obesity to metabolic syndrome and diabetes, *Diabetol. Metab. Syndr.*, 12 (1), 1–20.
- [5] Miptah, H. N., Ramli, A. S., Mohamad, M., Hashim, H., and Tharek, Z., 2020, Non-alcoholic fatty liver disease (NAFLD) and the cardiovascular disease (CVD) risk categories in primary care: is there an association?, *BMC Fam. Pract.*, 21 (1), 1–12.
- [6] Zarghamravanbakhsh, P., Frenkel, M., and Poretsky, L., 2021, Metabolic causes and consequences of nonalcoholic fatty liver disease (NAFLD), *Metab. Open*, 12, 100149.
- [7] Bedossa, P., 2017, Pathology of non-alcoholic fatty liver disease, *Liver Int.*, 37 (October 2016), 85–89.
- [8] Pouwels, S., Sakran, N., Graham, Y., Leal, A., Pintar, T., Yang, W., Kassir, R., Singhal, R., Mahawar, K., and Ramnarain, D., 2022, Non-alcoholic fatty liver disease (NAFLD): a review of pathophysiology, clinical management and effects of weight loss, *BMC Endocr. Disord.*, 22 (1), 1–10.
- [9] Srivastava, R., 2017, An updated review on phyto-pharmacological and pharmacognostical profile of *Amaranthus tricolor*: A herb of nutraceutical potentials, *Pharma Innov. J.*, 6 (6), 124–129.
- [10] Mokhtari, E., Farhadnejad, H., Salehi-Sahlabadi, A., Najibi, N., Azadi, M., Teymouri, F., and Mirmiran, P., 2021, Spinach consumption and nonalcoholic fatty liver disease among adults: a case–control study, *BMC Gastroenterol.*, 21 (1), 1–10.
- [11] Reed, B., and Jennings, M., 2011, Guidance on the housing and care of Zebrafish, *Res. Anim. Dep.*, 1–64.
- [12] Yuniarto, A., Putri, A. Z., Selifiana, N., and Adnyana, I. K., 2020, Preventive Effect of Ethanol Extract of Red Spinach (*Amaranthus tricolor* L.) on Diet-induced Obese Zebrafish, *European J. Med. Plants*, 31 (20), 27–32.
- [13] Butler, D. C., Lewin, D. N., and Batalis, N. I., 2018, Differential Diagnosis of Hepatic Necrosis Encountered at Autopsy, *Acad. Forensic Pathol.*, 8 (2), 256–295.