

Case study

Ischemic stroke in young adult patients: Excess of Factor VIII

ABSTRACT

Aims: Ischemic stroke in young adult patients is an increasing public health problem. Hypercoagulability states and thrombophilia are both rare conditions behind ischemic strokes in young patients. We report a case of ischemic stroke in a young patient due to an excess of factor VIII.

Presentation of Case: A 38-year-old woman with a medical history of depression treated with Clomipramine was admitted to the emergency room for coma. The initial brain CT-Scan showed an image of a spontaneously hyperdense basilar artery, and brain MRI found a right occipital and left capsule-thalamic ischemic stroke with total occlusion of the basilar arterial trunk. A standard biological assessment has been performed showing an isolated elevation of factor VIII level at 200%.

Discussion: Approximately 80% of all strokes are ischemic strokes. Thrombophilic disorders and their contribution to the stroke risk are uncommon and factor V Leiden mutation accounts for almost half of the thrombophilic states. Case-control studies have suggested an association between elevated levels of FVIII and cryptogenic stroke in particular, which was nearly four times higher in people with elevated FVIII.

Conclusion: Factor VIII excess is a recently described, apparently common, and under-recognized cause of hypercoagulability. This case should make consider the fact that ischemic stroke is not only a pathology of the old subject. Also, it highlights the implication of excess in factor VIII in the states of hypercoagulability as a cause of young patient's ischemic stroke.

Keywords: [Ischemic stroke , Factor VIII excess , young patient, thrombophilia]

1. INTRODUCTION

Risk factors for ischemic stroke in younger adults are not unique to younger adults and overlap considerably with those of older adults but do vary in terms of the percent contribution to ischemic stroke subtypes. Of the more traditional risk factors that are highly prevalent among older adults (hypertension, dyslipidemia, and diabetes mellitus), clinical case studies and administrative studies have found that these risk factors are also highly prevalent among younger adult stroke patients although smoking is even more prevalent among younger stroke patients compared with older adults [5]. An ischemic stroke occurs due to a decreased blood flow in a certain area in the brain. This can be the consequences of obstruction of one of the blood vessels that irrigates the brain, or it can occur due to low systemic blood pressure. The most common causes of blood vessel obstruction are thrombosis and embolization. Thrombosis usually develops on atherosclerotic plaques [13].

2. PRESENTATION OF CASE

A 38-year-old woman with a medical history of depression treated with Clomipramine was admitted to the emergency room for coma. On admission, the patient was unconscious with a Glasgow Coma Scale at 8/15, with left anisocoria. Blood pressure was normal at 130/60 mmHg, a heart rate of 95 beats/min, normal glucose level of 1,05g/l, moreover the patient presented an initial oxygen saturation of 92%.

Orotracheal intubation was immediately performed, with the placement of a central venous line, as well as a gastric tube and a urinary catheter.

The initial brain CT-Scan (Figure 1), showed an image of a spontaneously hyperdense basilar artery, with no image of constituted ischemia, or hemorrhage. A toxicological screening performed was normal.

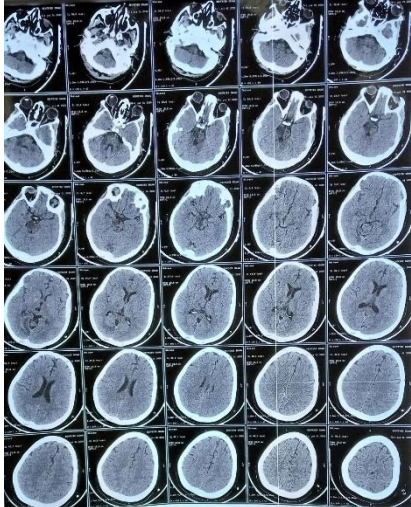


Figure 1 : Spontaneously hyperdense aspect of the basilar artery, on the initial brain scan

A brain MRI (Figure 2) , was performed, finding a right occipital and left capsulo-thalamic ischemic stroke with total occlusion of the basilar arterial trunk.

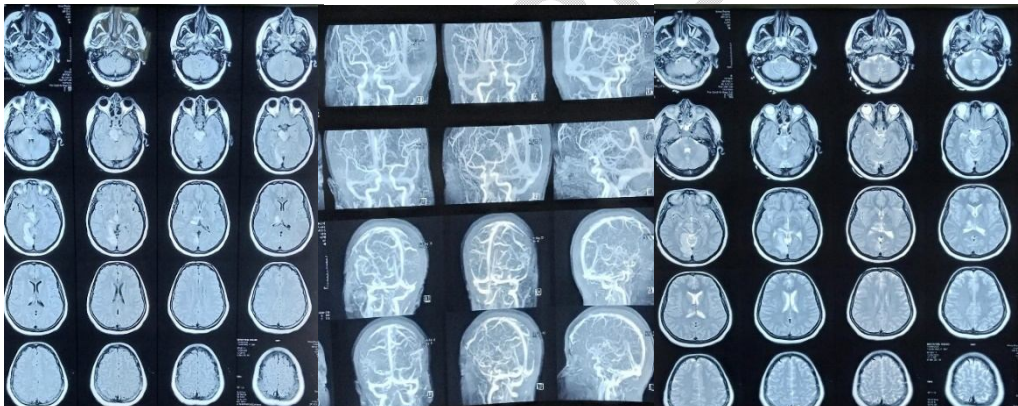


Figure 2 : Total occlusion of basilar trunk associated with hypodense lesions on brain MRI

ECG and transthoracic echocardiography were normal.

A standard biological assessment has been performed, showing :

- Normal platelets count at 258 000/mm³
- Normal prothrombin time at 98%
- Normal activated Partial Thromboplastin Time at 23 seconds

Faced with an ischemic stroke in a young adult, a complete assessment of thrombophilia was performed showing:

- A normal level of antithrombin 3, protein C and S at 109%, 115% and 140% respectively
- Elevated factor VIII level at 200%
- Absence of anti-phospholipid antibodies including:
 - Search for 'Lupus'-Type Circulating Anticoagulant by chronometric technique
 - Search for anti-cardiolipin and anti-beta2 glycoprotein1 antibodies by ELISA technique.

- Absence of resistance to activated protein C, with RPCa at 0.68 seconds (0.86 - 1.10).
- Absence of hyperhomocysteinemia
- Absence of Prothrombin gene G20210A mutation
- Absence of factor V Leiden mutation

Based on the results of this workup, ischemic stroke has been linked to increased factor VIII levels.

The patient was put on mechanical ventilation, with continuous sedation for 48 hours. Antiplatelet therapy was started with the association clopidogrel/aspirin.

Weaning from sedation was performed for neurological assessment, the patient could open her eyes spontaneously, with noninteraction, and with persistent anisocoria, and tetraparesis.

The evolution was marked by a failure of ventilation weaning, the patient underwent a tracheostomy after 12 days of mechanical ventilation and was discharged from the ICU after 49 days of hospitalization.

3. DISCUSSION

Stroke is a devastating disease that affects 15 million patients worldwide each year, resulting in death in about one-third of patients and severe disability in two-thirds of the survivors.(3) Approximately 80% of all strokes are ischemic strokes.(4) Although the incidence of ischemic stroke increases with age, an estimated 10% to 20% of these events occur in young people aged 18 to 50 years.(5) Compared with stroke in older adults, stroke in the young has a disproportionately large economic impact by leaving victims disabled before their most productive years.(1) In addition to traditional causes of strokes as vascular risk factors, including hypertension, hypercholesterolemia, diabetes mellitus, and obesity that they share with elderly subjects, young people present other etiologies with a predominance of cryptogenic strokes.(6) thrombophilic disorders and their contribution to the stroke risk are uncommon and factor V Leiden mutation accounts for almost half of the thrombophilic states.(7)

Factor VIII was significantly associated in men with coronary heart disease events (RR=1.5) and mortality (RR=1.8), and in women with stroke/transient ischemic attack (RR=1.4). (8)

Case-control studies have suggested an association between elevated levels of FVIII and cryptogenic stroke in particular, which was nearly four times higher in people with elevated FVIII, regardless of hypertension, smoking, and low high-density lipoprotein cholesterol, and FVIII was the only clotting abnormality positively associated with the disease among several others thrombophilic conditions , as in the case with our patient.(9–11)

The relationship between factor VIII and arterial thrombosis may be based on the combination of increased thrombin formation and increased platelet adhesion/aggregation, induced by vWF (von Willebrand factor), at sites of arterial wall damage. (12)

4. CONCLUSION

Factor VIII excess is a recently described, apparently common, and under-recognized cause of hypercoagulability. This case should make consider the fact that ischemic stroke is not only a pathology of the old subject. Also, it highlights the implication of excess in factor VIII in the states of hypercoagulability as a cause of young patient's ischemic stroke.

CONSENT (WHERE EVER APPLICABLE)

All authors declare that written informed consent was obtained from the patient for publication of this case report and accompanying images

REFERENCES

1. Renna R, Pilato F, Profice P, Della Marca G, Broccolini A, Morosetti R, et al. Risk Factor and Etiology Analysis of Ischemic Stroke in Young Adult Patients. *J Stroke Cerebrovasc Dis.* mars 2014;23(3):e221-7.
2. Conlan MG, Folsom AR, Finch A, Davis CE, Sorlie P, Marcucci G, et al. Associations of factor VIII and von Willebrand factor with age, race, sex, and risk factors for atherosclerosis. *Thromb Haemost.* 1993;70(09):380-5.
3. Pompili M, Venturini P, Campi S, Seretti ME, Montebovi F, Lamis DA, et al. Do stroke patients have an increased risk of developing suicidal ideation or dying by suicide? An overview of the current literature. *CNS Neurosci Ther.* 2012;18(9):711-21.
4. Chugh C. Acute ischemic stroke: management approach. *Indian J Crit Care Med Peer-Rev Off Publ Indian Soc Crit Care Med.* 2019;23(Suppl 2):S140.
5. George MG. Risk factors for ischemic stroke in younger adults: a focused update. *Stroke.* 2020;51(3):729-35.
6. Perera KS, de Sa Boasquevisque D, Rao-Melacini P, Taylor A, Cheng A, Hankey GJ, et al. Evaluating Rates of Recurrent Ischemic Stroke Among Young Adults With Embolic Stroke of Undetermined Source: The Young ESUS Longitudinal Cohort Study. *JAMA Neurol.* 1 mai 2022;79(5):450-8.
7. Ng KWP, Loh PK, Sharma VK. Role of Investigating Thrombophilic Disorders in Young Stroke. *Stroke Res Treat.* 8 févr 2011;2011:670138.
8. Tracy RP, Arnold AM, Ettinger W, Fried L, Meilahn E, Savage P. The Relationship of Fibrinogen and Factors VII and VIII to Incident Cardiovascular Disease and Death in the Elderly. *Arterioscler Thromb Vasc Biol.* juill 1999;19(7):1776-83.
9. Karttunen V, Alfthan G, Hiltunen L, Rasi V, Kervinen K, Kesäniemi YA, et al. Risk factors for cryptogenic ischaemic stroke. 2002;
10. GUSTAFSSON C. Coagulation factors and the increased risk of stroke in nonvalvular atrial fibrillation. *Stroke.* 1990;21:47-51.
11. CATTO A, CARTER A, BARRETT J, BAMFORD J, RICE P, GRANT P. von Willebrand factor and factor VIII: C in acute cerebrovascular disease: Relationship to Stroke subtype and mortality. *Thromb Haemost.* 1997;77(6):1104-8.
12. Kamphuisen PW, Eikenboom JCJ, Bertina RM. Elevated Factor VIII Levels and the Risk of Thrombosis. *Arterioscler Thromb Vasc Biol.* mai 2001;21(5):731-8.
13. MIHAI D, PLESA FC, AXELERAD AD, MUNTEANU A, GHINESCU MC, SIRBU CA. Ischemic stroke in young adults: practical diagnosis guide. *In ischemic stroke 2020 JUN 1 (P. 17). INTECHOPEN.*