

# **Secondary glaucoma after congenital cataract surgery: a serious complication not to be missed**

## **ABSTRACT :**

Secondary glaucoma is a serious complication in patients who have already undergone surgery for congenital cataract.

We report the case of a 27 year old female patient, operated on at the age of 3 weeks for bilateral congenital cataract, subsequently complicated by secondary glaucoma, followed since paediatric age; admitted to our department on dual hypotonic therapy,

Glaucoma and suspected glaucoma develop in 50% or more of children who have undergone congenital cataract surgery. The risk of developing glaucoma is the same whether patients remain aphakic or receive an implant at the time of cataract extraction. Most often, these glaucomas develop within 3 years of the surgical procedure,

Pediatric patients with surgically controlled intraocular pressure (IOP) may still have morbidities related to previous IOP elevation, including amblyopia, corneal scarring, strabismus, anisometropia, trauma susceptibility due to scleral fragility, and recurrent IOP elevation,

These morbidities can lead to severe long-term visual impairment and should be treated promptly.

**KEYWORDS:** congenital cataract, glaucoma, aphakic,

## **INTRODUCTION**

"Glaucoma in childhood and adolescence (also known as paediatric glaucoma) is a heterogeneous group of disorders associated with elevated intraocular pressure (IOP)"[1].

These disorders can result in structural damage to the optic nerve, and the functional damage in the visual field and, up to about 4 years of age, the cornea and other structures.

"Many of the causes of secondary glaucoma in infants and children are similar to those in adults, including trauma, inflammation, steroid use and topiramate-induced angle closure" [1].

The signs and symptoms at presentation will depend on the age of the child (whether the child is younger or older than 3-4 years) as well as the extent of the IOP elevation and the severity of the vision loss[1].

Congenital cataract is also associated with secondary paediatric glaucoma.

## CLINICAL CASE :

This is a 27-year-old female patient, operated on at the age of 3 weeks for bilateral congenital cataract, later complicated by secondary glaucoma, followed since paediatric age in the same eye health center in the same eye health center ; on admission to our department, she was put on dual hypotonising therapy for the first time .

On admission, the ophthalmological examination objective a :

- Corrected visual acuity: in the right eye at 5/10 : -1.75 (-1.00axe 65), and in the left eye at 2.5/10 : -1.25(0.75 a 135);
- preserved ocular motility
- A microcornea bilaterally( 9 mm), with a central corneal thickness of 630  $\mu$ m in the right eye, and 615  $\mu$ m in the left eye;
- A deep anterior chamber
- A difficult iridocorneal angle examination,
- Aphakic eye tone by applanation was 30 mmhg in the right eye and 25 mmhg in the left eye,
- Fundus examination; found a dysverted papilla; with a cup disc excavation of 9/10 in both eyes (figure 1),

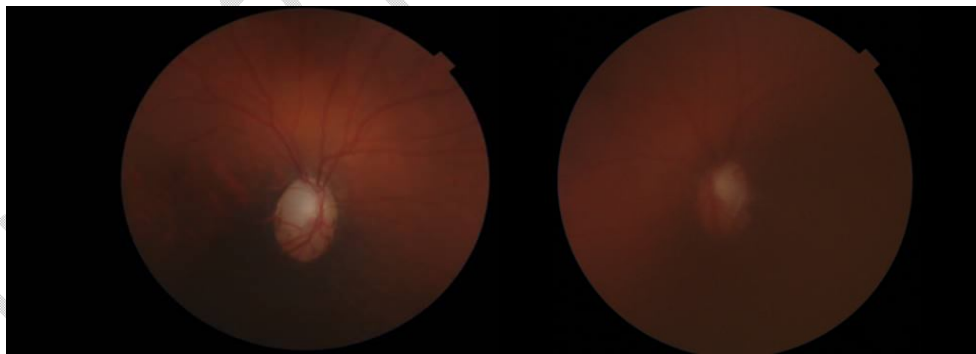


Figure 1: dysverted papilla; with a cup /disc excavation of 9/10 in both eyes

The functional impairment in the visual field 24.2 is almost alarming with a MD of -27dB in the right eye, and -30db in the left eye.

The analysis of the visual field 10,2 finds an impairment of the fixation point with a MD at -32dB in the right eye and -13 dB in the left eye (figure 2),

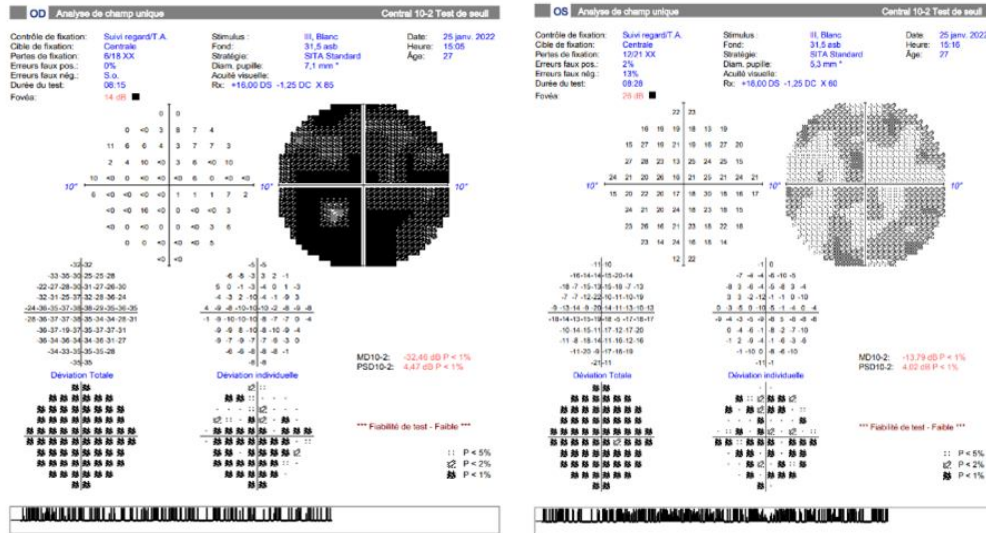


Figure 2 : the visual field 10,2 :an impairment of the fixation point with a MD at -32dB in the right eye and -13 dB in the left eye

The general examination does not find any facial or body deformation

In total: it is a picture of secondary glaucoma post surgery of congenital cataract

The patient is currently on quadritherapy with normalization of the ocular tone (carbonic anhydrase inhibitors, beta blockers, brimonidine, prostaglandin); a filtering surgery is discussed with the patient with analysis of the benefit-risk ratio.

## **DISCUSSION:**

"The Childhood Glaucoma Research Network has defined that although pediatric glaucoma shares many characteristics with adult glaucoma, there are many management issues that are unique to child and adolescent populations" [1]

Isolated angle defects are seen in primary paediatric glaucoma[2].

"In primary congenital glaucoma (PCG), angle dysgenesis leads to outflow resistance and elevated IOP, resulting in the classic features of PCG: enlarged and/or cloudy corneas, Haab's striae, and an enlarged globe (buphthalmos)" [2][3].

"In juvenile open-angle glaucoma (JOAG), another primary high-pressure glaucoma, an isolated angle defect may be present; this glaucoma develops later in childhood (usually after the age of 4 years) or in early adulthood, and is associated with other ocular or systemic conditions" [3].

"Secondary paediatric glaucomas are associated with other ocular or systemic conditions. These glaucomas are also classified according to whether or not the condition is acquired after the child's birth".[4]

"Glaucoma and suspected glaucoma develop in 50% or more of children who have undergone congenital cataract surgery".[5]

Glaucoma is predominantly of the open-angle type; however, angle closure can also occur as a late consequence of an enlargement of Sommering's ring that pushes the iris forward.[6]

The term "aphakic glaucoma" is commonly used to refer to this group of glaucomas; today, this term may be considered outdated as many of these young patients receive intraocular lens implants.[5][6]

Risk factors include[5]:

- Cataract surgery in the first year of life (the risk is higher in those who had surgery in the first 6 weeks of life),

- Post-operative complications

- Small diameter of the cornea

"The risk of developing glaucoma is the same whether patients remain aphakic or receive an intraocular lens implant at the time of cataract extraction. Although most glaucoma following congenital cataract surgery develops in patients within 3 years of cataract surgery, these patients are still at risk of glaucoma and therefore require lifelong follow-up".[5][7]

The underlying mechanism is unclear, but likely etiologies of open-angle cases include congenital abnormalities of the outflow tract, surgically induced inflammation, and altered intraocular anatomy after surgery. Removal of all residual cortex during cataract surgery can reduce the risk of IOP elevation. 5]

"The development of effective surgical techniques has significantly improved the long-term prognosis of patients with pediatric glaucoma, when the disease is diagnosed after the age of 12 months, the prognosis is poor and the risk of blindness is high".[7]

Children with secondary paediatric glaucoma tend to have the worst prognosis; up to 50% of them lose light perception despite treatment.

Early referral to vision rehabilitation may be helpful to patients and their families.[4]

"Paediatric patients with surgically controlled IOP may still have morbidities related to previous IOP elevation, including amblyopia, corneal scarring, strabismus, anisometropia, susceptibility to trauma due to scleral fragility and recurrent IOP elevation",[4][6]

These morbidities can lead to severe long-term visual impairment and therefore need to be treated promptly.

"Amblyopia is a common cause of visual impairment, especially in patients with unilateral glaucoma, corneal opacification and/or anisometropia. It is important to treat amblyopia aggressively, addressing the conditions that contribute to its development, such as refractive error, strabismus, and corneal pathology".[6][7]

High IOP can lead to progressive myopia and anisometropia in patients with juvenile open-angle glaucoma.

"Refractive errors should be corrected with glasses or contact lenses, and the use of protective eyewear should be encouraged".[8]

"Strabismus may result from glaucoma tube bypass surgery or amblyopia. When performing surgery to correct strabismus, the surgeon should try to minimise conjunctival scarring in anticipation of future glaucoma surgeries and should be aware of the sites of previous trabeculectomies and shunt tube implantations".[9]

## **CONCLUSION:**

All cases of paediatric glaucoma require lifelong follow-up to monitor

IOP, potential complications from previous operations and secondary vision-threatening complications. As IOP elevation may recur even years later, glaucoma and paediatric ophthalmologists must coordinate care.

A team approach to care will involve low vision rehabilitation specialists, paediatricians, genetic counsellors, educators and parents or caregivers. This doesn't come out from this case

Educating parents or caregivers about the need for lifelong follow-up of a child with operated congenital cataract can improve the long-term management of this difficult disease.

## **CONSENT :**

As per international standard or university standard, patient(s) written consent has been collected and preserved by the author(s)

## **ETHICAL APPROVAL :**

As per international standard or university standard written ethical approval has been collected and preserved by the author(s)

## **REFERENCES :**

[1]Thau A, Lloyd M, Freedman S, Beck A, Grajewski A, Levin AV. New classification system for pediatric glaucoma: implications for clinical care and research registry. *Curr Opin Ophthalmol.* 2018;29(5):385–394

[2]Lewis CJ, Hedberg-Buenz A, DeLuca AP, Stone EM, Alward WLM, Fingert JH. Primary congenital and developmental glaucomas. *Hum Mol Genet.* 2017;26(R1):R28–36.

[3]Zhao Y, Sorenson CM, Sheibani N. Cytochrome P450 1B1 and primary congenital glaucoma. *J Ophthalmic Vis Res.* 2015;10(1):60–67.

[4]Ko F, Papadopoulos M, Khaw PT. Primary congenital glaucoma. *Prog Brain Res.* 2015; 221:177–189.

[5] Freedman SF, Lynn MJ, Beck AD, Bothun ED, Öрге FH, Lambert SR; Infant Aphakia Treatment Study Group. Glaucoma-related adverse events in the first 5 years after unilateral cataract removal in the Infant Aphakia Treatment Study. *JAMA Ophthalmol.* 2015;133(8):907–914.

[6] Martinez-de-la-Casa JM, Garcia-Feijoo J, Saenz-Frances F, et al. Comparison of rebound tonometer and Goldmann handheld applanation tonometer in congenital glaucoma. *J Glaucoma.* 2009;18(1):49–52.

[7] Bradfield YS, Melia BM, Repka MX, et al; Pediatric Eye Disease Investigator Group. Central corneal thickness in children. *Arch Ophthalmol.* 2011;129(9):1132–1138.

[8]Allingham MJ, Cabrera MT, O’Connell RV, et al. Racial variation in optic nerve head parameters quantified in healthy newborns by handheld spectral domain optical coherence tomography. *J AAPOS.* 2013;17(5):501–506.

[9]Samarawickrama C, Pai A, Tariq Y, Healey PR, Wong TY, Mitchell P. Characteristics and appearance of the normal optic nerve head in 6-year-old children. *Br J Ophthalmol.* 2012;96(1):68–72.

UNDER PEER REVIEW