

Twiddler syndrome : A case report

Abstract

Background: Pacemaker (PM) devices are increasingly used to treat cardiac conduction abnormality especially in elderly population,. Twiddler syndrome (TS) in PM patients is a condition where patient manipulation of a pacemaker leads to its retraction and dysfunction. TS can be extremely dangerous in patient who depend on PM rhythm and therefore can be fatal

Case summary: We present the case of a 52-year-old women who underwent implantation of a of pacemaker for idiopathic third degree auriculo-ventricular block. Forty days after the operation she was admitted to the hospital for recurrent episodes of syncope. Chest radiographs confirmed lead retraction and suggested device manipulation. The patient was immediately transferred to the cath lab to perform a repositioning of the Pacemaker leads .

Discussion: This rare case highlights the life threatening aspect of Twiddler syndrome related to pacemaker . Hence rigorous fixationof the generator and leads is essential , close follow up and meticulous examination of EKG , X ray is primordial especially in the first year following the intervention . Finally patient should be educated not to manipulate their devices with clear explanation of potential consequence of such behavior .

Key words *Twiddler syndrome , pacemaker , dysfunction*

Introduction:

Twiddler syndrome (TS) is a condition where patient manipulation of an implanted device, a pacemaker or implantable defibrillator leads to its dysfunction . Generally the mechanism of manipulation is twisting ;causing the rotation of the generator and leads displacement(1) withthe majority of the cases being females patients some studies reported Body mass index , age ,depression and mental disorders as being risk factors for TS(2,3).TS related with pacemaker tend to be more dangerousSince in some conditions , without the Pacemaker stimulation , a third degree heart block wouldrapidly degenerate into a cardiac arrest leaving no time for proper medical intervention(4).We report the case of a 53 years old Moroccan women whopresenteditching in the site of Pacemaker device , leading to it manipulation and dysfunction forty days after its placement.

Case report:

A 53-years-old female patient, with history of hypothyroidism was admitted in our structure for high degree atrioventricular block after recurrent episodes of syncope . The patient underwent screening investigations to ensure no reversible cause was present and a dual chamber permanent pacemaker was implanted . The patient returned forty days later due to three episode of syncope she reported sensation of skin Pruritus leading to her manipulating the device . EKG was performed shortly after showing a third degree block with an escape rhythm of twenty four beats per minute . Chest X-ray showed coiled and retracted leads with the two leads in the right atrium while the pulse generator appeared with 360 degree rotation (Figure 1). The patient was immediately transferred to the cath lab to perform a repositioning of the Pacemaker leads the patient was given proper education prior to discharge . Routine device follow-up has revealed normal stimulated rhythm and patient was free of symptoms .

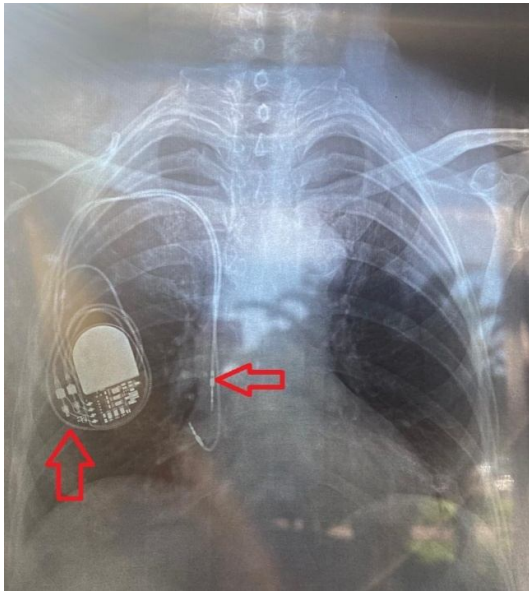


Figure 1: X-ray showing the pulse-generator with twisted ventricular lead around it and retracted ventricular lead (red arrows)

Discussion:

Twiddler syndrome is a form of Lead macro displacement (LMD) . It is relatively infrequent after implantation of cardiac implanted device ,with an estimated incidence during the first year of 0.07 - 7%(5). Many mechanisms of TS were described in some studies (twiddler type , flip type , reel type , ratched type) (6–8) . the mechanism of dislodgment in this case was a reel type with counter clock wise rotation leading to leads retraction and dysfunction TS is life threatening yet an easily avoided entity , countries with limited resources like Morocco should avoided it at all cost: mainly due to the limited access to tertiary hospital centers ,and due to the elevated cost of cardiac devices in comparison to GDP per capita . Special consideration should be given to females, elderly and patients with mental disease

The diagnostic of TS is easy in the case of devices dysfunction and recurrent symptoms , however it can be more challenging in others cases . meticulous follow up of patients is necessary for early intervention. chest X ray is accessible and gives precious information regarding the generator and leads placements

The question is how to avoid this dangerous phenomenon . It is known that the smaller the pocket , the lower are the risks of device displacement . Furthermore ,some authors suggested using Dacron pouch that promote tissue growth around the device and to limit its angle of rotation(9). Others encourage fixing the pulse generator to the pectoral muscle with nonabsorbable suture and active fixation of leads(10)with T. Fahraeus and C. J. Hoijerreserving this practice to patients with mental disorders, confusion or very lax subcutaneous tissues(11)

Despite all these measures , patients and family education remains pivotal for avoiding this fatal yet avertible syndrome(12)

Conclusion

Twiddler syndrome is a rare yet dangerous cause of cardiac device dysfunction. Therefore ,prevention is always better than treatment , and more attention should be given for educating and sensitizing patients .Rigorous fixation of the generator and leads it is also crucial for TS prevention.Close follow up and meticulous examination of EKG , X ray is essential especially in the first year following the intervention in order to detect and treat any disorder.

Patient Consent :

The patient has signed a legal consent to the submission of the case report to the journal.

Disclosures:

The authors have no funding and conflicts of interest to disclose.

References

1. Bayliss CE, Beanlands DS, Baird RJ. The pacemaker-twiddler's syndrome: a new complication of implantable transvenous pacemakers. *CMAJ*. 1968 Aug 24;99(8):371–3.
2. Gomez JO, Doukky R, Pietrasik G, Wigant RR, Mungee S, Baman TS. Prevalence and predictors of Twiddler's syndrome. *Pacing Clin Electrophysiol*. 2023 Feb 20;pace.14655.
3. Mandal S, Pande A, Kahali D. A Rare Case of Very Early Pacemaker Twiddler's Syndrome. *Heart Views Off J Gulf Heart Assoc*. 2012 Jul;13(3):114–5.
4. Tseng AS, Shipman JN, Lee JZ, Mi L, Amin M, Killu AM, et al. Incidence, patterns, and outcomes after transvenous cardiac device lead macrodislodgment: Insights from a population-based study. *Heart Rhythm*. 2019 Jan;16(1):140–7.
5. Ghani A, Delnoy PPHM, RamdatMisier AR, Smit JJJ, Adiyaman A, Ottervanger JP, et al. Incidence of lead dislodgement, malfunction and perforation during the first year following device implantation. *Neth Heart J*. 2014 Jun 1;22(6):286–91.
6. Vijay SK, Dwivedi SK, Chandra S, Saran RK. Ratchet-traction effect: an underdiagnosed mechanism of pacing lead dislodgement. *Indian Heart J*. 2014;66(5):555–6.
7. Fuertes B, Toquero J, Arroyo-Espiguero R, Lozano IF. Pacemaker lead displacement: mechanisms and management. *Indian Pacing Electrophysiol J*. 2003 Oct 1;3(4):231–8.
8. Arias MA, Pachón M, Puchol A, Jiménez-López J, Rodríguez-Picón B, Rodríguez-Padial L. Terminology management for implantable cardiac electronic device lead macro-dislodgement. *Rev Espanola CardiolEngl Ed*. 2012 Jul;65(7):671–3.
9. Shandling AH, Ellestad MH, Castellanet MJ, Messenger JC. Dacron-Woven Pacemaker Pouch*: Influence on Long-term Pacemaker Mobility. *CHEST*. 1991 Mar 1;99(3):660–2.
10. Pande A, Kahali D, Mandal S. A rare case of very early pacemaker Twiddler's syndrome. *Heart Views*. 2012;13(3):114.
11. Fahraeus T. Early pacemaker twiddler syndrome. *Europace*. 2003 Jul;5(3):279–81.
12. DeMarco DC, Xuereb RG. 'Twiddling' of the Pacemaker Resulting. 2009;21(03).