

# Twiddlersyndrome : A case report

## **Abstract**

**Background:** Pacemaker (PM) devices are increasingly used to treat cardiac conduction abnormality especially in elderly population, Twiddler syndrome (TS) in PM patients is a condition where patient manipulation of a pacemaker leads to its retraction and dysfunction. TS can be extremely dangerous in patient who depend on PM rhythm and therefore can be fatal

**Case summary:** We present the case of a 52-year-old woman who underwent implantation of a pacemaker for idiopathic third degree auriculo-ventricular block. Forty days after the operation she was admitted to the hospital for recurrent episodes of syncope. Chest radiographs confirmed lead retraction and suggested device manipulation. The patient was immediately transferred to the cath lab to perform a repositioning of the Pacemaker leads .

**Discussion:** This rare case highlights the life threatening aspect of Twiddler syndrome related to pacemaker . Hence rigorous fixation of the generator and leads is essential , close follow up and meticulous examination of EKG , X ray is primordial especially in the first year following the intervention . Finally patient should be educated not to manipulate their devices with clear explanation of potential consequence of such behavior .

**Key words** *Twiddlersyndrome , pacemaker , dysfunction*

## **Introduction:**

Twiddler syndrome (TS) is a condition where patient manipulation of an implanted device, a pacemaker or implantable defibrillator leads to its dysfunction . generally the mechanism of manipulation is twisting causing the rotation of the generator and leads displacement(1) with the majority of the cases are females, elderly, obese and psychiatric patients (2). TS related with pacemaker tend to be more fatal since in some conditions , without the Pacemaker stimulation , a third degree heart block will rapidly degenerate into a cardiac arrest leaving no time for proper medical intervention(3). We report the case of a 53 years old Moroccan woman who, presented this complication forty days after the placement of a Pacemaker device ?=.

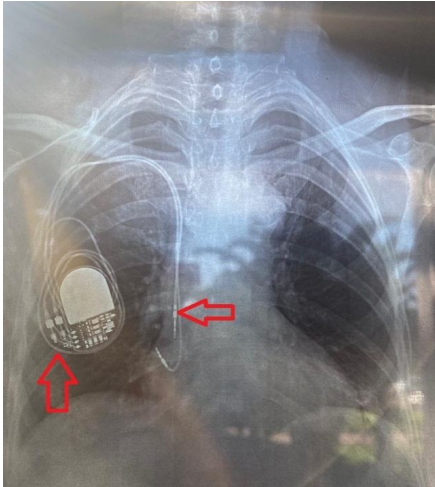
## **Case report:**

A 53-years-old female patient, with history of hypothyroidism was admitted in our structure for high degree atrioventricular block after recurrent episodes of syncope . The patient underwent screening investigations to ensure no reversible cause was present and a dual chamber permanent pacemaker was implanted. The patient returned forty days later due to three episodes of syncope she reported sensation of skin Pruritus leading to her manipulating the device . EKG was performed shortly after showing a third degree block with an escape rhythm of twenty four beats per minute . Chest X-ray showed coiled and retracted leads with the two leads in the right atrium while the pulse generator appeared with 360 degree rotation ( Figure 1 ). The patient was immediately transferred to the cath lab to perform a repositioning of the Pacemaker leads the patient was given proper education prior to discharge . Routine device follow-up has revealed normal stimulated rhythm and patient was free of symptoms .

**Comment [D1]:** Basic investigations and detail thyroid test. Was it autoimmune thyroiditis or something else ?

**Comment [D2]:** Whom and in which center pacemaker was implanted. need initial x-ray chest to show the position of pace maker.

**Comment [D3]:** Also attached ECG



**Figure 1:** X-ray showing the pulse-generator with twisted ventricular lead around it and retracted ventricular lead ( red arrows)

### **Discussion:**

Twiddler syndrome is a form of Lead macro displacement (LMD) . It is relatively infrequent after implantation of cardiac implanted device ,with an estimated incidence during the first year of 0.07 - 7%(4). Many mechanisms of TS were described in some studies ( twiddler type , flip type , reel type , ratched type ) (5-7) . the mechanism of dislodgment in this case was a reel type with counter clock wise rotation leading to leads retraction and dysfunction TS is life threatening yet an easily avoided entity , countries with limited resources like Morocco should avoided it at all cost: mainly due to the limited access to tertiary hospital centers ,and due to the elevated cost of cardiac devices in comparison to GDP per capita . Special consideration should be given to females, elderly and patients with mental disease

The diagnostic of TS is easy in the case of devices dysfunction and recurrent symptoms , however it can be more challenging in others cases . meticulous follow up of patients is necessary for early intervention. chest X ray is accessible and gives precious information regarding the generator and leads placements

The question is how to avoid this dangerous phenomenon . It is known that the smaller the pocket the lower are the risks of device displacement . Furthermore ,some authors suggested using Dacron pouch that promote tissue growth around the device and to limit its angle of rotation(8). Others encourage fixing the pulse generator to the pectoral muscle with nonabsorbable suture and active fixation of leads(9)

Twiddler syndrome is a rare yet dangerous cause of cardiac device dysfunction .prevention is always better than treatment. Hence more attention should be given to patient education ,rigorous fixation of the generator and leads . close follow up and meticulous examination of EKG , X ray is essential especially in the first year following the intervention .

### **Patient Consent :**

The patient has signed a legal consent to the submission of the case report to the journal.

### **Disclosures:**

The authors have no funding and conflicts of interest to disclose.

## **References**

1. Bayliss CE, Beanlands DS, Baird RJ. The pacemaker-twiddler's syndrome: a new complication of implantable transvenous pacemakers. *CMAJ*. 1968 Aug 24;99(8):371-3.
2. Mandal S, Pande A, Kahali D. A Rare Case of Very Early Pacemaker Twiddler's Syndrome. *Heart Views Off J Gulf Heart Assoc*. 2012 Jul;13(3):114-5.
3. Tseng AS, Shipman JN, Lee JZ, Mi L, Amin M, Killu AM, et al. Incidence, patterns, and outcomes after transvenous cardiac device lead macrodislodgment: Insights from a population-based study. *Heart Rhythm*. 2019 Jan;16(1):140-7.
4. Ghani A, Delnoy PPHM, Ramdat Misier AR, Smit JJJ, Adiyaman A, Ottervanger JP, et al. Incidence of lead dislodgement, malfunction and perforation during the first year following device implantation. *Neth Heart J*. 2014 Jun 1;22(6):286-91.
5. Vijay SK, Dwivedi SK, Chandra S, Saran RK. Ratchet-traction effect: an underdiagnosed mechanism of pacing lead dislodgement. *Indian Heart J*. 2014;66(5):555-6.
6. Fuentes B, Toquero J, Arroyo-Espiguero R, Lozano IF. Pacemaker lead displacement: mechanisms and management. *Indian Pacing Electrophysiol J*. 2003 Oct 1;3(4):231-8.
7. Arias MA, Pachón M, Puchol A, Jiménez-López J, Rodríguez-Picón B, Rodríguez-Padial L. Terminology management for implantable cardiac electronic device lead macro-dislodgement. *Rev Espanola Cardiol Engl Ed*. 2012 Jul;65(7):671-3.
8. Shandling AH, Ellestad MH, Castellanet MJ, Messenger JC. Dacron-Woven Pacemaker Pouch\*: Influence on Long-term Pacemaker Mobility. *CHEST*. 1991 Mar 1;99(3):660-2.
9. Pande A, Kahali D, Mandal S. A rare case of very early pacemaker Twiddler's syndrome. *Heart Views*. 2012;13(3):114.