

ORIGINAL RESEARCH ARTICLE

MORPHOMETRIC STUDY OF THE BREAST IN NULLIPAROUS NIGERIAN FEMALES AT THE UNIVERSITY OF PORT HARCOURT, RIVERS STATE, NIGERIA

ABSTRACT

Background: The breast, also known as the mammary gland, is an essential aesthetic feature in a woman. Anthropometric breast measurements are vital for research and in reconstructive surgery as a quantitative tool for preoperative and postoperative evaluation. **Aim:** This study aimed to measure morphometric parameters of the breast of nulliparous Nigerian females to establish reference baseline data for the region. **Methodology:** In this prospective descriptive and analytical study, 66 female students from the University of Port-Harcourt in Rivers State, Nigeria, ranging in age from 16 to 30, were used. Various morphometric parameters were observed and measured using measuring tape, a metre rule, and skin markers in a standing position. **Descriptive and inferential analysis of data was done** using Statistical Package for Social Sciences (SPSS) version 23. **Results:** Most of the mean values of the measured anthropometric parameters of the left breast were higher than the right but displayed no significant difference except the nipple and mammary projections, which showed a significant difference between the right and left breasts. This study on the morphometry of the female breast revealed the slender and severe ptosis shapes as the most prevalent breast shapes, while the least prevalent were the bell and pseudoptosis breast shapes. The mammary size volume showed the left breast to be significantly bigger than the right, while of all the breast parameters analysed, the nipple projection (left) and mammary projection (right) displayed significant differences in this study, with all the right and left measured breast parameters indicating a positive correlation. **Conclusion:** The values from this study can be used as a guide by plastic surgeons providing services to females of African descent requiring aesthetic and reconstructive breast surgeries, as well as in physical anthropological studies and racial identification.

Keywords: Morphometry, breastshape, and asymmetry.

INTRODUCTION

The **breast**, also known as the mammary **gland**, is a modified sweat gland found in both **sexes**; it **is** rudimentary in males but well developed in females after puberty. It is an accessory organ of the female reproductive system **that** provides nutrition to the **new-born** in the form of milk [1]. **It is an organ of attraction and a representation of femininity. In addition, it is a very dynamic organ of the human body that constantly changes in size and location throughout the course of a person's lifetime [2].** The female mammary glands are **significant** and attractive features, whose shape and size are subject to numerous factors [3]. They are the secondary sexual characteristics of the female gender and have many anatomic variations **concerning** volume, width, length, projection, density, composition, shape, and placement on the chest wall [4]. **Hormonal changes during adolescence and the first few years of adulthood affect the mammary gland's size and structure, and it takes three to four years of increased hormonal activity before the mammary gland takes on its ultimate shape [5].** The shape of the mammary gland in an adult woman is conical for those who are nulliparous and may become ptotic after breast feeding [6]. **An adult woman's mammary gland's size, stiffness, and nodularity can alter depending on her weight, menstrual cycle, gestation, and nursing. Obesity is a crucial factor [6] because the size and shape of the mammary gland varies depending on the amount of fat tissue present. It is common to see a discrepancy in size between the two mammary glands in women without endocrine problems [7]. With age, the amount of fatty and connective tissue in the mammary gland diminishes, and it gets smaller and ptotic. After menopause, the mammary gland may become asymmetric and exhibit irregularity upon probing.[6, 8].**

Morphometry is the quantitative analysis of size and shape and **measures** the form of organisms and their parts [9]. Measurements of the human body or its parts are important in any area of medicine. They are **particularly relevant** in plastic surgery, as millimetres or centimetres can make a difference in getting a positive result. Anthropometry of the mammary gland **aims to obtain** objective results for some universal reference points and parameters in different communities. Studies performed using these common points have revealed some differences between races and several geographical regions [10]. Early reports of breast measurements date as far back as **1970; since then,** many newer methods have been developed [11].

Direct and indirect anthropometry are two different measurement methods used for the mammary gland. Direct anthropometry is performed directly on the individual using tools such as a ruler, compass, protractor, callipers, and anthropometers [12]. Direct anthropometry has some measurement limitations, including difficulty in areas where the skin has protrusions and curves, improper application of pressure by rigid instruments during the measurement, questionable reproducibility due to chest wall movements during breathing, loss of initial posture due to fatigue and discomfort of the patient during relatively long evaluation periods, and even patient humiliation brought on by nude body exposure and measurement equipment use [13, 14].

Female mammary glands are difficult to measure accurately; however, objective and standardised measurements are necessary despite the limited acceptable measurement systems. Studies on the morphometry of the mammary gland have been done in different populations and races, but there have been very few studies done on African women.

This study was designed to examine the breast morphometry of female students at the University of Port-Harcourt in Nigeria who are nulliparous with the goal of figuring out the mean values of the morphometric parameters of the breast and the most common breast shape. Thus, the results of this study will be used as anthropometric research and reconstructive surgery reference data.

MATERIALS AND METHODS

This study used a prospective descriptive analysis of the anthropometric measurements of the breasts of young and nulliparous female students. The study population was females between the ages of 16 and 30 studying at the University of Port-Harcourt, Rivers State, Nigeria. Convenience sampling technique was used for this study based on the nature of the study. Sixty-six (66) nulliparous students who consented were used as a sample of convenience.

Inclusion Criteria.

Nulliparous female participants who consented were recruited only if they were: within the age range of 16–30 years; of Nigerian origin; studying at the University of Port Harcourt; and whose breast displayed normal physical development with no history of mammary gland disease, deformities or augmentation of the mammary gland, or previous injuries or burns to the mammary gland.

Exclusion Criteria

Nulliparous female participants who are not: within the age range of 16–30 years; Nigerians and non-Nigerians studying at the University of Port Harcourt; and whose breasts did not display normal physical development with a history of mammary gland disease, deformities or augmentation of the mammary gland, or previous injuries or burns to the mammary gland, were excluded from the study.

Procedure

Sixty-six (66) participants who volunteered to participate in the study and fulfilled the inclusion requirements were given a questionnaire. Each participant took off their clothes so that the breast could be viewed and the mammary gland could be seen unaided. After that, they either stood up straight or lied down to allow the researcher easy access to the mammary gland and to minimise mistakes.

In this study, the Quao et al. [15] methodology was utilised. All mammary gland measurements were made using a ruler with the individuals standing in anatomical position. The record sheets were prepared, and a skin marker was used to mark the major anatomical landmarks: the suprasternal notch, xiphoid process, nipple, areolar, midclavicular point, and anterior axillary line (AAL). All measurements were evaluated in centimetres (cm) except for height taken in metres, weight in kilogrammes (kg), and mammary volume in millilitres (ml). The following parameters were taken and recorded:

- I. Areolar diameter (AD): A meter rule was placed transversely along the centre of the nipple from one end of the areola (areola mammae) to the other end of the mammary gland.
- II. Nipple diameter (ND): A meter rule was used to measure transversely and placed along the centre of the nipple from one end to the other.
- III. Suprasternal notch to nipple distance (SNL): This measurement was taken from the suprasternal notch to the centre of each nipple using a ruler.
- IV. Nipple–nipple length (NNL): From the centre of one nipple to the other using a ruler in the horizontal axis.
- V. Nipple to Inframammary fold to distance (NIMF): This was taken vertically with a ruler from the inframammary fold to the nipple of each mammary gland; both left and right.
- VI. Midclavicular line to nipple length (CNL): This was taken vertically with a ruler from the middle of the clavicle to the nipple on each side.
- VII. Lateral radius (LR): This was taken vertically with a ruler from the nipple to the anterior axillary line (AAL) on each side.
- VIII. Medial radius (MR): This was taken vertically with a ruler from the nipple to xiphoid process of the mid sternal line(MSL) on each side.

- IX. Mammary projection (MP): Vertical distance from the chest wall to the highest point on the mammary gland using two rulers.
- X. Nipple projection (NP): Vertical height of the nipple from the mammary gland.
- XI. Mammary gland diameter (BD): The widest part of mammary gland was taken with a measuring tape circumferentially around the thorax at the level of the nipple.
- XII. Chest circumference under the Inframammary Fold (CCF): This was taken firmly with a measuring tape circumferentially around the thorax at the level of the inframammary fold.
- XIII. Chest circumference under the axilla (CCA): This was taken firmly with a measuring tape circumferentially around the upper part of the mammary gland at the level of the axilla.
- XIV. Mammary volume (MV) was calculated using the formula defined by Qiao *et al.*, [15] by inserting the measured MR, LR, and NIMF values for each subject:

$$MV = 1/3 \times 3.14 \times MP^2 \times (MR + LR + NIFL - MP).$$

The mammary volume was in millilitres (ml)

Data Analysis

Data analysis was done using the Statistical Package for the Social Sciences (SPSS) version 23. The result was expressed as mean and standard deviation (SD), while analysis of variance (ANOVA) and a t-test were used to compare differences in the mean breast anthropometric parameters between the left and right mammary glands. Finally, Pearson's correlation was used to determine the association or relationship between the left and right parameters of each breast. A P value of 0.05 was considered statistically significant.

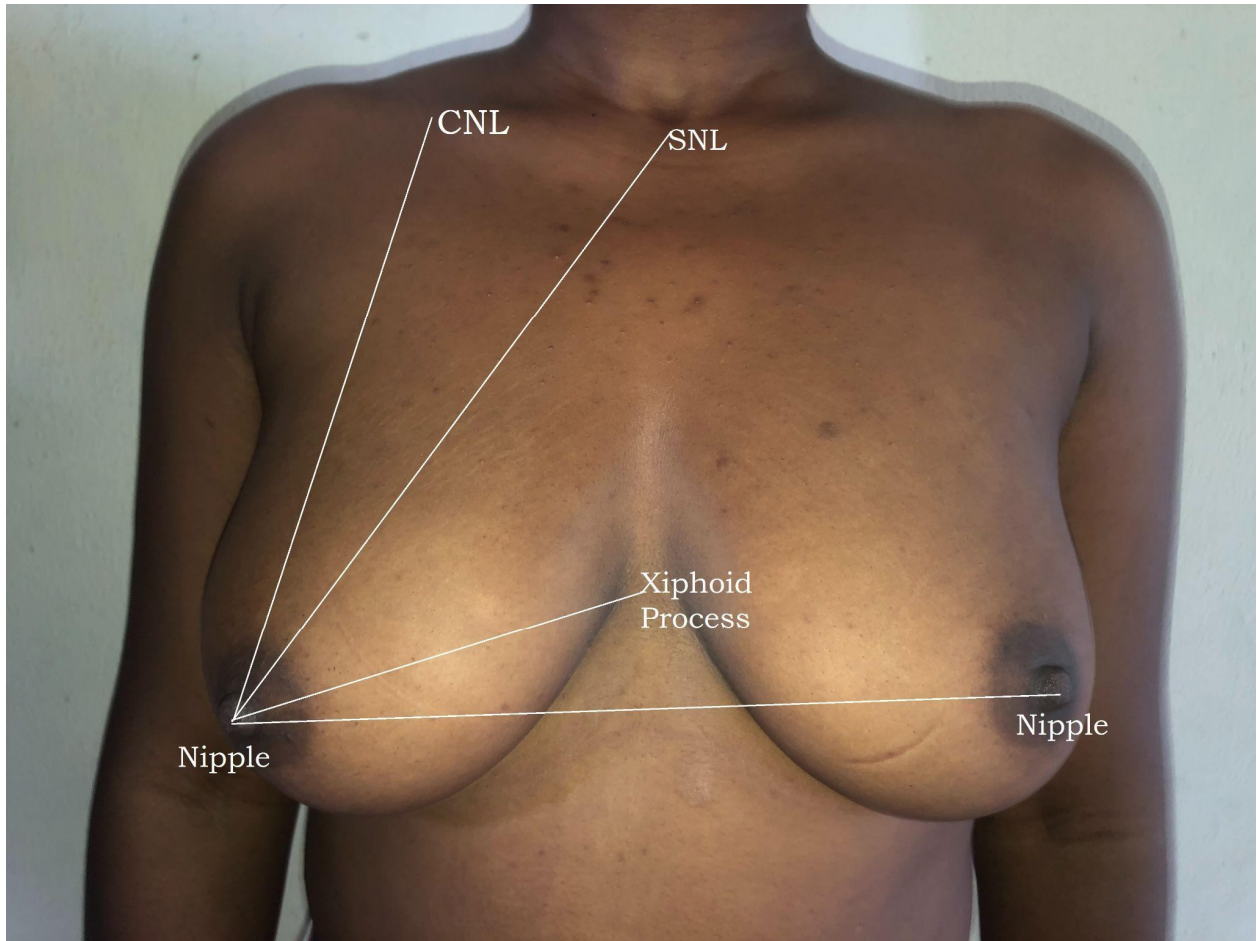


Figure 1: A 23-year-old subject of Grade C or 2 (moderate ptosis) / Archetype with the attribute of being side set showing some of the breast parameters measured. *CNL* midclavicular to nipple length. *SNL* Suprasternal notch to nipple distance

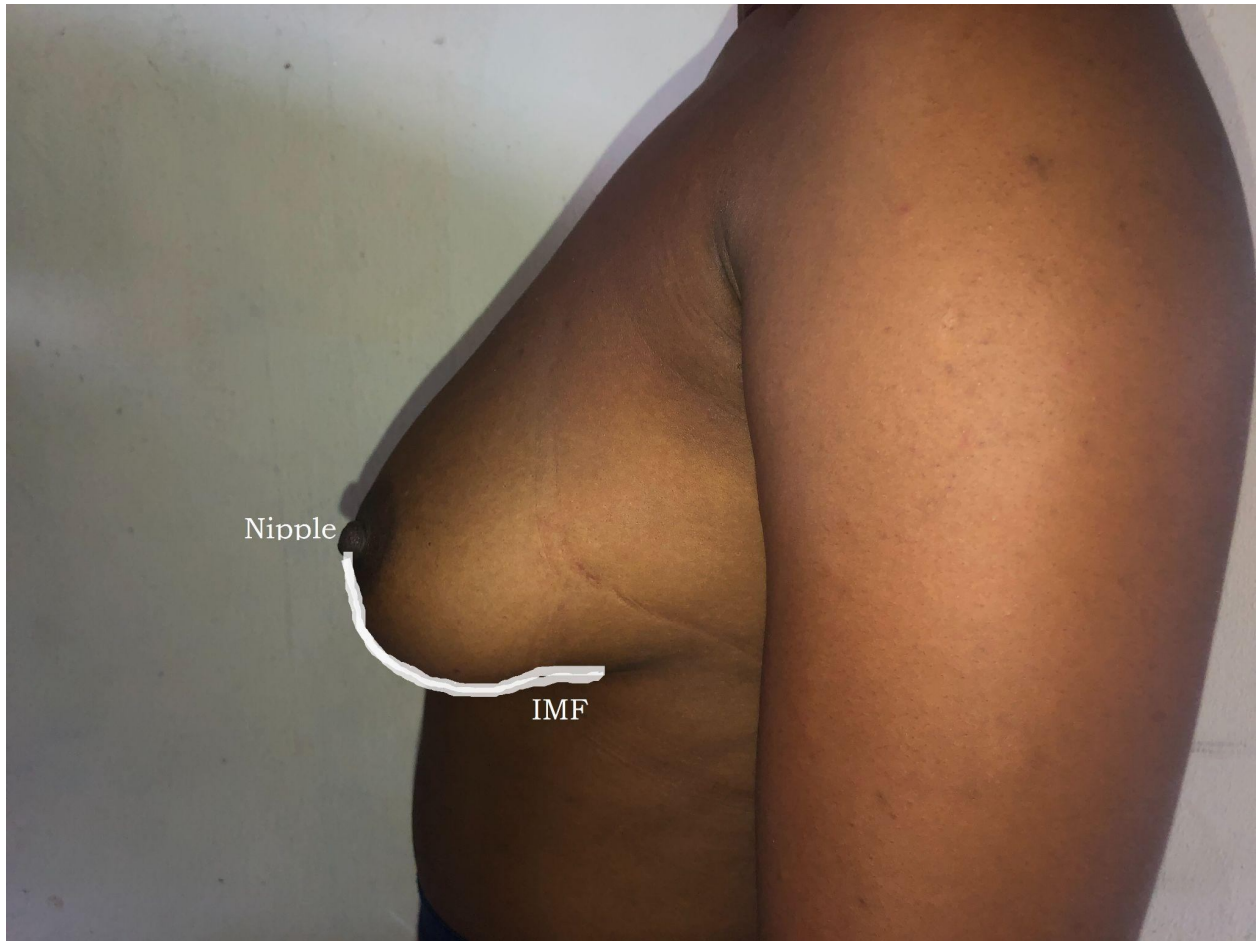

Figure 2: A23-year-old subject with Nipple inframammary fold length (NIMF) taken.

UNDER REVIEW

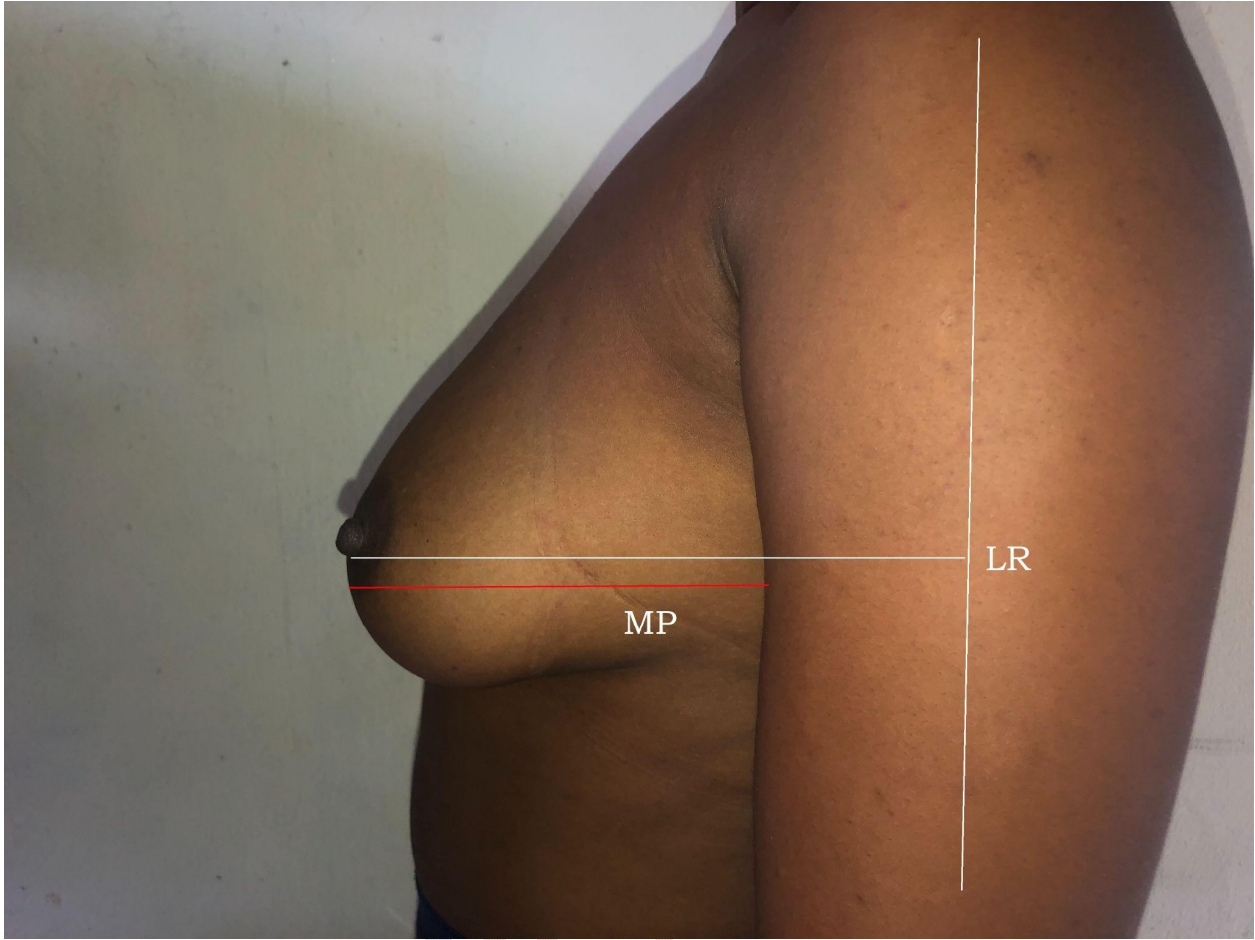


Figure 3: A 23-year-old subject showing the lateral radius (*LR*) and mammary projection (*MP*) respectively.

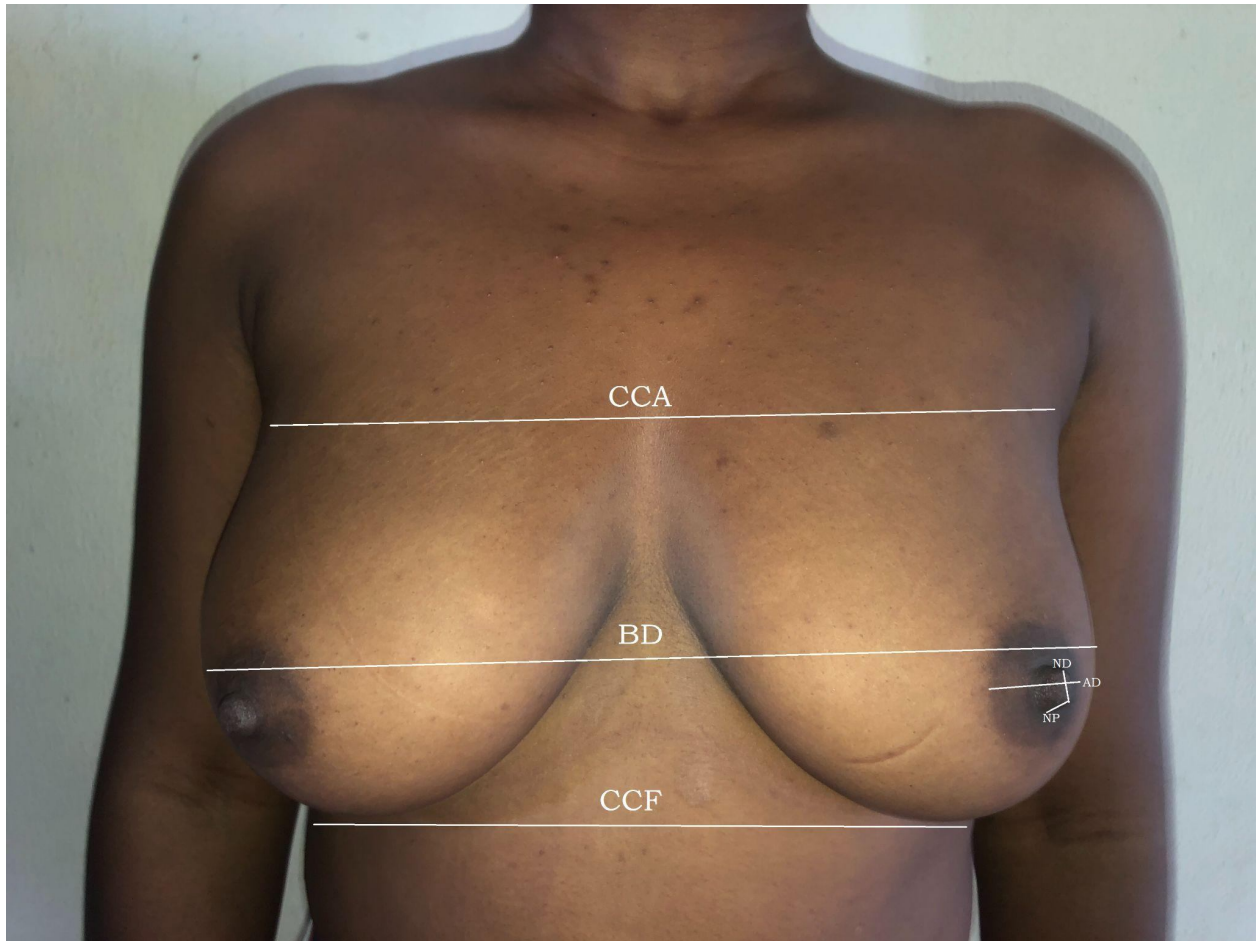


Figure 4: A 23-year-old subject of some of the breast parameters measured: *CCA* chest circumference under the axilla; *BD* Breast Diameter; *CCF* Chest circumference under the inframammary fold; *ND* Nipple diameter ; *AD* Areola diameter; *NP* Nipple projection.

LIMITATIONS OF THE STUDY

Most female students approached for this study were unwilling to participate due to the nature of the **study**, and this greatly affected the sample size.

Table 1: Descriptive statistics of Single mammary gland Parameters

Measurements	N	Min	Max	Mean (cm)	SE	SD
Nipple/nipple distance	66	15.0	30.0	22.20	0.52	4.19
CCA	66	63.0	109.0	78.27	1.59	12.93
mammary gland diameter	66	64.5	93.6	83.20	0.85	6.89
CCF	66	60.54	105.38	82.25	1.28	10.40

Values are given as **Mean** \pm **SE** for each group where **SE** is the Standard Error of mean; **Min** = *Minimum*, **Max** = *Maximum*, **SD** = *Standard Deviation*, **CCA** chest circumference over axilla; **CCF** chest circumference under the inframammary fold

Table 2: Age based statistical analysis of single morphometric parameters of mammary gland using one way analysis of variance.

MEASUREMENT (cm)	AGE RANGE (YRS)			P value	Inference
	16-20	21-25	26-30		
Nipple/nipple distance	22.11 \pm 0.89	22.61 \pm 0.67	20.88 \pm 1.58	0.58	N/S
CCA	80.11 \pm 2.62	76.06 \pm 2.08	80.63 \pm 5.55	0.43	N/S
mammary gland diameter	83.78 \pm 1.32	82.06 \pm 1.29	85.68 \pm 1.94	0.36	N/S
CCF	83.74 \pm 1.94	80.48 \pm 1.85	84.06 \pm 4.27	0.44	N/S

Values are given as **Mean** \pm **SE** for each group where **SE** is the Standard Error. **P**: statistical level of significance was determined by one-way Analysis of Variance (ANOVA). **P**<0.05 means significant; *N/S* not significant, **CCA** chest circumference over axilla; **CCF** chest circumference under the inframammary fold

Table 3: Comparison of right and left mammary gland parameters of females using paired sample t-test (N=66)

Measurements (cm)	mamma ry gland	MEAN±SE	t-Test	P value	INFERENCE
Areolar diameter	Right	4.17±0.14	-1.85	0.07	Not significant
	Left	4.33±0.14			
Nipple diameter	Right	0.62±0.21	-0.29	0.77	Not significant
	Left	0.63±0.21			
Nipple projection	Right	0.29±0.02	-5.01	0.00	Significant
	Left	0.32±0.02			
SNL distance	Right	22.64±0.36	-0.14	0.89	Not significant
	Left	22.66±0.37			
NIFL distance	Right	10.43±0.21	-0.69	0.49	Not significant
	Left	10.50±0.22			
CNL distance	Right	21.41±0.41	-0.14	0.89	Not significant
	Left	21.43±0.40			
Medial radius	Right	13.19±0.20	1.38	0.17	Not significant
	Left	12.97±0.24			
Lateral radius	Right	16.91±0.26	-1.63	0.11	Not significant
	Left	17.17±0.25			
Mammary projection	Right	10.62±0.29	2.71	0.01	Significant
	Left	10.30±0.26			

N=number of subjects, *t*= t-test, **P**<0.05 means significant. *SE*=Standard Error (**N**=sample size).

SNL sternal notch nipple length; *NIMF* nipple infra mammary fold length; *CNL* midclavicular point nipple length;

Table 4: Relationship between right and left mammary gland parameters of females using Pearson Correlation ®

Measurements (cm)	mamma ry gland	MEAN±SE	R	P value	INFERENCE
Areolar diameter	Right	4.17±0.14	0.82	0.00	Significant
	Left	4.33±0.14			
Nipple diameter	Right	0.62±0.21	0.86	0.00	Significant
	Left	0.63±0.21			
Nipple projection	Right	0.29±0.02	0.97	0.00	Significant
	Left	0.32±0.02			
SNL distance	Right	22.64±0.36	0.95	0.00	Significant
	Left	22.66±0.37			
NIFL distance	Right	10.43±0.21	0.89	0.00	Significant
	Left	10.50±0.22			
CNL distance	Right	21.41±0.41	0.96	0.00	Significant
	Left	21.43±0.40			
Medial radius	Right	13.19±0.20	0.77	0.00	Significant
	Left	12.97±0.24			
Lateral radius	Right	16.91±0.26	0.81	0.00	Significant
	Left	17.17±0.25			
Mammary projection	Right	10.62±0.29	0.91	0.00	Significant
	Left	10.30±0.26			

N=number of subjects, R=Pearson correlation or correlation coefficient, P<0.05. *SNL* sternal notch nipple length; *NIFL* nipple infra mammary fold length; *CNL* midclavicular point nipple length;

Table 5: Age range statistical analysis of right & left mammary gland parameters using one way analysis of variance.

Mammary gland Parameters		Age Range			P-value	Inference
Measurements (cm)	Position	16-20 (Mean/SD)	21-25 (Mean/SD)	26-30 (Mean/SD)		
Areola Diameter	Right	4.32±0.21	4.08±0.22	4.00±0.42	0.67	Not significant
	Left	4.50±0.22	4.22±0.21	4.15±0.41	0.61	Not significant
Nipple Diameter	Right	0.82±0.34	1.2±0.30	0.95±0.79	0.97	Not significant
	Left	0.8±0.35	1.0±0.30	1.03±0.67	0.92	Not significant
SNL	Right	22.78±0.59	22.26±0.50	23.63±1.21	0.49	Not significant
	Left	22.72±0.62	22.36±0.49	23.61±1.23	0.58	Not significant
NIFL Distance	Right	8.45±0.32	10.46±0.35	11.29±0.37	0.97	Not significant
	Left	8.46±0.32	10.57±0.37	11.39±0.46	0.96	Not significant
CNL Length	Right	21.95±0.72	20.79±0.57	22.00±0.91	0.38	Not significant
	Left	21.94±0.70	20.77±0.56	22.29±0.84	0.30	Not significant
Lateral Radius	Right	16.50±0.36	17.24±0.39	17.00±0.91	0.41	Not significant
	Left	17.13±0.36	17.21±0.36	17.13±0.90	0.99	Not significant
Medial Radius	Right	13.22±0.33	13.05±0.31	13.63±0.39	0.68	Not significant
	Left	13.11±0.38	12.75±0.38	13.38±0.52	0.66	Not significant
MP	Right	10.39±0.49	10.92±0.42	10.25±0.67	0.63	Not significant
	Left	10.16±0.41	10.53±0.39	9.88±0.62	0.67	Not significant
NP	Right	0.28±0.03	0.31±0.03	0.24±0.07	0.44	Not significant
	Left	0.29±0.03	0.34±0.03	0.29±0.05	0.45	Not significant

Values are given as Mean ± SE for each group where *SE* is the Standard Error. **P**: statistical level of significance was determined by One-Way Analysis of Variance (ANOVA). **P**<0.05 means

significant. *SNL* sternal notch nipple length; *NIFL* nipple infra mammary fold length; *CNL* midclavicular point nipple length; *MP* mammary projection; *NP* nipple projection;

Table 6: Comparison of the mean mammary gland parameters of present study with previous studies outside Africa.

Parameters	Workers	Country	Year	No of subjects studied (n)	Mean	SD
Areolar diameter	Al-Qattan <i>et.al.</i> ,	Saudi	2019	44	4.5	1.4
	Qiao <i>et.al.</i> ,	China	1997	125	3.32	0.4
	Present Study	Nigeria	2023	66	4.25	0.10
Nipple diameter	Westreich <i>et.al.</i> ,	Israel	1997	50	0.35	0.6
	Present study	Nigeria	2023	66	0.62	0.18
Nipple Projection	Demiroz <i>et.al.</i> ,	Turkey	2020	100	0.39	—
	Qiao <i>et.al.</i> ,	China	1997	125	0.46	0.16
	Westreich <i>et.al.</i> ,	Israel	1997	50	0.36	0.8
	Present study	Nigeria	2023	66	0.30	0.01
SNL distance	Demiroz <i>et.al.</i> ,	Turkey	2020	100	19.85	—
	Al-Qattan <i>et.al.</i> ,	Saudi	2019	44	19.8	2.5
	Qiao <i>et.al.</i> ,	China	1997	125	19.05	0.107
	Present study	Nigeria	2023	66	22.65	0.25
NNL distance	Demiroz <i>et.al.</i> ,	Turkey	2020	100	19.05	—
	Al-Qattan <i>et.al.</i> ,	Saudi	2019	44	20.3	2.3
	Westreich <i>et.al.</i> ,	Israel	1997	50	19.3	1.7
	Present study	Nigeria	2023	66	22.2	4.19
NIFL distance	Demiroz <i>et.al.</i> ,	Turkey	2020	100	7.35	—
	Al-Qattan <i>et.al.</i> ,	Saudi	2019	44	7.7	1.6
	Westreich <i>et.al.</i> ,	Israel	1997	50	5.1	1.0
	Present study	Nigeria	2023	66	10.45	0.15
CNL distance	Demiroz <i>et.al.</i> ,	Turkey	2020	100	19.25	—

	Qiaoet.al.,	China	1997	125	19.26	0.09
	Westreichet.al.,	Israel	1997	50	18.8	1.5
	Present study	Nigeria	2023	66	21.42	0.29
Medial Radius	Qiaoet. al.,China	1997	44	10.03	0.08	
	Present Study	Nigeria	2023	66	13.08	0.16
Lateral Radius	Demirozet.al.,	Turkey	2020	100	10.05	—
	Qiaoet. al.,	China	1997	44	9.6	0.1
	Present study	Nigeria	2023	66	17.04	0.18
Mammary projection	Demirozet.al.,	Turkey	2020	100	10.95	—
	Qiaoet.al.,	China	1997	44	3.6	0.06
	Present study	Nigeria	2023	66	10.46	0.19
CCA	Qiaoet.al.,	China	1997	125	79.6	0.4
	Present study	Nigeria	2023	66	78.27	12.93
BD	Qiaoet.al.	China	1997	44	81.4	0.489
	Present study	Nigeria	2023	66	83.20	6.89
CCF	Demirozet.al.,	Turkey	2020	100	77.9	—
	Westreichet.al.,	Israel	1997	50	71.9	4.5
	Present study	Nigeria	2023	66	82.25	10.40

AD areolar diameter;**BD** mammary gland diameter; **MV** mammary volume; **SNL** sternal notch nipple length;**NIFL** nipple infra mammary fold length; **CNL** midclavicular point nipple length; **MP** mammary projection; **NP** nipple projection; **MR** medial radius; **LR** lateral radius; **NNL** nipple to nipple length;**CCA** chest circumference over axilla;**CCF** chest circumference under the inframammary fold and **ND** nipple diameter.

Table 7: Comparison of the mean mammary gland parameters in the present study with other Nigerian studies and Ghana.

Parameters	Workers	Country	Year	Subjects studied (n)	Mean	SD
AD	Archibong et al	Nigeria	2022	370	4.5	1.4
	Isiweleet <i>al.</i> ,	Nigeria	2020	500	3.32	0.4
	Present Study	Nigeria	2023	66	4.25	0.10
ND	Archibong et al	Nigeria	2022	370	3.49	0.6
	Isiweleet <i>al.</i> ,	Nigeria	2020	500	3.9	—
	Present study	Nigeria	2023	66	0.62	0.18
NP	Archibong et al	Nigeria	2022	370	0.28	0.30
	Present study	Nigeria	2023	66	0.30	0.01
SNL distance	Agbenorku et al	Ghana	2010	438	20.64	—
	Archibong et al	Nigeria	2022	370	22.10	3.50
	Isiweleet <i>al.</i> ,	Nigeria	2020	500	21.12	1.99
	Present study	Nigeria	2023	66	22.65	0.25
NNL distance	Archibong et al	Nigeria	2022	370	21.70	3.50
	Isiweleet <i>al.</i> ,	Nigeria	2020	500	21.12	—
	Present study	Nigeria	2023	66	22.2	4.19
NIFL distance	Agbernorku et al	Nigeria	2010	438	9.28	—
	Archibong et al	Nigeria	2022	370	9.90	2.50
	Isiweleet <i>al.</i> ,	Nigeria	2020	500	8.20	—
	Present study	Nigeria	2023	66	10.45	0.15
CNL distance	Archibong et al	Nigeria	2022	370	21.08	3,69
	Isiweleet <i>al.</i> ,	Nigeria	2020	500	—	0.4
	Present Study	Nigeria	2023	66	21.42	0.29

MR	Agbenorku et al	Nigeria	2010	438	10.89	—
	Archibong et al	Nigeria	2022	370	12.87	2.59
	Present study	Nigeria	2023	66	13.08	0.16
LR	Archibong et al	Nigeria	2022	100	13.92	2.60
	Present study	Nigeria	2023	66	17.04	0.18
MP	Archibong et al	Nigeria	2022	370	6.50	1.26
	Present study	Nigeria	2023	66	10.46	0.19
NNL distance	Archibong et al	Nigeria	2022	370	21.70	2.22
	Egiehiokhin et al	Nigeria	2020	500	21.12	—
	Present study	Nigeria	2023	66	22.20	4.19
CCA	Archibong et al	Nigeria	1997	370	83.06	6.35
	Present study	Nigeria	2023	66	78.27	12.93
BD	Archibong et al	Nigeria	2022	370	88.18	8.14
	Egiehiokhin et al	Nigeria	2020	500	73.65	—
	Present study	Nigeria	2023	66	83.20	6.89
CCF	Egiehiokhin et al	Nigeria	2020	500	84.76	—
	Present study	Nigeria	2023	66	82.25	10.40

AD areolar diameter *BD* mammary gland diameter; *MV* mammary volume; *SNL* sternal notch nipple length; *NIFL* nipple infra mammary fold length; *CNL* midclavicular point nipple length; *MP* mammary projection; *NP* nipple projection; *MR* medial radius; *LR* lateral radius; *NNL* nipple to nipple length; *CCA* chest circumference over axilla; *CCF* chest circumference under the inframammary fold and *ND* nipple diameter

RESULT AND DISCUSSION

This study has shown that there is some degree of asymmetry between the left and right mammary glands of the female subjects, with the left being slightly bigger. This asymmetry between paired body parts like the breast is quite common and normal. The mean right and left breast volumes in this study were 402.54 mL and 449.76 mL, respectively. This work revealed

the left breast to be bigger than the right in most of the subjects. This is in conformity with the findings from breast anthropometric studies in Israel [14], the United States of America [20], Ghana [16], and Nigeria [17], who all reported the left breast to be slightly bigger than the right. However, findings in the studies from Turkey [4, 21] were at variance with this present study. The average breast volume from this work is therefore 426.15 mL, which is higher than the 200 mL breast volume that was reported in the United States of America for African women [22].

Age is vital when carrying out morphometric breast analysis because the breast is a very dynamic organ of the human body, continuously changing in size and position with the passage of time. The mean age found in this study was 19.30 years, two years older than the mean age of 17 years (16–22 years) found in a study on 438 adolescent females conducted by Ghanaian researchers [16]. Like the study in Ghana, ours studied nulliparous breasts, bearing in mind that every woman coming for an aesthetic breast procedure would expect her breasts to be more youthful-looking and not sagging or with minimum ptosis [17].

Two out of the nine breast parameters measured showed statistically significant differences: the mean mammary projection and the mean nipple projection, which were significantly higher on the right and higher on the left, respectively. The mean values of the remaining seven parameters: areola diameter (AD), nipple diameter (ND), suprasternal notch to nipple length distance (SNL), nipple to inframammary fold length (NIMF), mid-clavicular to nipple length distance (CNL), medial radius (MR), and lateral radius (LR), although not significant, all displayed higher mean values on the left mammary gland. These findings tend to agree with studies done in Ghana [16], Lagos, Nigeria [17], and Israel [14], but were at variance with the study in Turkey [4], which had the parameters of the right breast significantly higher. The concurrence of our study with that from Lagos, Nigeria, and Ghana may be due to the fact that both studies were of the West African region, and as such, the females from these studies displayed similar morphometric features as Africans. The non-significant difference in the areolar diameter and nipple diameter of the right and left breast in this study was in agreement with the findings in studies in Nigeria [16], Turkey [4], and Israel [14].

There was a positive correlation between all nine breast parameters between the left and right breast. This was similar to the findings in Turkey [4, 21], Israel [14], China [15], and Lagos, Nigeria [17].

On the age-based analysis of the four single breast morphometric parameters (nipple-nipple length (NNL), mammary gland diameter (BD), chest circumference under the inframammary fold (CCF), and chest circumference under the axilla (CCA)) measured, none showed a significant difference. The mean values of NNL (22.20cm), BD (83.20cm), CCF (82.25cm), and CCA (78.27cm) in this present study varied from those recorded in previous studies.

The mean NNL from this study of 22.20cm was the highest when compared to previous studies: Lagos, Nigeria, 21.70cm [17], Ghana, 21.78 cm [16], Saudi Arabia, 20.3 cm [3], Korea, 18.5 cm [25], Turkey, 19.9 cm [4], and Israel, 19.33 cm [14].

The NIMF mean value was higher in this study (10.45cm) compared to values for Ghana (9.2 cm) [16], Turkey (6.64 cm) [23], Belgium (6.94 cm) [18], and South Africa (6.74 cm) [24]. A close analysis of these values suggests the NIMF in black African females is longer than that of white females. Despite the fact that the study by Vandepu et al., in Belgium [18], did not exclude non-nulliparous subjects and also that the highest age was up to 60 years, the NIMF was still less than what was obtained from our study. Furthermore, comparing the study of the Ghanaian females with ours, a lower NIMF mean value was expected because the age groups studied were younger than the age groups in this present study, and it was expected that NIMF would increase with age, but this was not the case.

The mean SNL value from this study was 22.65 cm, which was the highest when compared to previous studies: Ghana: 20.64 cm [16]; Lagos, Nigeria: 22.10cm [17]; Saudi Arabia: 19.8cm [3]. China, 19.05cm [15].

The mean areolar diameter (AD) of 4.25cm from this study was lower than that in Saudi Arabian females (4.5cm) [3] but higher than that in Chinese females (3.32 cm) [15].

The nipple diameter (ND) of 0.62cm from this study was higher than that of Israeli females (0.35 cm) [14], while the nipple projection (NP) of 0.30cm from this study was the least when compared to Israel (0.36cm) [14], Turkey (0.39cm) [19, 23], and China (0.46cm) [15].

The average distance between the nipple and the midline in the xiphoid area, or the medial radius (MR), was 13.08 cm in our study. This is higher than the values found in earlier research from Ghana (11.0 cm), Nigeria (12.87 cm), and Turkey (19 cm) in women.

The breast shape, based on the classification study done by Johnson [26], was classified into thirteen (13) shapes, namely: archetype, round, asymmetrical, athletic, bell shape, close set, conical, east-west, relaxed, side set, slender, and teardrop. Based on this classification, this present study revealed that 25 (38%) subjects had a slender breast shape, 23 (34%) subjects had an archetype breast shape, 11 (17%) subjects had both side-set and teardrop breast shapes, and the remaining 7 (11%) subjects had a bell-shaped breast. Furthermore, in another classification, according to Avsar et al. [4], who studied the breasts of 385 Turkish females, they classified or categorized the female breast shape in five classes: Ideal breast shape (Grade A or Grade zero), mild ptosis shape Grade B or Grade 1), moderate ptosis shape (Grade C or Grade 2) severe ptosis shape (Grade D or Grade 3), and pseudoptosis shape (Grade E or Grade 4). Based on this classification, results in this present study revealed 23(34.8%) subjects have severe ptosis shape, 17(25.75%) subjects have moderate ptosis shape, 13 (20.2%) subjects have ideal breast shape, 7(11.5%) subjects had mild ptosis shape and the remaining 5(7.8%) subjects had pseudoptosis shape. From both classifications, the most prevalent breast shapes are the slender and severe ptosis breast shapes.

CONCLUSION

We conclude that baseline reference values for the morphometric parameters of the breast of nulliparous females have been generated that show racial variation. These values can be used as a guide by plastic surgeons providing services to females of African descent requiring aesthetic and reconstructive breast surgeries, as well as in physical anthropological studies and racial identification. Besides, the slender and severe ptosis shapes are the most prevalent breast shapes, while the bell and pseudoptosis shapes are the least prevalent. The mammary size volume showed the left breast to be significantly bigger than the right, while of all the analysed breast parameters, the nipple projection (left) and mammary projection (right) displayed significant differences in this study, with all the right and left measured breast parameters displaying a positive correlation.

Ethical Approval and Consent

The University of Port Harcourt Research and Ethics committee granted ethical clearance, and their research methodology in accordance with best practises was strictly followed. Participants also provided their consent after being fully informed.

REFERENCES

1. Chaurasia, B. D. (2017). Human Anatomy Upper Limb and Thorax Volume 1: Regional and Applied Dissection and Clinical Anatomy (6th ed.). CBS Publishers & Distributors.
2. Isiwele E, Nnabuko RE, Ogbonnaya IS (2020). Morphometric analysis and key dimensions of the female breast: a baseline study of 500 nulliparous Nigerian females. *Nigerian J PlastSurg*;16:27-31
3. Al-Qattan M.M, Aldakhil S.S, Al-Hassan T.S (2019). Anthropometric Breast Measurement: Analysis of the Average Breast in Young Nulliparous Saudi Female Population. *PlastReconstrSurg Glob Open* 7:e2326. DOI: 10.1097/GOX.0000000000002326.
4. Avşar D.K., Aygıt A.C., Benlier E (2010). Anthropometric breast measurement: a study of 385 Turkish female students. *AesthetSurg J.* 30:44–50.
5. Tortora G. J., & Derrickson, B (2017). Principles of anatomy and physiology. John Wiley & Sons.
6. Moore K. L., & Dalley, A. F (2018). Clinically oriented anatomy. Wolters Kluwer, 8th Edition.
7. Loukas M., Hullett, J., Louis, R. G., & Kapos T. (2011). Breast symmetry: a review. *The Breast Journal*, 17(6), 569-581.
8. Moore K.L & Dalley A.F (2006). Clinically oriented anatomy, 5th edition, p. 105 – 111.
9. Rohlf F. J., & Marcus L. F. (1993). A revolution morphometrics. *Trends in Ecology & Evolution*, 8(4), 129-132.
10. Quieregatto P. R., Bernardo Hochman, Ferrara S.F., Fabianne Furtado, Liebano R. E., Miguel Sabino Neto, Ferreira L. M (2014). Anthropometry of the Breast Region: How to Measure? *Aesthetic Plastic Surgery*, 38, 344-349. DOI: 10.1007/s00266-014-0291-9.
11. Bouman F.G (1970). Volumetric measurement of the human breast and breast tissue before and during mammoplasty. *Br J PlastSurg* ; 23:263–264.
12. Nechala P., Mahoney J., Farkas L (1999). Digital two-dimensional photogrammetry: a comparison of the three techniques of obtaining digital photographs. *PlastReconstrSurg* 103(7): 1819–1825 2.

13. Hochman B, Castilho HT, Ferreira LM (2002). Padronizaçãofotográfica e morfométricafotogrametriacomputadorizada do nariz. *Acta Cir Bras* 17(4):258–266.
14. Westreich M. (1997). Anthropomorphic breast measurement: protocol and results in 50 women with aesthetically perfect breasts and clinical application. *PlastReconstr Surg.* 100(2):468–479.
15. Qiao Q., Zhou G., & Ling, Y (1997). Breast volume measurement in young Chinese women and clinical applications. *Aesthetic plastic surgery*, 21(4), 266-271. doi: 10.1007/s002669900164
16. Agbenorku M., Iddi A., Amevor E., Sefenu R., Osei D (2011). Measurements of breasts of young west African females: A guideline in anatomical landmarks for adolescent breast surgery. *Aesthetic PlastSurg* 35:49-54.
17. Archibong O.R., Abikoye F.O., Osisanya T.O (2021). Anthropometric breast measurements of nulliparous women in Lagos Nigeria. *J West Afr Coll Surg* 11:1-6.
18. Vandeput J.J., Nelissen M (2002). Considerations on anthropometric measurements of the female breast. *AesthPlastSurg* 26:348-55.
19. Dilek K.A., Ahmet C.A., Erol B., Hu'sametdin T., Oguz T (2010). Anthropometric breast measurement: a study of 385 Turkish female students. *AesthetSurg J* 30(1):44–50.
20. Losken A., Fishman I., Denson D.D., Moyer H.R., Carlson G.W (2005). An objective evaluation of breast symmetry and shape differences using 3-dimensional images. *Ann PlastSurg* 55:571-5.
21. Demiroz, A., Turkmen, A., Yıldız, T. F., &Daghan, B. (2020). Anthropometric breast measurements of young women with no history of pregnancy or surgery in Turkey. *Journal of Plastic Surgery and Hand Surgery*. <https://doi.org/10.1080/2000656X.2020.1817>.
22. Anderson J.D., Chandler S.C., Mason M.A., Khan C.B., Lindsay J.E., *et al.*, (2013). Scientific analysis reveals major differences in breast size of women in different countries. *J Female Health Sci; JFH.TD.13.098:268-92*
23. Smith D.J Jr, Palin W.E Jr, Katch V.L, *et al.*, (1986). Breast volume and anthropomorphic measurements: normal values. *PlastReconstr Surg.* 78(3):331–335.
24. Penn J (1954). Breast reduction. *Br J Plast Surg.* 7:357–371.
25. Kim, M., & Kim, M. J. (2014). The affecting factors of breast anthropometry in Korean women. *Breastfeeding Medicine*, 9, 73-78. doi: 10.1089/bfm.2013.0097.

26. Johnson M.Z (2019). What Are the Most Common Breast Shapes? Healthline Online Publication. DOI: <https://www.healthline.com/health/breast-shapes#shapes>.
27. Kim, M. S., Sbalchiero, J. C., Reece, G. P., Miller, M. J., Elisabeth, K., & Markey, M. K. (2008). Assessment of breast aesthetics. *Plastic and Reconstructive Surgery*, 121, 186e-194e.

UNDER PEER REVIEW