

# **MORPHOMETRIC STUDY OF THE BREAST: A STUDY OF 66 NIGERIAN FEMALE STUDENTS OF THE UNIVERSITY OF PORT HARCOURT, RIVERS STATE, NIGERIA.**

## **ABSTRACT**

The breast, also known as the mammary gland is an important aesthetic feature in a woman. Anthropometric breast measurements are important for research and are significant in the legal field as a quantitative tool for preoperative and postoperative evaluation. This study was aimed at measuring breast values in nulliparous Nigerian females, thus establishing reference data for the region. This was a prospective descriptive analytical study that used sixty-six (66) female students of the University of Port-Harcourt, Rivers State Nigeria between ages 16 and 30 years. Various morphometric parameters were observed and measured using measuring tape, meter rule and skin markers in standing position. Data obtained were analyzed using Statistical Package for Social Sciences (SPSS) version 23 and Student's t-test. Most of the mean anthropometric values of the left breast were higher than the right but displayed no significance difference except the nipple and mammary projections only which showed significant difference between the right and left breasts. This study on the morphometry of the female breast using students of the University of Port Harcourt revealed the slender and severe ptosis shapes as the major breast shapes while the least were the bell and the pseudoptosis breast shapes based on two classifications. The mammary size volume showed the left breast to be significantly bigger than the right, while of all the analyzed breast parameters, the nipple projection (left) and mammary projection (right) displayed significant differences in this study with all the right and left measured breast parameters displaying a positive correlation. The values from this study can be used as a guide by plastic surgeons providing services to females of African descent requiring aesthetic and reconstructive breast surgeries as well as in physical anthropological studies and racial identification.

**Keywords: Morphometry, breast, shape & asymmetry.**

## **INTRODUCTION**

The breast also known as the mammary gland is a modified sweat gland found in both sexes, rudimentary in the males but well developed in females after puberty. It is an accessory organ of

the female reproductive system which provides nutrition to the newborn in the form of milk [1]. It is also an organ of attraction and a symbol of femininity; a very dynamic organ of the human body, continuously changing in size and position during the life of a person [2]. The female mammary glands are important and attractive features, whose shape and size are subject to numerous factors [3]. They are the secondary sexual characteristics of the female gender and have many anatomic variations with respect to volume, width, length, projection, density, composition, shape, and placement on the chest wall [4]. Changes in the shape of the mammary gland and dimensions during adolescence and early adulthood are caused by hormonal changes and the final shape of the adult mammary gland results after three to four years of increased hormonal activity [5]. The shape of the mammary gland in an adult woman is conical for those who are nulliparous and may become ptotic after breast feeding [6]. Size, stiffness, and nodularity of the mammary gland in an adult woman may change with weight, menstrual period, gestation, and lactation. The size and shape of the mammary gland also vary depending on the fat tissue content thus making obesity an important factor [6]. A size difference between the two mammary glands in women who do not have any endocrine disorder is frequently observed [7]. After menopause, the mammary gland can become asymmetric, displaying irregularity on palpation and with aging, the amount of fatty and connective tissue of the mammary gland decreases, and it becomes smaller and ptotic [6,8].

Morphometry is the quantitative analysis of size and shape and is the measurement of the form of organisms and their parts [9]. Measurements of the human body or its parts are an important chapter in any area of medicine. They are of particular relevance in plastic surgery as millimeters or centimeters can make a difference in getting a positive result. Anthropometry of the mammary gland is aimed at obtaining objective results for some universal reference points and parameters in different communities. Studies performed using these common points have revealed that there are some differences between races and several geographical regions [10]. Early reports of the breast measurements date as far back as 1970 and since then many newer methods have been developed [11].

Direct and indirect anthropometry are two different measurement methods used for the mammary gland. Direct anthropometry is performed directly on the individual using tools such as a ruler, compass, protractor, calipers, and anthropometers [12]. Direct anthropometry has

some measurement limitations such as difficulty in regions with protrusions and curvatures of the skin, inappropriate application of pressure on the skin by rigid instruments during the measurement, questionable reproducibility due to movements of the chest wall during breathing, loss of initial posture due to fatigue and discomfort of the patient during relatively long evaluation periods, and even patient embarrassment due to the exposure of the naked body and application of measurement tools [13,14].

Female mammary glands are difficult to measure accurately; however, objective and standardized measurements are absolutely necessary despite limited acceptable systems of measurement. Studies on morphometry of the mammary gland have been done in different populations and races but there have been very few studies done on the African woman.

Based on this, this research was conceived to investigate the breast morphometry in nulliparous female students of the University of Port-Harcourt, Nigeria with the objectives of determining the mean dimensions of the breast parameters, breast size/volume and the most prominent breast shape. The findings from this study will thus serve as a reference data for anthropometric research and reconstructive surgery.

## **MATERIALS AND METHODS**

### **Study Design**

This study was done using a prospective descriptive analysis of the anthropometric measurements of the breast of young female students.

### **Study Population**

The study population is females between the ages of 16 years and 30 years studying in the University of Port-Harcourt, Rivers State, Nigeria.

### **Ethical Clearance**

Ethical clearance was obtained from the University of Port Harcourt Research and Ethics committee and their research protocol in line with standard practice was strictly adhered to.

## **Sampling Technique**

Convenience sampling technique was used for this study based on the nature of the study. The University of Port Harcourt estimated the number of female students is about 18,000 which is 54.17% of the entire school's population. Thus, 18,000 students become our population (N). Each of the 18,000 students is known as a unit, a case or an object. In order to select a sample (n) of students from this population of 18,000 students, 66 students who consented were used as a sample of convenience because of the nature of the study.

## **Inclusion & Exclusion Criteria.**

Nulliparous female Participants who consented were recruited only if they are within the age range of 16-30 years who are of Nigerian origin studying in the University of Port Harcourt whose breast displayed normal physical development with no history of mammary gland disease, deformities or augmentation of the mammary gland, previous injuries or burns to the mammary gland,

## **Procedure**

A questionnaire was issued to the sixty six (66) participants who volunteered to participate in the research and who met the inclusion criteria. Each participant undressed to expose the breast and to allow the mammary gland to be seen without support. They thereafter stood in an upright position or supine position so as to grant the researcher easy access to the mammary gland and also to reduce researcher's error. Methodology by *Quao et. al.*, [15] was adopted for this study and all measurements on the mammary glands were taken with a ruler with the subjects in the standing position with their heads upright and upper limbs by their sides. The record sheets were prepared and skin marker was used to mark the major anatomical landmarks: suprasternal notch, xiphoid process, nipple, areolar, midclavicular point, and anterior axillary line (AAL). All measurements were evaluated in centimeters (cm) except for height taken in meters, weight in kilograms (kg) and mammary volume in millimeters (ml). The following under listed parameters were taken and recorded:

- I. Areolar diameter (AD): A meter rule was placed transversely along the center of the nipple from one end of the areola (areola mammae) to the other end of the mammary gland.
- II. Nipple diameter (ND): A meter rule was used to measure transversely and placed along the center of the nipple from one end to the other.
- III. Suprasternal notch to nipple distance (SNL): This measurement was taken from the suprasternal notch to the center of each nipple using a ruler.

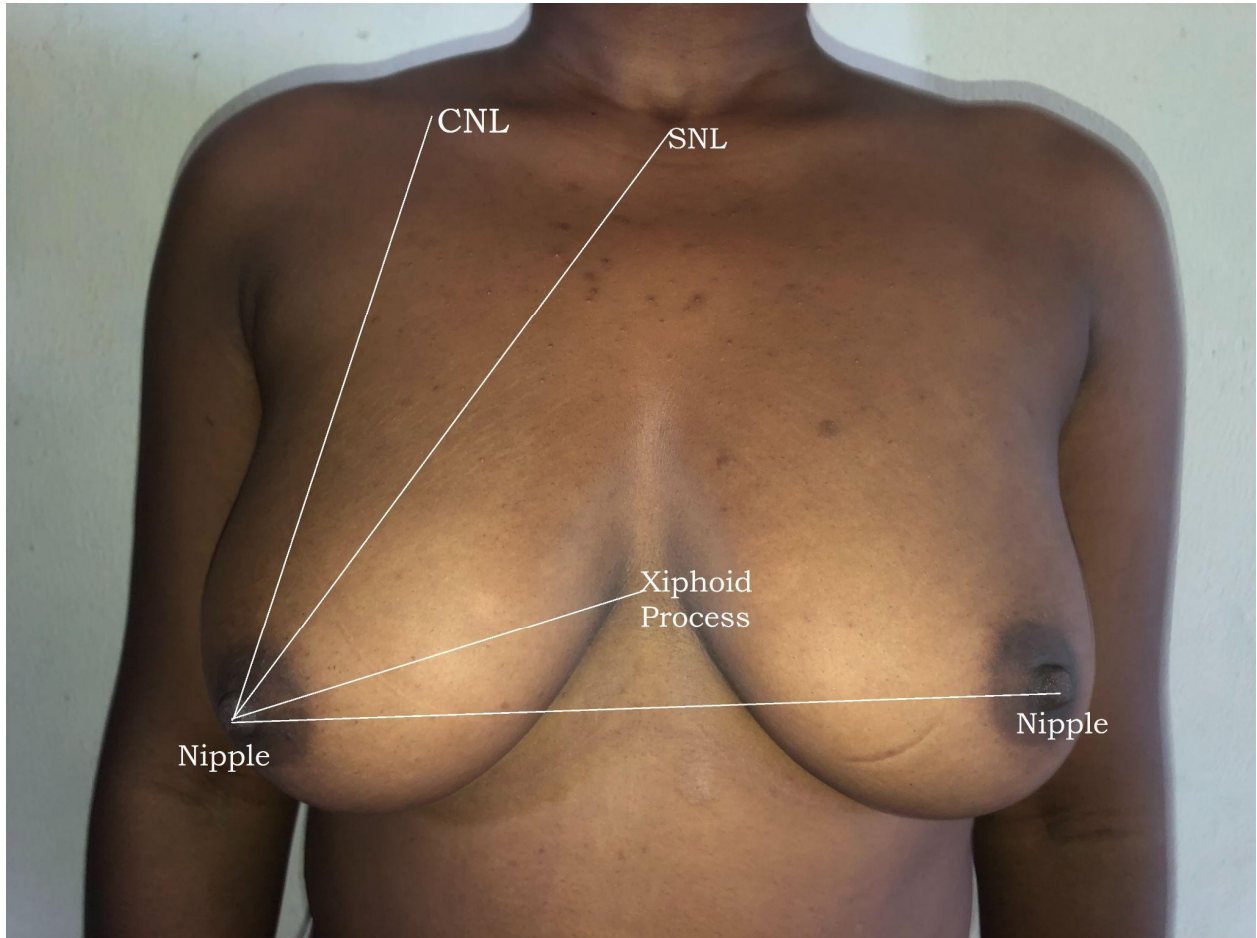
- IV. Nipple–nipple length (NNL): From the center of one nipple to the other using a ruler in the horizontal axis.
- V. Nipple to Inframammary fold to distance (NIMF): This was taken vertically with a ruler from the inframammary fold to the nipple of each mammary gland; both left and right.
- VI. Midclavicular line to nipple length (CNL): This was taken vertically with a ruler from the middle of the clavicle to the nipple on each side.
- VII. Lateral radius (LR): This was taken vertically with a ruler from the nipple to the anterior axillary line (AAL) on each side.
- VIII. Medial radius (MR): This was taken vertically with a ruler from the nipple to xiphoid process of the mid sternal line (MSL) on each side.
- IX. Mammary projection (MP): Vertical distance from the chest wall to the highest point on the mammary gland mold using two rulers.
- X. Nipple projection (NP): Vertical height of the nipple from the mammary gland.
- XI. Mammary gland diameter (BD): The widest part of mammary gland was taken with a measuring tape circumferentially around the thorax at the level of the nipple.
- XII. Chest circumference under the Inframammary Fold (CCF): This was taken firmly with a measuring tape circumferentially around the thorax at the level of the inframammary fold.
- XIII. Chest circumference under the axilla (CCA): This was taken firmly with a measuring tape circumferentially around the upper part of the mammary gland at the level of the axilla.
- XIV. Mammary volume (MV) was calculated using the formula defined by Qiao *et al.*, [15] by inserting the measured MR, LR, and NIMF values for each subject:

$$MV = 1/3 \times 3.14 \times MP^2 \times (MR + LR + NIFL - MP).$$

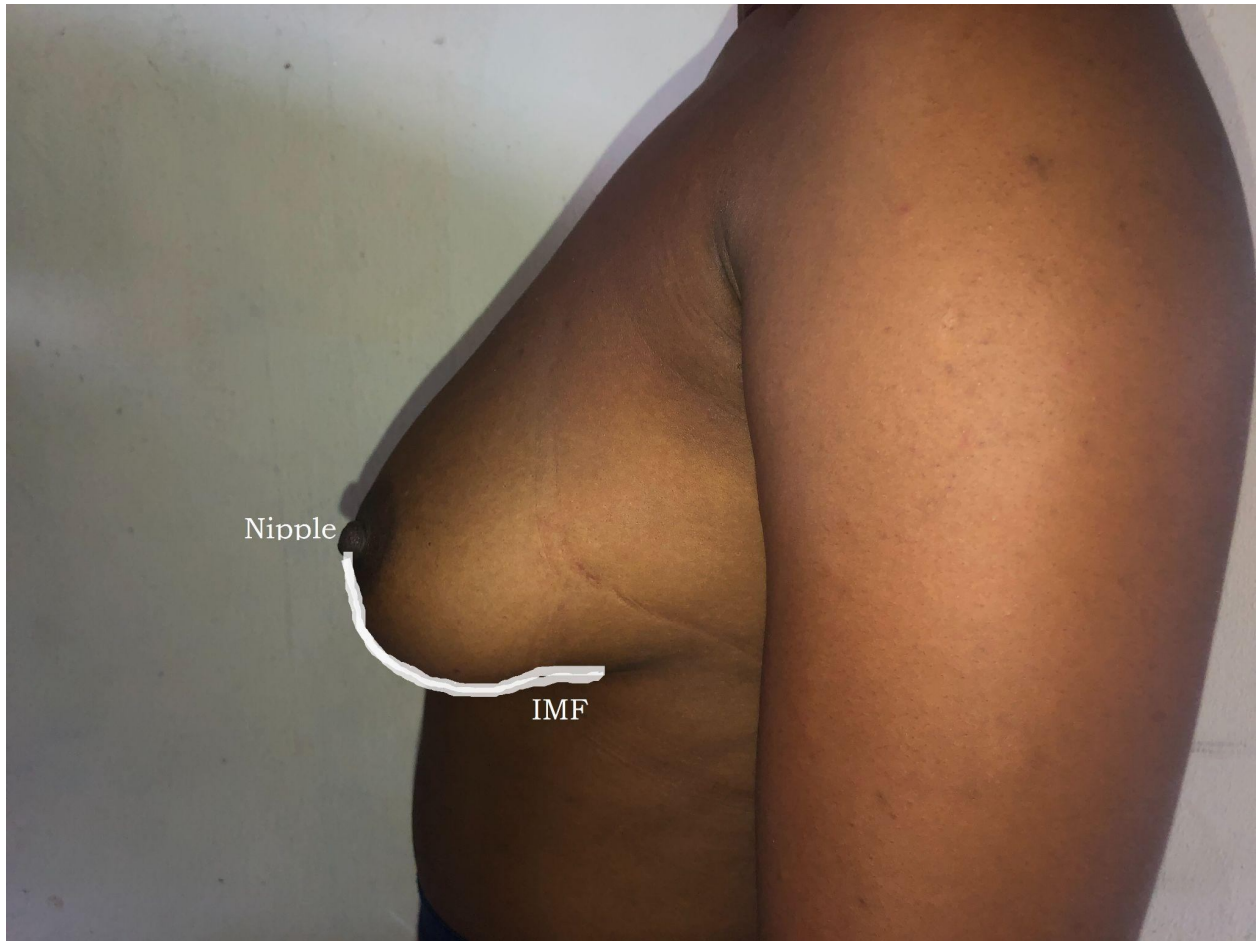The mammary volume was in milliliters (ml)

### **Data Analysis**

Data analysis was done using statistical Package for the Social Sciences (SPSS) version 2020. Result was expressed as mean  $\pm$  standard deviation (SD) while analysis of variance (ANOVA) and independent t-test was used to compare differences in the mean breast anthropometric parameters between the left and right mammary glands. Finally, Pearson's correlation was used to determine the association or relationship between the left and right parameters of each breast. A  $P < 0.05$  was considered statistically significant.

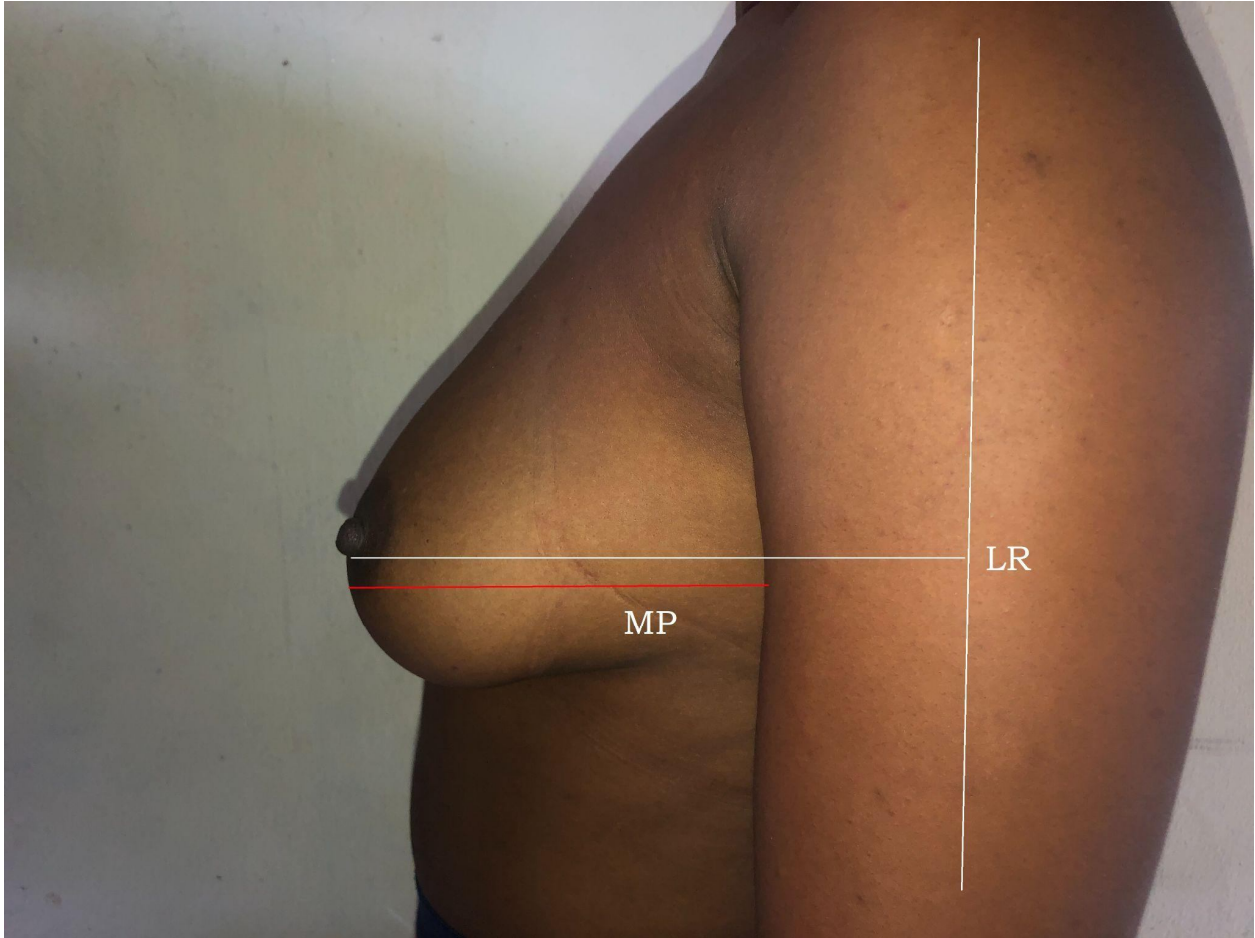


**Figure 1:** A 23-year-old subject of Grade C or 2 (moderate ptosis) / Archetype with the attribute of being side set showing some of the breast parameters measured. *CNL* midclavicular to nipple length. *SNL* Suprasternal notch to nipple distance

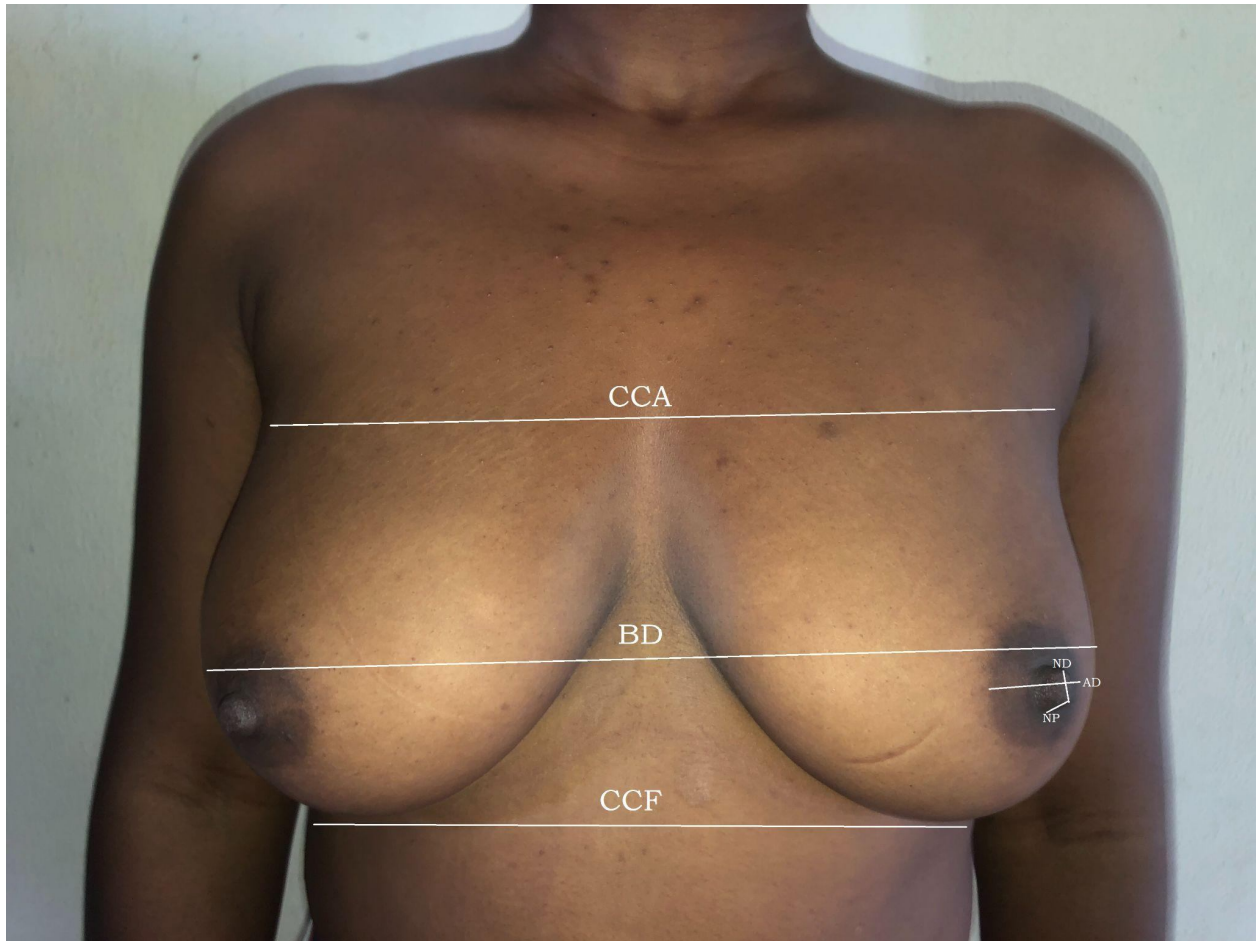


**Figure 2:** A 23-year-old subject with Nipple inframammary fold length (NIMF) taken.

UNDER REVIEW



**Figure 3:** A 23-year-old subject showing the lateral radius (*LR*) and mammary projection (*MP*) respectively.



**Figure 4:** A 23-year-old subject of some of the breast parameters measured: **CCA** chest circumference under the axilla; **BD** Breast Diameter; **CCF** Chest circumference under the inframammary fold; **ND** Nipple diameter ; **AD** Areola diameter; **NP** Nipple projection.

### 3.5 LIMITATIONS OF THE STUDY

Most female students approached for this study were unwilling to participate due to the nature of the study and this greatly affected the sample size.

**Table 1: Descriptive statistics of Single mammary gland Parameters**

Measurements	N	Min	Max	Mean (cm)	SE	SD
Nipple/nipple distance	66	15.0	30.0	22.20	0.52	4.19
CCA	66	63.0	109.0	78.27	1.59	12.93
mammary gland diameter	66	64.5	93.6	83.20	0.85	6.89
CCF	66	60.54	105.38	82.25	1.28	10.40

Values are given as **Mean**  $\pm$  **SE** for each group where **SE** is the Standard Error of mean; **Min** = *Minimum*, **Max** = *Maximum*, **SD** = *Standard Deviation*, **CCA** chest circumference over axilla; **CCF** chest circumference under the inframammary fold

**Table 2: Age range statistical analysis of single mammary gland Parameters using one way analysis of variance.**

MEASUREMENT (cm)	AGE RANGE (YRS)			P value	Inference
	16-20	21-25	26-30		
Nipple/nipple distance	22.11 $\pm$ 0.89	22.61 $\pm$ 0.67	20.88 $\pm$ 1.58	0.58	N/S
CCA	80.11 $\pm$ 2.62	76.06 $\pm$ 2.08	80.63 $\pm$ 5.55	0.43	N/S
mammary gland diameter	83.78 $\pm$ 1.32	82.06 $\pm$ 1.29	85.68 $\pm$ 1.94	0.36	N/S
CCF	83.74 $\pm$ 1.94	80.48 $\pm$ 1.85	84.06 $\pm$ 4.27	0.44	N/S

Values are given as **Mean**  $\pm$  **SE** for each group where **SE** is the Standard Error. **P**: statistical level of significance was determined by one-way Analysis of Variance (ANOVA). **P**<0.05 means significant; *N/S* not significant, **CCA** chest circumference over axilla; **CCF** chest circumference under the inframammary fold

**Table 3: Comparison of right and left mammary gland parameters of females using paired sample t-test (N=66)**

Measurements (cm)	mamma ry gland	MEAN±SE	t-Test	P value	INFERENCE
Areolar diameter	Right	4.17±0.14	-1.85	0.07	Not significant
	Left	4.33±0.14			
Nipple diameter	Right	0.62±0.21	-0.29	0.77	Not significant
	Left	0.63±0.21			
Nipple projection	Right	0.29±0.02	-5.01	0.00	Significant
	Left	0.32±0.02			
SNL distance	Right	22.64±0.36	-0.14	0.89	Not significant
	Left	22.66±0.37			
NIFL distance	Right	10.43±0.21	-0.69	0.49	Not significant
	Left	10.50±0.22			
CNL distance	Right	21.41±0.41	-0.14	0.89	Not significant
	Left	21.43±0.40			
Medial radius	Right	13.19±0.20	1.38	0.17	Not significant
	Left	12.97±0.24			
Lateral radius	Right	16.91±0.26	-1.63	0.11	Not significant
	Left	17.17±0.25			
Mammary projection	Right	10.62±0.29	2.71	0.01	Significant
	Left	10.30±0.26			

*N*=number of subjects, *t*= t-test, **P**<0.05 means significant. *SE*=Standard Error (**N**=sample size).

*SNL* sternal notch nipple length; *NIMF* nipple infra mammary fold length; *CNL* midclavicular point nipple length;

**Table 4: Relationship between right and left mammary gland parameters of females using Pearson Correlation ®**

Measurements (cm)	mamma ry gland	MEAN±SE	R	P value	INFERENCE
Areolar diameter	Right	4.17±0.14	0.82	0.00	Significant
	Left	4.33±0.14			
Nipple diameter	Right	0.62±0.21	0.86	0.00	Significant
	Left	0.63±0.21			
Nipple projection	Right	0.29±0.02	0.97	0.00	Significant
	Left	0.32±0.02			
SNL distance	Right	22.64±0.36	0.95	0.00	Significant
	Left	22.66±0.37			
NIFL distance	Right	10.43±0.21	0.89	0.00	Significant
	Left	10.50±0.22			
CNL distance	Right	21.41±0.41	0.96	0.00	Significant
	Left	21.43±0.40			
Medial radius	Right	13.19±0.20	0.77	0.00	Significant
	Left	12.97±0.24			
Lateral radius	Right	16.91±0.26	0.81	0.00	Significant
	Left	17.17±0.25			
Mammary projection	Right	10.62±0.29	0.91	0.00	Significant
	Left	10.30±0.26			

N=number of subjects, R=Pearson correlation or correlation coefficient, P <0.05. *SNL* sternal notch nipple length; *NIFL* nipple infra mammary fold length; *CNL* midclavicular point nipple length;

**Table 5: Age range statistical analysis of right & left mammary gland parameters using one way analysis of variance.**

Mammary gland Parameters		Age Range			P-value	Inference
Measurements (cm)	Position	16-20 (Mean/SD)	21-25 (Mean/SD)	26-30 (Mean/SD)		
Areola Diameter	Right	4.32±0.21	4.08±0.22	4.00±0.42	0.67	Not significant
	Left	4.50±0.22	4.22±0.21	4.15±0.41	0.61	Not significant
Nipple Diameter	Right	0.82±0.34	1.2±0.30	0.95±0.79	0.97	Not significant
	Left	0.8±0.35	1.0±0.30	1.03±0.67	0.92	Not significant
SNL	Right	22.78±0.59	22.26±0.50	23.63±1.21	0.49	Not significant
	Left	22.72±0.62	22.36±0.49	23.61±1.23	0.58	Not significant
NIFL Distance	Right	8.45±0.32	10.46±0.35	11.29±0.37	0.97	Not significant
	Left	8.46±0.32	10.57±0.37	11.39±0.46	0.96	Not significant
CNL Length	Right	21.95±0.72	20.79±0.57	22.00±0.91	0.38	Not significant
	Left	21.94±0.70	20.77±0.56	22.29±0.84	0.30	Not significant
Lateral Radius	Right	16.50±0.36	17.24±0.39	17.00±0.91	0.41	Not significant
	Left	17.13±0.36	17.21±0.36	17.13±0.90	0.99	Not significant
Medial Radius	Right	13.22±0.33	13.05±0.31	13.63±0.39	0.68	Not significant
	Left	13.11±0.38	12.75±0.38	13.38±0.52	0.66	Not significant
MP	Right	10.39±0.49	10.92±0.42	10.25±0.67	0.63	Not significant
	Left	10.16±0.41	10.53±0.39	9.88±0.62	0.67	Not significant
NP	Right	0.28±0.03	0.31±0.03	0.24±0.07	0.44	Not significant
	Left	0.29±0.03	0.34±0.03	0.29±0.05	0.45	Not significant

Values are given as Mean ± SE for each group where *SE* is the Standard Error. **P**: statistical level of significance was determined by One-Way Analysis of Variance (ANOVA). **P**<0.05 means

significant. *SNL* sternal notch nipple length; *NIFL* nipple infra mammary fold length; *CNL* midclavicular point nipple length; *MP* mammary projection; *NP* nipple projection;

**Table 6: Comparison of the mean mammary gland parameters of present study with previous studies outside Africa.**

Parameters	Workers	Country	Year	No of subjects studied (n)	Mean	SD
<b>Areolar diameter</b>	Al-Qattan <i>et.al.</i> ,	Saudi	2019	44	4.5	1.4
	Qiao <i>et.al.</i> ,	China	1997	125	3.32	0.4
	Present Study	Nigeria	2023	66	4.25	0.10
<b>Nipple diameter</b>	Westreich <i>et.al.</i> ,	Israel	1997	50	0.35	0.6
	Present study	Nigeria	2023	66	0.62	0.18
<b>Nipple Projection</b>	Demiroz <i>et.al.</i> ,	Turkey	2020	100	0.39	—
	Qiao <i>et.al.</i> ,	China	1997	125	0.46	0.16
	Westreich <i>et.al.</i> ,	Israel	1997	50	0.36	0.8
	Present study	Nigeria	2023	66	0.30	0.01
<b>SNL distance</b>	Demiroz <i>et.al.</i> ,	Turkey	2020	100	19.85	—
	Al-Qattan <i>et. al.</i> ,	Saudi	2019	44	19.8	2.5
	Qiao <i>et.al.</i> ,	China	1997	125	19.05	0.107
	Present study	Nigeria	2023	66	22.65	0.25
<b>NNL distance</b>	Demiroz <i>et.al.</i> ,	Turkey	2020	100	19.05	—
	Al-Qattan <i>et.al.</i> ,	Saudi	2019	44	20.3	2.3
	Westreich <i>et.al.</i> ,	Israel	1997	50	19.3	1.7
	Present study	Nigeria	2023	66	22.2	4.19
<b>NIFL distance</b>	Demiroz <i>et.al.</i> ,	Turkey	2020	100	7.35	—
	Al-Qattan <i>et.al.</i> ,	Saudi	2019	44	7.7	1.6
	Westreich <i>et.al.</i> ,	Israel	1997	50	5.1	1.0
	Present study	Nigeria	2023	66	10.45	0.15
<b>CNL distance</b>	Demiroz <i>et.al.</i> ,	Turkey	2020	100	19.25	—

	Qiao <i>et.al.</i> ,	China	1997	125	19.26	0.09
	Westreich <i>et.al.</i> ,	Israel	1997	50	18.8	1.5
	Present study	Nigeria	2023	66	21.42	0.29
<b>Medial Radius</b>	Qiao <i>et.al.</i> ,	China	1997	44	10.03	0.08
	Present Study	Nigeria	2023	66	13.08	0.16
<b>Lateral Radius</b>	Demiroz <i>et.al.</i> ,	Turkey	2020	100	10.05	—
	Qiao <i>et.al.</i> ,	China	1997	44	9.6	0.1
	Present study	Nigeria	2023	66	17.04	0.18
<b>Mammary projection</b>	Demiroz <i>et.al.</i> ,	Turkey	2020	100	10.95	—
	Qiao <i>et.al.</i> ,	China	1997	44	3.6	0.06
	Present study	Nigeria	2023	66	10.46	0.19
<b>CCA</b>	Qiao <i>et.al.</i> ,	China	1997	125	79.6	0.4
	Present study	Nigeria	2023	66	78.27	12.93
<b>BD</b>	Qiao <i>et.al.</i>	China	1997	44	81.4	0.489
	Present study	Nigeria	2023	66	83.20	6.89
<b>CCF</b>	Demiroz <i>et.al.</i> ,	Turkey	2020	100	77.9	—
	Westreich <i>et.al.</i> ,	Israel	1997	50	71.9	4.5
	Present study	Nigeria	2023	66	82.25	10.40

**AD** areolar diameter; **BD** mammary gland diameter; **MV** mammary volume; **SNL** sternal notch nipple length; **NIFL** nipple infra mammary fold length; **CNL** midclavicular point nipple length; **MP** mammary projection; **NP** nipple projection; **MR** medial radius; **LR** lateral radius; **NNL** nipple to nipple length; **CCA** chest circumference over axilla; **CCF** chest circumference under the inframammary fold and **ND** nipple diameter.

**Table 7: Comparison of the mean mammary gland parameters in the present study with other Nigerian studies and Ghana.**

Parameters	Workers	Country	Year	Subjects studied (n)	Mean	SD
<b>AD</b>	Archibong et al	Nigeria	2022	370	4.5	1.4
	Isiwele <i>et al.</i> ,	Nigeria	2020	500	3.32	0.4
	Present Study	Nigeria	2023	66	4.25	0.10
<b>ND</b>	Archibong et al	Nigeria	2022	370	3.49	0.6
	Isiwele <i>et al.</i> ,	Nigeria	2020	500	3.9	—
	Present study	Nigeria	2023	66	0.62	0.18
<b>NP</b>	Archibong et al	Nigeria	2022	370	0.28	0.30
	Present study	Nigeria	2023	66	0.30	0.01
<b>SNL distance</b>	Agbenorku et al	Ghana	2010	438	20.64	—
	Archibong et al	Nigeria	2022	370	22.10	3.50
	Isiwele <i>et al.</i> ,	Nigeria	2020	500	21.12	1.99
	Present study	Nigeria	2023	66	22.65	0.25
<b>NNL distance</b>	Archibong et al	Nigeria	2022	370	21.70	3.50
	Isiwele <i>et al.</i> ,	Nigeria	2020	500	21.12	—
	Present study	Nigeria	2023	66	22.2	4.19
<b>NIFL distance</b>	Agbernorku et al	Nigeria	2010	438	9.28	—
	Archibong et al	Nigeria	2022	370	9.90	2.50
	Isiwele <i>et al.</i> ,	Nigeria	2020	500	8.20	—
	Present study	Nigeria	2023	66	10.45	0.15
<b>CNL distance</b>	Archibong et al	Nigeria	2022	370	21.08	3,69
	Isiwele <i>et al.</i> ,	Nigeria	2020	500	—	0.4
	Present Study	Nigeria	2023	66	21.42	0.29

<b>MR</b>	Agbenorku et al	Nigeria	2010	438	10.89	—
	Archibong et al	Nigeria	2022	370	12.87	2.59
	Present study	Nigeria	2023	66	13.08	0.16
<b>LR</b>	Archibong et al	Nigeria	2022	100	13.92	2.60
	Present study	Nigeria	2023	66	17.04	0.18
<b>MP</b>	Archibong et al	Nigeria	2022	370	6.50	1.26
	Present study	Nigeria	2023	66	10.46	0.19
<b>NNL distance</b>	Archibong et al	Nigeria	2022	370	21.70	2.22
	Egiehiokhin et al	Nigeria	2020	500	21.12	—
	Present study	Nigeria	2023	66	22.20	4.19
<b>CCA</b>	Archibong et al	Nigeria	1997	370	83.06	6.35
	Present study	Nigeria	2023	66	78.27	12.93
<b>BD</b>	Archibong et al	Nigeria	2022	370	88.18	8.14
	Egiehiokhin et al	Nigeria	2020	500	73.65	—
	Present study	Nigeria	2023	66	83.20	6.89
<b>CCF</b>	Egiehiokhin et al	Nigeria	2020	500	84.76	—
	Present study	Nigeria	2023	66	82.25	10.40

**AD** areolar diameter **BD** mammary gland diameter; **MV** mammary volume; **SNL** sternal notch nipple length; **NIFL** nipple infra mammary fold length; **CNL** midclavicular point nipple length; **MP** mammary projection; **NP** nipple projection; **MR** medial radius; **LR** lateral radius; **NNL** nipple to nipple length; **CCA** chest circumference over axilla; **CCF** chest circumference under the inframammary fold and **ND** nipple diameter

## DISCUSSION

Measuring the mammary gland can be challenging due to its complex shape and varying sizes. Despite the challenges in accurately measuring the mammary gland, the information gathered from morphometric studies can help researchers and healthcare providers diagnose and treat mammary gland diseases and disorders. With the increasing demand for aesthetic and

reconstructive mammary gland surgeries, a study of this nature is relevant, as there have been very few anthropometric studies performed on the mammary gland among the African blacks.

This study evaluated the mean mammary gland parameters in a sample of 66 young nulliparous female students between ages 16 and 30 years of the University of Port-Harcourt, Nigeria who met the inclusion criteria. This study has shown that there is some degree of asymmetry between the left and right mammary glands of the female subjects with the left being slightly bigger. This asymmetry between paired body parts like the breast is quite common and normal. The mean right and left breast volumes in this study were 402.54 mL and 449.76 mL respectively. This work revealed the left breast to be bigger than the right in most of the subjects. This is in conformity with the findings from breast anthropometric studies in Israel [14], United states of America [20], Ghana [16] and Nigeria [17] who all reported the left breast to be slightly bigger than the right. However, findings in the studies from Turkey [4, 21] were at variance to this present study. The average breast volume from this work is therefore 426.15 mL which is higher than the 200mL breast volume that was reported in the United States of America for African women[22].

The mean age recorded in this study was 19.30 years which is two years above the mean age of 17 years (16-22 years) of the study done by Ghanaian researchers [16] on 438 young females. Age is vital when carrying out morphometric breast analysis because the breast is a very dynamic organ of the human body, continuously changing in size and position during the life of a person. Like the study in Ghana, ours studied nulliparous breasts, bearing in mind that every woman coming for a breast aesthetic procedure would expect her breast to be more youthful looking and not sagging or with minimum ptosis [17].

Two out of the nine breast parameters measured showed statistical significant differences on the mean mammary projection value of the right been higher and on the mean nipple projection which was significantly higher on the left. The mean values of the remaining seven parameters (areola diameter -AD, nipple diameter-ND, Suprasternal notch to nipple length distance SNL, Nipple to inframammary fold length -NIMF distance, Mid-clavicular to nipple length distance- CNL distance, medial radius - MR and lateral radius - LR), although not significant, all except the medial radial distance displayed higher mean values on the left mammary gland. These

findings tend to agree with studies done in Ghana [16], Lagos, Nigeria [17] and Israel [14], but were at variance with the study in Turkey [4] which had the parameters of the right breast significantly higher. The concurrence of our study with that from Lagos- Nigeria and Ghana may be due to the fact that both studies were of the West African region and as such the females from these studies displayed similar morphometric features as Africans. The none significant difference in the areolar diameter and nipple diameter of the right and left breast in this study was in agreement with the findings in studies in Nigeria [16], Turkey [4] and Israel [14].

There was a positive correlation of all the nine breast parameters between the left and right breast (table 3): This was similar to the findings in Turkey [4,21], Israel [14], China [15] and in Lagos-Nigeria [17].

On the age range analysis of 16 -20years, 21-25years and 26-30years of the right and left nine breast parameters (table 4) and the four single breast parameters (Nipple-nipple length- NNL, mammary gland diameter –BD, Chest circumference under the Inframammary Fold - CCF and Chest circumference under the axilla - CCA ) displayed in table 2, none showed significant difference. The mean values of NNL (22.20cm), BD (83.20cm) , CCF (82.25cm) and CCA (78.27cm) in this present study varied from those in recorded in previous studies. The mean NNL from this study of 22.20cm was highest when compared to previous studies: Lagos-Nigeria - 21.70cm [17], Ghana - 21.78 cm[16], Saudi-Arabia - 20.3 cm [3], Korea -18.5 cm [25],Turkey -19.9 cm [4] and Israel -19.33cm[14].

The NIMF mean value was longer in this study (10.45cm) compared to Ghana – 9.2cm [16], Turkey – 6.64cm [23], Belgium – 6.94cm [18] and South Africa – 6.74cm [24]. A close analysis of these values suggests the NIFM in black African females to be longer compared to that of the white females. Despite the fact that the study by Vandeput *et al.*, in Belgium [18] did not exclude non-nulliparous subjects and also that the highest age was up to 60 years, the NIFM was still less than what was obtained from our study. Furthermore, comparing the study of the Ghanaian females with ours, a lower NIFM mean value was expected because the age groups studied were younger than the age groups in this present study and it was expected that NIFM would increase with age, however this was not the case.

The mean SNL value from this study was 22.65cm which was the highest when compared to previous studies: Ghana-20.64cm [16], Lagos, Nigeria – 22.10cm [17], Saudi-Arabia – 19.8cm [3] China – 19.05cm [15].

The mean areolar diameter (AD) of 4.25cm from this study was lower than that in Saudi Arabian females (4.5cm) [3] but higher than that in Chinese females (3.32cm)[15].

The nipple diameter (ND) of 0.62cm from this study was higher than that of Israeli females (0.35cm)[14]; while the nipple projection (NP) of 0.30cm from this study was the least when compared to Israel (0.36cm) [14], Turkey (0.39cm) [19, 23] and China (0.46cm) [15].

The medial radius (MR) distance which is the average distance from the nipple to the midline in the xiphoid area was 13.08cm from our study and this is still higher than previous studies in Nigeria by Archibong *et. al.*, (12.87cm) [17 ]; Ghana by Agbenorku *et. a.,l* (11.0cm) [16] as well as in Turkish females [19].

The breast shape based on the classification study done by Johnson [26], classified the breast into thirteen (13) shapes namely; archetype, round, asymmetrical, athletic, bell shape, close set, conical, east-west, relaxed, side set, slender and teardrop. Based on this classification by visual appearance, this present study revealed 25(38%) subjects to have slender breast shape, 23(34%) subjects had archetype breast shape, 11(17%) subjects had both side set and teardrop breast shapes, while the remaining 7(11%) subjects had a bell breast shape. furthermore, in another classification according to Avsar *et al.*,[4] who studied the breast of 385 Turkish females, they classified or categorized the female breast shape from the Ideal breast shape (Grade A or Grade zero) to Pseudoptosis shape (Grade E or Grade 4). Thus, Grade A or Grade 0 is same as the Ideal shape; Grade B or Grade 1 is same as mild ptosis shape; Grade C or Grade 2 same as moderate ptosis shape; Grade D or Grade 3 same as severe ptosis shape and Grade E or Grade 4 same pseudoptosis shape. Based on this classification, the shapes of the 66 subjects investigated in this present study revealed 23(34.8%) subjects to fall under Grade D or 3 which is severe ptosis shape, 17(25.75%) subjects under Grade C or 2 which is moderate ptosis shape, 13 subjects (20.2%) fell into Grade A or zero which is the ideal breast shape, 7(11.5%) subjects had mild ptosis shape - Grade B or 1 and the remaining 5(7.8%) subjects had pseudoptosis shape

which is Grade E or 4. Based on these two classifications, the major breast shapes are the slender and severe ptosis breast shapes.

## CONCLUSION

This study on the morphometry of the female breast using students of the University of Port Harcourt revealed the slender and severe ptosis shapes as the major breast shapes while the least were the bell and the pseudoptosis breast shapes based on two classifications. The mammary size volume showed the left breast to be significantly bigger than the right, while of all the analyzed breast parameters, the nipple projection (left) and mammary projection (right) displayed significant differences in this study with all the right and left measured breast parameters displaying a positive correlation. The values from this study can be used as a guide by plastic surgeons providing services to females of African descent requiring aesthetic and reconstructive breast surgeries as well as in physical anthropological studies and racial identification.

## REFERENCES

1. Chaurasia, B. D. (2017). Human Anatomy Upper Limb and Thorax Volume 1: Regional and Applied Dissection and Clinical Anatomy (6th ed.). CBS Publishers & Distributors.
2. Isiwele E, Nnabuko RE, Ogbonnaya IS (2020). Morphometric analysis and key dimensions of the female breast: a baseline study of 500 nulliparous Nigerian females. Nigerian J Plast Surg;16:27-31
3. Al-Qattan M.M, Aldakhil S.S, Al-Hassan T.S (2019). Anthropometric Breast Measurement: Analysis of the Average Breast in Young Nulliparous Saudi Female Population. Plast Reconstr Surg Glob Open 7:e2326. DOI: 10.1097/GOX.0000000000002326.
4. Avşar D.K., Aygıt A.C., Benlier E (2010). Anthropometric breast measurement: a study of 385 Turkish female students. Aesthet Surg J. 30:44–50.

5. Tortora G. J., & Derrickson, B (2017). Principles of anatomy and physiology. John Wiley & Sons.
6. Moore K. L., & Dalley, A. F (2018). Clinically oriented anatomy. Wolters Kluwer, 8th Edition.
7. Loukas M., Hullett, J., Louis, R. G., & Kapos T. (2011). Breast symmetry: a review. The Breast Journal, 17(6), 569-581.
8. Moore K.L & Dalley A.F (2006). Clinically oriented anatomy, 5th edition, p. 105 – 111.
9. Rohlf F. J., & Marcus L. F. (1993). A revolution morphometrics. Trends in Ecology & Evolution, 8(4), 129-132.
10. Quieregatto P. R., Bernardo Hochman, Ferrara S.F., Fabianne Furtado, Liebano R. E., Miguel Sabino Neto, Ferreira L. M (2014). Anthropometry of the Breast Region: How to Measure? Aesthetic Plastic Surgery, 38, 344-349. DOI: 10.1007/s00266-014-0291-9.
11. Bouman F.G (1970). Volumetric measurement of the human breast and breast tissue before and during mammoplasty. Br J Plast Surg ; 23:263–264.
12. Nechala P., Mahoney J., Farkas L (1999). Digital two-dimensional photogrammetry: a comparison of the three techniques of obtaining digital photographs. Plast Reconstr Surg 103(7): 1819–1825 2.
13. Hochman B, Castilho HT, Ferreira LM (2002). Padronizac,ão fotogr´fica e morfome´trica na fotogrametria computadorizada do nariz. Acta Cir Bras 17(4):258–266.
14. Westreich M. (1997). Anthropomorphic breast measurement: protocol and results in 50 women with aesthetically perfect breasts and clinical application. Plast Reconstr Surg. 100(2):468–479.
15. Qiao Q., Zhou G., & Ling, Y (1997). Breast volume measurement in young Chinese women and clinical applications. Aesthetic plastic surgery, 21(4), 266-271. doi: 10.1007/s002669900164
16. Agbenorku M., Iddi A., Amevor E., Sefenu R., Osei D (2011). Measurements of breasts of young west African females: A guideline in anatomical landmarks for adolescent breast surgery. Aesthetic Plast Surg 35:49-54.

17. Archibong O.R., Abikoye F.O., Osisanya T.O (2021). Anthropometric breast measurements of nulliparous women in Lagos Nigeria. *J West Afr Coll Surg* 11:1-6.
18. Vandeput J.J., Nelissen M (2002). Considerations on anthropometric measurements of the female breast. *Aesth Plast Surg* 26:348-55.
19. Dilek K.A., Ahmet C.A., Erol B., Hu'samettin T., Oguz T (2010). Anthropometric breast measurement: a study of 385 Turkish female students. *Aesthet Surg J* 30(1):44–50.
20. Losken A., Fishman I., Denson D.D., Moyer H.R., Carlson G.W (2005). An objective evaluation of breast symmetry and shape differences using 3-dimensional images. *Ann Plast Surg* 55:571-5.
21. Demiroz, A., Turkmen, A., Yıldız, T. F., & Daghan, B. (2020). Anthropometric breast measurements of young women with no history of pregnancy or surgery in Turkey. *Journal of Plastic Surgery and Hand Surgey*. <https://doi.org/10.1080/2000656X.2020.1817>.
22. Anderson J.D., Chandler S.C., Mason M.A., Khan C.B., Lindsay J.E., *et al.*, (2013). Scientific analysis reveals major differences in breast size of women in different countries. *J Female Health Sci; JFH.TD.13.098:268-92*
23. Smith D.J Jr, Palin W.E Jr, Katch V.L, *et al.*, (1986). Breast volume and anthropomorphic measurements: normal values. *Plast Reconstr Surg*. 78(3):331–335.
24. Penn J (1954). Breast reduction. *Br J Plast Surg*. 7:357–371.
25. Kim, M., & Kim, M. J. (2014). The affecting factors of breast anthropometry in Korean women. *Breastfeeding Medicine*, 9, 73-78. doi: 10.1089/bfm.2013.0097.
26. Johnson M.Z (2019). What Are the Most Common Breast Shapes?. Healthline Online Publication. DOI: <https://www.healthline.com/health/breast-shapes#shapes>.
27. Kim, M. S., Sbalchiero, J. C., Reece, G. P., Miller, M. J., Elisabeth, K., & Markey, M. K. (2008). Assessment of breast aesthetics. *Plastic and Reconstructive Surgery*, 121, 186e-194e.