

## **Case study**

### **Intracranial hemorrhage in pregnancy: case report and review of literature**

#### **Abstract:**

Intracranial hemorrhage during pregnancy is a rare but life-threatening event during pregnancy. There is a major risk of maternal and fetal death and morbidity. The risk of hemorrhage increases during the third trimester and is greatest during labor and postpartum.

We report a dramatic case of a 33-year-old primigravida 38 weeks by gestation complicated by eclampsia and intracranial hemorrhage with cerebral mass effect . She was managed by an emergency cesarean section and craniotomy but without desirable results , we were not able to save the patient ,she died on day 2. the publication of such cases could provide another insight into pre-eclampsia and its life-threatening complications.

Keywords: Intracranial hemorrhage, Eclampsia, Intraparenchymal hemorrhage

#### **Introduction:**

Cerebrovascular complications of pregnancy are caused by physiological cerebrovascular changes and/or preexisting disease, the intracranial hemorrhage is the deadliest complication. The risk of haemorrhage increases during the third trimester and is greatest during parturition and the puerperium(1). Incidence of pregnancy-related stroke is approximately 34 strokes per 100,000 deliveries; however, incidence is reported to vary by ethnicity(2).

#### **Case presentation:**

We report the history of a 33-year-old young woman, primigravidae at 38 weeks of amenorrhea, admitted to hospital in a state of loss of consciousness. according to her

family, she complained of severe headaches, she has no notable medical or surgical history or trauma. Her general examination found blood pressure at 190/110 mm Hg, pulse at 92/min, respiratory rate at 19/min and SpO2 at 96%.

The obstetrical examination finds a uterine height of 31 cm, regular fetal heart sounds at 150 bpm. The biological assessment including a complete blood count, kidney and liver function, uric acid assay and normal lactate dehydrogenase (LDH). The electrocardiogram (ECG) were normal.

A treatment with intravenous nicardipine and magnesium sulphate was started.

After stabilization, an emergency caesarean section was indicated given the unfavorable cervical condition giving birth to a newborn in good health the patient was transferred to intensive care for altered consciousness, an injected brain scan (Fig. 1) showed a Left fronto-parietal intraparenchymal hematoma exerting a mass effect on the adjacent parenchyma, the midline as well as the homolateral lateral ventricle with subfalcine herniation

and ventricular flooding. It is associated with cerebral edema around. an emergency craniotomy with decompression was performed, but unfortunately, the prognosis was poor, the patient dies on the second day postpartum.

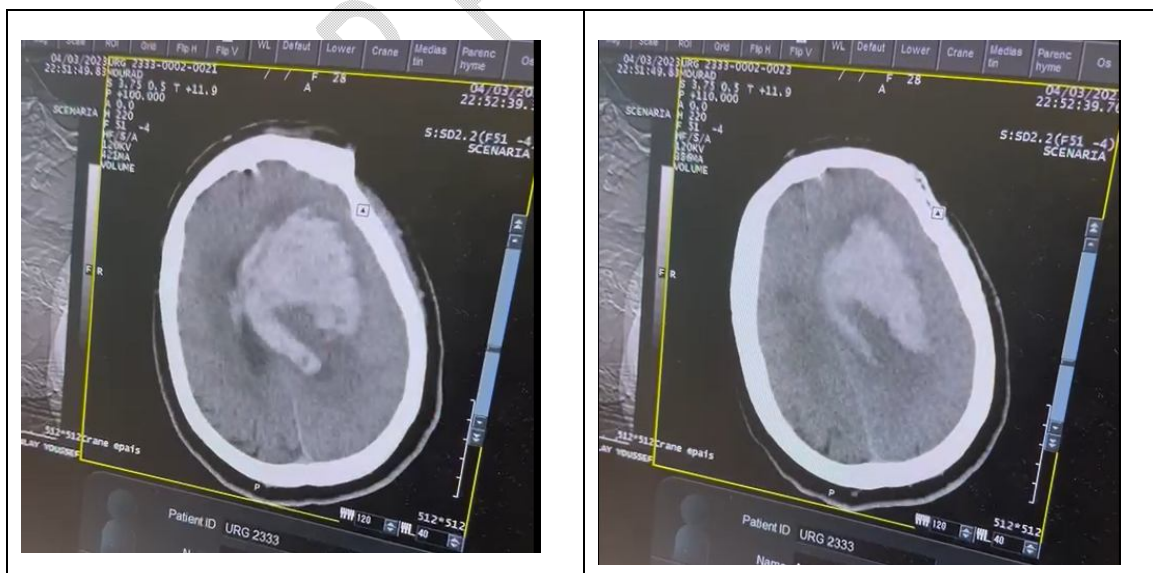


Figure 1: Brain scan image

## Discussion:

There are differences in the types of Intracranial hemorrhage:

a) Extradural hemorrhage due to injury to the middle meningeal artery secondary to traumatic head injury.

b) Subdural hemorrhage: a hemorrhage that is below the dura mater and is a result of head trauma severe injury, has a poor prognosis(4,3). Treatment is the same as for non-pregnant women.

The first case of subarachnoid hemorrhage in pregnancy was reported in 1899. This event in pregnancy occurs in 0.01 to 0.03% and its occurrence is more common during pregnancy (90%), during childbirth (2%) and 8% in the puerperium. (4).

In 1/3 of the cases present an alteration of consciousness with a coma, while those who present a normal consciousness present severe headaches associated with vomiting(4). A neurological deficit may be present(4).

Intracranial hemorrhage occurs in 6 per 100,000 deliveries and causes approximately 12% of maternal deaths(2). Postpartum, advanced maternal age, obesity, chronic hypertension, preeclampsia gestational hypertension are the most common risk factors, thus preeclamptic patients have twice the risk of stroke and four times the risk of high blood pressure later in life(2).

Patients with Diabetes, migraine with aura, heart disease, atrial fibrillation, depression and emotional stress, Coagulopathy, Tobacco abuse are more likely to be exposed to the risk of stroke(4).

Pregnancy and labour are hyperdynamic states. The Blood volume increases in early pregnancy and plateaus at 32 weeks, it is increased by 50% above the nonpregnant state by the end of pregnancy, plasma volume increases by 6% in the first trimester and by 29% at the end of the second trimester, and 48% in the third trimester(7).

The Cardiac output increases by 30-50% in the first 24 weeks of pregnancy, systemic vascular tone falls and blood pressure decreases(7). During the first stage of labour, cardiac output increases by 50%, the mean arterial pressure increases up to 20% during uterine contractions. By 24 h after delivery, all haemodynamic variables are returned to the prelabour baseline(7).

Pregnancy increases the likelihood of cerebral infarction to about 13 times the rate expected outside of pregnancy(3).

Due to significant decrease in blood volume, hemodynamic and hormonal changes, postpartum is associated with a higher risk of intracerebral hemorrhage and the most common clinical manifestations are loss of consciousness, collapse, vomiting, headaches, convulsions, respiratory discomfort(7).

Arteriovenous malformation and aneurysms are the most common causes with 41 % of cases(3). Arteriovenous malformation is the chief cause of intracerebral haemorrhage in pregnancy with a Prevalence of 15-18 per 100,000. The Maternal mortality rate after AVM Arteriovenous malformation haemorrhage is 28% (3). And pregnancy is probably not a significant risk factor. The risk of bleeding from an unruptured arteriovenous malformation is 3.5% vs. 3.1% in non-pregnant women(3).

The most important risk factors for cerebral venous thrombosis are: Pregnancy and in particular postpartum, protein C or S deficiency. Infections, caesarean section also expose to thrombosis(5). The most important risk factors for cerebral venous thrombosis are pregnancy and postpartum, protein C or S deficiency. infections, caesarean section also expose to thrombosis(5). Anticoagulants are the main treatment with or without cerebral hemorrhage and are generally safe after 24 hours postpartum(6).

The use of low molecular weight heparin and warfarin are not contraindicated during breast-feeding(6).

Surgical treatment of large hematomas is sometimes mandatory and the prevention consists of ensuring normal hydration.

Moyamoya's disease is another cause, it is a rare pathology that causes spontaneous occlusion of the cerebral arteries, particularly at the level of the polygon of Willis(6).

The overall goal in the management during pregnancy is to minimize the risk of re-bleeding(6).

Angiography including MRI, CT angiography are recommended for decision-making.

Pregnancy is not a contraindication to these examinations or to endovascular treatment. The overall goal in the management during pregnancy is to minimize the risk of re-bleeding(11).

Angiography including MRI, CT angiography are recommended for decision-making.

Pregnancy is not a contraindication to these examinations or to endovascular treatment and the overall goal in the management during pregnancy is to minimize the risk of re-bleeding (11). Angiography including MRI, CT angiography are recommended for decision-making(11).

Aneurysmal rupture is a therapeutic emergency whatever the pregnancy term, The choice of coils or clip is depending on condition. The target bloodpressure is less than 140/90 mmHg(11).

If the fetus is viable, cesarean section will be discussed with a multidisciplinary team, whereas if it is non-viable, maternal safety takes precedence. by the way the caesarean avoids the maneuvers of Valsalva and the peaks of hypertension which can aggravate the patient's condition(6,).

Conclusion:

*because of the gravity, the mortality and the therapeutic difficulties, prevention is essential, recognize and optimally treat hypertension , Diagnose preeclampsia and establish seizure prophylaxis , recognize and appropriately treat coagulopathy*

*Screening for warning neurological signs , immediate evaluation by neurologist And Imaging are primordial.*

References:

- 1- Razmara A, Bakhadirov K, Batra A, Feske SK. Cerebrovascular complications of pregnancy and the postpartum period. *Curr Cardiol Rep.* 2014;16(10):532
- 2- Bushnell C, McCullough LD, Awad IA, Chireau MV, Fedder WN, Furie KL, Howard VJ, Lichtman JH, Lisabeth LD, Piña IL, Reeves MJ, Rexrode KM, Saposnik G, Singh V, Towfighi A, Vaccarino V, Walters MR; American Heart Association Stroke Council; Council on Cardiovascular and Stroke Nursing; Council on Clinical

Cardiology; Council on Epidemiology and Prevention; Council for High Blood Pressure Research. Stroke. 2014 May;45(5):1545-88. doi: 10.1161/01.str.0000442009.06663.48. Epub 2014 Feb 6.

- 3- Jennifer R. Meeks, MS<sup>1</sup>; Arvind B. Bambhroliya, MBBS, MS, MPH<sup>1</sup>; Katie M. Alex, BS<sup>2</sup>; et al ; Association of Primary Intracerebral Hemorrhage With Pregnancy and the Postpartum Period, *JAMA Netw Open*. 2020;3(4):e202769. doi:10.1001/jamanetworkopen.2020.2769
- 4- Jun C. Takahashi, MD, PhD , Koji Iihara, MD, PhD .Akira Ishii, MD, PhD . Eiju Watanabe, MD, PhD .Tomoaki Ikeda, MD, PhD . Susumu Miyamoto, MD, PhD. Pregnancy-associated Intracranial Hemorrhage: Results of a Survey of Neurosurgical Institutes across Japan. *Journal of Stroke and Cerebrovascular Disease* . VOLUME 23, ISSUE 2, E65-E71, FEBRUARY 2014. <https://doi.org/10.1016/j.jstrokecerebrovasdis.2013.08.017>
- 5- **Marilyn J. Cipolla** , Cerebrovascular Function in Pregnancy and Eclampsia , *American Heart Association Journals* , Hypertension. 2007;50:14–24  
<https://doi.org/10.1161/HYPERTENSIONAHA.106.079442>.
- 6- Mas J-L, Lamy C. Stroke in pregnancy and the postpartum period. In: Ginsberg MD, Bogousslavsky J, eds. *Cerebrovascular Disease: Pathophysiology, Diagnosis and Management*. Malden, MA: Blackwell Science; 2004:1684–1697.
- 7- Zunker P, Happe S, Georgiadis AL, Louwen F, Georgiadis D, Ringelstein EB, Holgreve W. Maternal cerebral hemodynamics in pregnancy-related hypertension. A prospective transcranial Doppler study. *Ultrasound Obstet Gynecol*. 2000;16:179–187.
- 8- Donaldson JO. The brain in eclampsia. *Hypertens Pregnancy*. 1994;13:115–133.
- 9- Richards AM, Graham DI, Bullock MR. Clinical pathological study of neurological complications due to hypertensive disorders of pregnancy. *J Neurol Neurosurg Psychiatr*. 1988;51:416–421.
- 10- Schwartz RB, Jones KM, Kalina P, Gajakian RL, Mantello MT, Garada B, Holman BL. Hypertensive encephalopathy: findings on CT, MR-imaging, and SPECT-imaging in 14 cases. *Am J Radiol*. 1992;159:379–383.

11-VII Alebeek ME, de Heus R, Tuladhar AM, de Leeuw FE. Pregnancy and ischemic stroke: a practical guide to management. [Curr Opin Neurol. 2018 Feb;31\(1\):44-51](#)

UNDER PEER REVIEW