

Case report on Central retinal vein occlusion secondary to carotid-cavernous sinus fistula

Abstract

The present case study highlights about Central retinal vein occlusion secondary to carotid-cavernous sinus fistula. Carotid cavernous fistulas are a rare entity occurring as result of head trauma and also spontaneously. A 61 year-old man consulted for acute unilateral visual loss preceded by a five days history of red eye and a bruit of the head. The patient had a history of blunt head trauma with no associated systemic illness. Carotid-cavernous fistulas arise from abnormal connections between the carotid arteries and the cavernous sinus leading arterialized blood to shunt into the venous system leading to venous hypertension.

Keywords: Central retinal vein occlusion, venous hypertension, Carotid-cavernous fistula, hypertension

Introduction

“Carotid-cavernous fistula (CCF) is an abnormal communication between a previously normal carotid artery and the cavernous sinus” [1]. “CCFs may be spontaneous or traumatic, high flow or low flow and direct or indirect” [2]. CCFs can present with varied ophthalmic complications such as conjunctival chemosis, congestion, proptosis, ptosis, ophthalmoplegia and diplopia, orbital pain, bruit and diminution of vision. CRVO complicating a post-traumatic CCF is a rare association reported in very in few cases [3-4-5-6] explained by venous stasis of the superior ophthalmic vein due to high venous pressure.

Case report:

A 61 year-old man consulted for acute unilateral visual loss preceded by a five days history of red eye and a bruit of the head. The patient had a history of blunt head trauma with no associated systemic illness. His best corrected visual acuity was reduced to light perception OS.

On examination, he was found to have mild proptosis and chemosis OS without restriction of ocular motility. We noted a relative afferent papillary defect with pathological bruit on auscultation in the same eye.

Slit lamp evaluation showed diffuse conjunctival hypereamia with episcleral and conjunctival corkscrew vessel tortuosity (figure 1 A). Anterior segment was unremarkable with normal ocular pressure. Fundus ophthalmoscopy was characterized by a constellation of signs consistent with a central retinal vein occlusion (CRVO) including intraretinal hemorrhages, a dilated tortuous retinal venous system in all four quadrants of the fundus with optic nerve head swelling (figure 1 B).

Orbito-cerebral computed tomography scan with contrast revealed enhancement of the superior ophthalmic vein in the arterial phase of injection with an abnormally dilated and tortuous aspect (figure 1 C).

The patient was urgently referred to neuro-interventional radiology department for diagnostic angiography that showed rapid enhancement of the left cavernous sinus and left superior ophthalmic vein characterizing a left carotid-cavernous sinus fistula (CCF) (figure 1 D). Embolization of the CCF was successfully performed in the same procedure. The final visual acuity was 20 /50 at one year of follow up.

Discussion

“Carotid-cavernous fistulas arise from abnormal connections between the carotid arteries and the cavernous sinus leading arterialized blood to shunt into the venous system leading to venous hypertension” [1]. “CCFs may be spontaneous or traumatic, high flow or low flow and direct or indirect” [2]. “A spontaneous rupture of an existing aneurysm or atherosclerotic artery is an uncommon cause of CCF which is called indirect or dural CCF which usually occurs in postmenopausal, hypertensive females. Because of the diverse clinical signs and symptoms with a long list of differentials, CCFs remains undiagnosed in many patients” [5,6]. “Since ocular manifestations are present in the majority of the patients, the ophthalmologists may be the first to encounter these patients” [2-4]. This underlines the importance of the proper ophthalmic evaluation of any clinical condition involves the eyes.

Conclusion

This is a case report of CRVO complicating a post-traumatic CCF by which we highlight clinical and radiological findings of this rare association. We moreover underline importance of the awareness of the ophthalmologists handling the patient as a whole, because ophthalmic conditions may be manifestations of a non ophthalmic underlying undiagnosed disease.

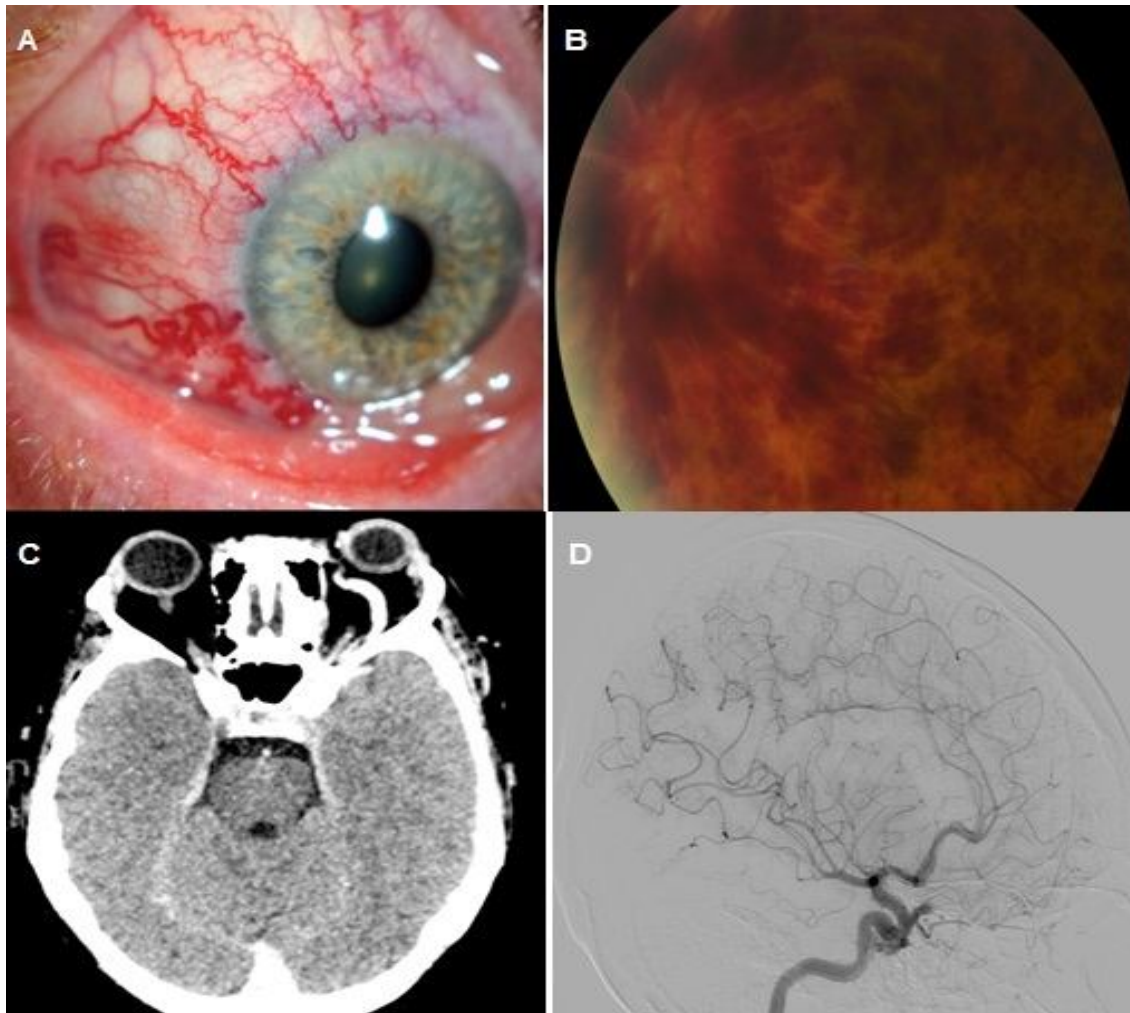


Figure 1: external ocular photography showing conjunctival injection with corkscrew vessels (a) fundus photography showing central retinal vein occlusion (b) axial CT-scan showing enhancement of the superior ophthalmic vein in the arterial phase of injection with an abnormally dilated and tortuous aspect (d) lateral view of catheter arteriography demonstrating rapid enhancement of the left cavernous sinus and left superior ophthalmic vein.

Consent

As per international standard or university standard, patient (s) written consent has been collected and preserved by the author(s).

Ethical Approval:

As per international standard or university standard written ethical approval has been collected and preserved by the author(s).

COMPETING INTERESTS: Authors have declared that no competing interests exist.

FUNDING: none.

References:

1. Gonzalez Castro LN, Colorado RA, Botelho AA, Freitag SK, Rabinov JD, Silverman SB. Carotid-Cavernous Fistula: A Rare but Treatable Cause of Rapidly Progressive Vision Loss. *Stroke*. 2016;47(8):e207-e209. doi:10.1161/STROKEAHA.116.013428
2. Chaudhry IA, Elkhamry SM, Al-Rashed W, Bosley TM. Carotid cavernous fistula: ophthalmological implications. *Middle East Afr J Ophthalmol*. 2009;16(2):57-63. doi:10.4103/0974-9233.53862
3. Schmidt D, Schumacher M. Zentralvenenverschluss als Folge von spontanen arteriovenösen Fisteln der Arteria carotis zum Sinus cavernosus. [Central vein occlusion as a sequela of spontaneous arteriovenous fistula of the carotid artery to the cavernous sinus]. *Fortschr Ophthalmol*. 1991;88(6):683–686. (Ger).
4. Barke RM, Yoshizumi MO, Hepler RS, Krauss HR, Jabour BA. Spontaneous dural carotid-cavernous fistula with central retinal vein occlusion and iris neovascularization. *Ann Ophthalmol*. 1991 Jan;23(1):11–17.
5. Brunette I, Boghen D. Central retinal vein occlusion complicating spontaneous carotid-cavernous fistula. Case report. *Arch Ophthalmol*. 1987 Apr;105(4):464–465. doi: 10.1001/archophth.1987.01060040034017.
6. Farouk MM, Mostafa EM, Mounir A. Central retinal vein occlusion complicating spontaneous dural carotid-cavernous fistula after phacoemulsification. *GMS Ophthalmol Cases*. 2019;9:Doc28. Published 2019 Jul 16. doi:10.3205/oc000117