

## Case Study report on uniuocular “Christmas tree” cataract

### Abstract:

Christmas tree cataract is a rare age-related condition characterized by the presence of multicolored crystals in the substance of the lens [1-3]. It is a chemical mixture of denaturated proteins with high level of calcium and cystine [4,5]. This type of cataract may be associated with autosomal-dominant myotonic dystrophy.

**Key words:** Cataract, Christmas tree, polychromatic opacities, cystine, calcium

### Introduction:

Christmas tree cataract is called so because of the presence polychromatic opacities within the lens. It is an age-related condition due to crystallization denaturated proteins in presence of favorable biochemical microenvironment. Herein, we describe a case of unilateral Christmas tree cataract.

### Case report:

A 62-year old patient with no particular past medical history presented for a routine eye checkup. His best corrected visual acuity was 6/6 OU. Ophthalmologic examination with dilated pupil objectified needle-like multicolored crystals in the substance of the right crystalline lens (figure 1). The multicolored sparking needles were essentially green, blue and gold. We noted variation of colors with change of the angle of incidence of the lit-lamp beam. There was no anomaly in the posterior segment and the fellow eye examination was unremarkable. The patient had no systemic abnormality. We concluded to a case of uniuocular “Christmas tree” cataract. The patient was advised regular follow-up in view of his excellent visual acuity.

### Discussion

“Christmas tree cataract is an age-related media opacity resulting from degeneration of crystallin proteins induced by elevated calcium levels” [1]. “The resulted denatured proteins accumulate in the lumen of the reticular meshwork. It is believed that cystine is likely responsible for the formation of needles which have a refractive potential” [2]. According to the angle of incident light, those needles may show various crystal colours giving the fascination pattern of a Christmas tree in the eye. This rare but striking appearance is often not visually significant and is usually encountered in a routine examination. Surgical intervention is indicated when the cataract impairs vision. Autosomal-dominant myotonic dystrophy is the most important systemic association with Christmas tree cataracts [3].

### Conclusion:

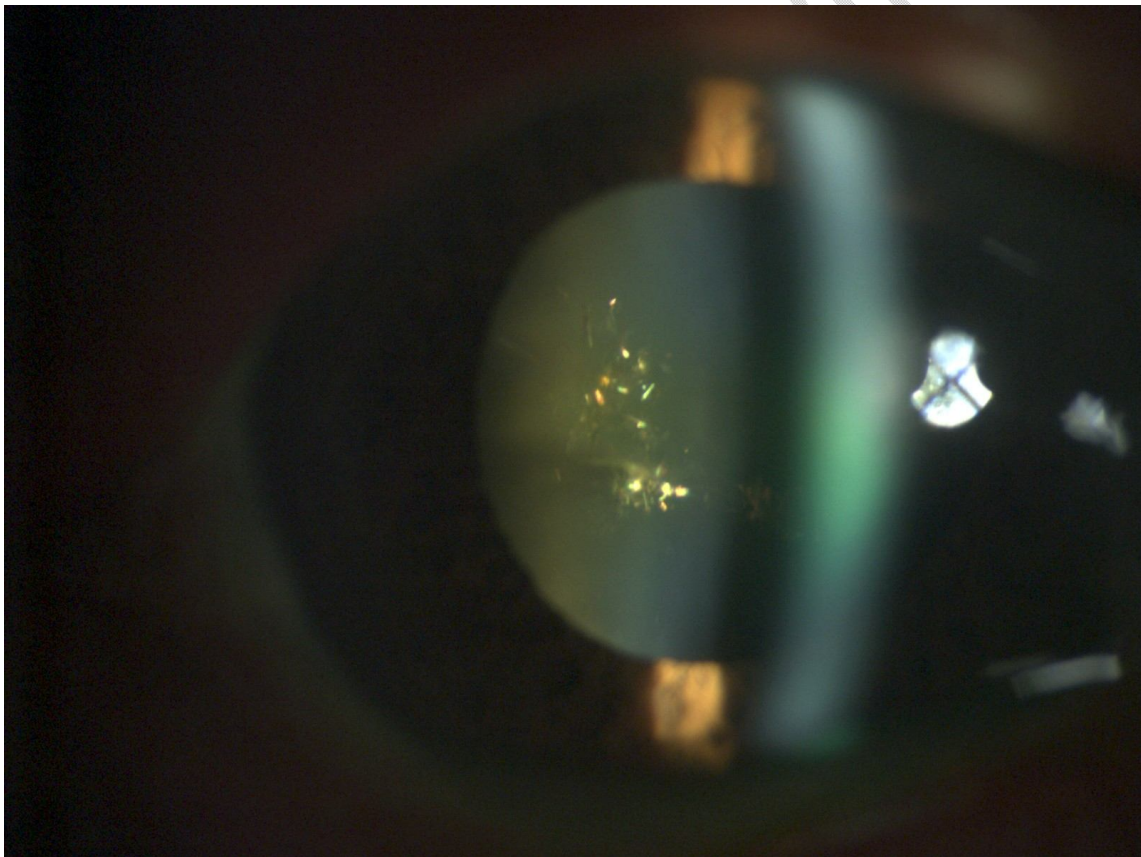
Christmas tree cataract is a rare age-related condition characterized by the presence of multicolored crystals within the lens because of favorable chemical microenvironment. This striking pattern should raise the possibility of an associated autosomal-dominant myotonic dystrophy.

#### **Consent**

As per international standard or university standard, patient(s) written consent has been collected and preserved by the author(s).

#### **Ethical Approval:**

As per international standard or university standard written ethical approval has been collected and preserved by the author(s).



**Figure 1:** Slit-lamp examination of a Christmas tree cataract showing polychromatic crystals within the substance of the crystalline lens.

**COMPETING INTERESTS:** Authors have declared that no competing interests exist.

**FUNDING:** none.

**References:**

1. Hayes BP, Fisher RF. Ultrastructural appearances of a lens with marked polychromatic lustre: evidence for diffraction as a cause. *Br J Ophthalmol* 1984;68:850–8.
2. Shun-Shin GA, Vrensen GF, Brown NP, Willekens B, Smeets MH, Bron AJ. Morphologic characteristics and chemical composition of Christmas tree cataract. *Invest Ophthalmol Vis Sci* 1993;34:3489–96.
3. Goel N. Christmas tree cataract. *Saudi J Ophthalmol*. 2016 Jul-Sep;30(3):210-211. doi: 10.1016/j.sjopt.2016.06.002. Epub 2016 Jun 25. PMID: 28210187; PMCID: PMC5299112.
4. Abihaidar N, Piteau H, Garcin T. Christmas tree cataract: Polychromatic crystals assessed by swept source-OCT. *Journal francais d'ophtalmologie*. 2023 Mar 6:S0181-5512.
5. Selvaraj R. Christmas tree pattern in age related cataracts. *Kerala Journal of Ophthalmology*. 2022 Sep 1;34(3):208-9.

UNDER PEER REVIEW