

*Original Research Article*

**Protective Effect of Methanolic Extract of *Vernonia amygdalina* (Bitter-Leaf) on Alloxan-Induced Pancreatic Toxicity in Adult Wistar Rats**

**ABSTRACT**

The pancreas is a glandular organ endowed with two main functions; an exocrine function that assists digestion and an endocrine function that modulates blood glucose concentration. Pancreatic Beta-cells produce insulin to regulate/lower blood glucose concentration, driving them into cells to be utilized. Distortions of the architecture of pancreatic Beta-cells lead to function loss; thus, preservation/restoration of their cytoarchitecture would sustain their functions. *Vernonia amygdalina* is a vital plant acknowledged widely for its antioxidant and anti-diabetic effects; however, its impact on the pancreas has received little attention. This study is premeditated to examine the effects of the methanolic leaf extracts of *Vernonia amygdalina* (MLEVA) on the cytoarchitecture of the pancreas in Alloxan-induced pancreatic toxicity. Thirty (30) adult male Wistar rats were grouped into 6 (A-F) (n=5). Group A, the control group, received feed and water only. Group B received a single intraperitoneal injection of 150mg/kg of Alloxan. Groups C, D, and E received single intra-peritoneal injections of 150mg/kg of Alloxan and were then treated with 200, 300, and 400 mg/kg/day of the MLEVA, respectively. Group F received a single intraperitoneal injection of 150mg/kg of Alloxan and was orally treated with 100mg/kg/day of Vitamin E. The experiment lasted 16 days before sacrificing the animals via a median incision on the abdominal cavity, under ketamine (100mg/ml), as anaesthesia, 24 hours after their last treatment. The pancreas was carefully and rapidly processed for routine H & E staining. This study recorded a 28% mortality rate after Alloxan administration, leading to degenerative histo-pathological changes in the pancreas' endocrine and exocrine compartments. 300mg/kg of MLEVA demonstrated a marked regenerative effect on the pancreas. The MLEVA is a promising agent for managing Diabetes,

evidenced by its protective and therapeutic effect on Alloxan-induced pancreatic toxicity.

**Keywords:** *Vernonia amygdalina*, MLEVA, Pancreatic toxicity, Alloxan, Diabetes Mellitus

## INTRODUCTION

The pancreas is a glandular organ located retroperitoneally within the abdominal cavity.<sup>[1]</sup> It is a gland that is partly exocrine and partly endocrine. The exocrine part secretes enzymes that assist in the digestion of carbohydrates, proteins and fats. At the same time, the endocrine pancreas produces two major hormones in addition to Somatostatin directly into the portal circulation.<sup>[1][2]</sup> These hormones include; glucagon secreted by the alpha-cells and insulin secreted by the beta-cells. The exocrine pancreas has a compound tubuloalveolar appearance microscopically. However, the endocrine pancreas appears as numerous rounded collections of cells embedded within the endocrine part. They are known as islets of Langerhans or termed pancreatic islets.<sup>[1]</sup> Therefore the function of the pancreas can easily be evaluated by examining the activities of these pancreatic hormones. The major hormones produced by the endocrine pancreas function by regulating glucose.<sup>[2]</sup> Glucose is the main sugar found in blood, serving as the body's immediate energy source. Notwithstanding, regulating blood glucose levels is vital for the healthy living of any complex organism. The pancreas is a vital organ charged mainly with the responsibility of blood sugar regulation, amongst other functions. Glucagon promotes an increase in blood glucose concentration, while insulin counters this action by enhancing the uptake of glucose by cells to be utilized.<sup>[2][3]</sup> The pancreas, however, is prone to toxicities or degenerative diseases that can be life-threatening. Ailments such as pancreatic acinar atrophy, pancreatitis and Pancreatic autoimmune disease (which leads to Insulin-dependent diabetes mellitus) diminish the functionality of the pancreas and, if left untreated, can prove lethal.<sup>[2][3]</sup> The life-threatening effect of pancreatic pathologies is mostly characterized by the loss of blood glucose

concentration regulation, which can easily tip an individual into Diabetes Mellitus and its complications.

In Africa, ubiquitous herbal medications have been attributed curative elements to Diabetes Mellitus.

*Vernonia amygdalina*, a plant commonly seen across the west coast of Africa where it is cultivated and grows wild as a domestic browse plant, has been attributed such a curative element.<sup>[4]</sup> Nigeria commonly identifies it as a "bitter leaf" because the leaves and the stem have an astringent, bitter taste. In Nigeria, it is a major vegetable of the celebrated "bitter leaf soup". *Vernonia amygdalina* has a long history of use in folk medicine, particularly among the people of sub-Saharan Africa and Southern Nigeria. It has a high reputation for use in the traditional management of diabetes mellitus.<sup>[4][5][6]</sup> Scientific studies have also reported its antihyperglycemic action<sup>[7][8]</sup> and hypoglycemic action<sup>[9]</sup> in diabetic and non-diabetic rats, respectively. The methanolic leaf extract has been shown to possess anti-diabetic and antioxidant Potentials in Alloxan-Induced diabetes mellitus in Sprague-Dawley Rats.<sup>[10]</sup> However, despite the extensive usage of *Vernonia amygdalina* traditionally as well as experimentally as a remedy for diabetes mellitus, its therapeutic potential is still largely unexplored, predominantly when it comes to its effect on organ and tissue architecture. Therefore, this study aims to investigate the effects of the methanolic extract of bitter-leaf (*Vernonia amygdalina*) on the microstructure of the pancreas in Alloxan-induced pancreatic toxicity using rat models.

Alloxan is a toxic glucose analogue that preferentially accumulates in the pancreatic beta cells via the GLUT2 glucose transporter.<sup>[11][12]</sup> This initiates a series of cyclic redox reactions, generating reactive oxygen species and hydroxyl radicals that lead to the death of beta cells.<sup>[12]</sup> It is commonly used in the induction of experimental Diabetes, giving rise to the rat model of insulin-dependent diabetes mellitus.<sup>[13]</sup> It also causes an enormous reduction in glucose-induced insulin release by inhibiting the  $\beta$ -cells of the islets of Langerhans glucose sensor glucokinase, thus inducing hyperglycemia.<sup>[14][15][16]</sup> Alloxan dosages ranging from 35mg/kg to 90mg/kg have been used experimentally to induce a rat model of insulin-dependent diabetes mellitus.<sup>[11][17]</sup> However, increased doses of Alloxan lead marked beta-cell toxicities

and remarkable damage in the endocrine pancreas.<sup>[18][19]</sup> It also damages the exocrine pancreas.<sup>[20][21]</sup>

Although endocrine evaluation serves as a direct approach to the monitoring of pancreatic toxicity, the use of histology in rat models serves as a holistic tool.<sup>[22]</sup> Distortion of the cyto-architecture of pancreatic acini, duct system and surrounding endocrine cells is a marker of pancreatic toxicity, hence used in the demonstration of the study of *Vernonia amygdalina* effect on distorted pancreatic cyto-architecture.

## **MATERIALS AND METHODS**

### **Plant Materials**

Matured bitter leaves (*Vernonia amygdalina*) were acquired from a local farm in Enugu-South local government area, Enugu state. A taxonomist at the Faculty of Agricultural Science, Enugu State University of Science and Technology, identified and authenticated these leaves.

### **Processing of Plant Materials**

The fresh bitter leaves were washed and air-dried at room temperature for one week within the animal facility where the study took place. The dried leaves were macerated using a warren blender to a smooth, dry powder and were subjected to methanolic extraction. The methanolic extraction technique used was adopted from Oyedeji et al. (2013)<sup>[23]</sup> and Adefisayo et al., (2018)<sup>[24]</sup>, filtered with Whatman No.1 filter paper (150 mm). The extract was concentrated using a rotary evaporator at 40–50 °C under reduced pressure. 10g of the crude extract was diluted in 100ml of normal saline and stored in an airtight container afterwards. The extract was stored at –8°C until required for use.

### **Experimental animals**

Thirty adults male Wistar rats with average weights of 180-200g were procured from the animal house facility of the Department of Anatomy, University of Nigeria, Enugu campus. However, this study was carried out in the animal facility of the Enugu State

University of Science and Technology College of Medicine, Parklane, Enugu. The animals were kept in well-ventilated breeding rooms and in netted iron cages. Easy access to water and standard livestock pellets (Guinea Feed Nigeria Limited) was provided as food, and they were allowed to acclimatize for 2 weeks. The animals were maintained under standard laboratory conditions, and handling was done following international guidelines on the use of experimental animals.

### **Experimental design**

The rats were randomly divided into six (6) groups (A-F) of 5 rats each. Alloxan was administered intraperitoneal, while all extract administrations were done orally. The experiment lasted 16 days.

Group A served as the control group and received normal saline orally till the end of the experiment. Group B was the untreated positive control group and received only a single intraperitoneal administration of 150mg/kg/bwt of Alloxan. This dosage of Alloxan used was adopted from Cheekati et al. (2017).<sup>[19]</sup> Groups C, D and E received a single intraperitoneal administration of 150mg/kg of Alloxan, left for two days (48 hours) to confirm diabetic statuses and then treated with 200, 300 and 400 mg/kg/day of the methanolic extract of bitter-leaf (*Vernonia amygdalina*) respectively for 14 days. The extract dosage was adopted from Adefisayo et al., (2018).<sup>[24]</sup> Group F received a single intraperitoneal administration of 150mg/kg of Alloxan, left for two days (48 hours) to confirm the diabetic status and then treated with 100mg/kg/day of Vitamin E for 14 days.

### **Confirmation of diabetic status:**

All animals were deprived of both food and water for 12 hours. Under aseptic conditions, blood samples were collected on the first day from all groups via tail venipuncture, and their blood glucose was determined using a one-touch glucometer strip test. Blood glucose levels for all groups ranged from 97mg/dl to 115mg/dl. Group B-F was administered with a single intraperitoneal administration of 150mg/kg of Alloxan immediately after determining their blood glucose. After the induction,

their drinking water was replaced with an oral solution of 20% glucose for two days to avoid mortalities due to hypoglycemic shock.<sup>[25]</sup>

Blood samples were re-collected from group B-F via tail venipuncture after two days (48 hours), and their blood glucose was determined. Blood glucose levels for these groups after 48 hours ranged from 418mg/dl to 505mg/dl, confirming positive hyperglycemia and suggesting pancreatic toxicity. Previous studies by Akhtar et al. (2002)<sup>[26]</sup> and Díez et al. (2013)<sup>[27]</sup> have reported that animals exhibiting a significant elevation in blood glucose levels above 250 mg/dL should be considered diabetic.

### **Histological Study**

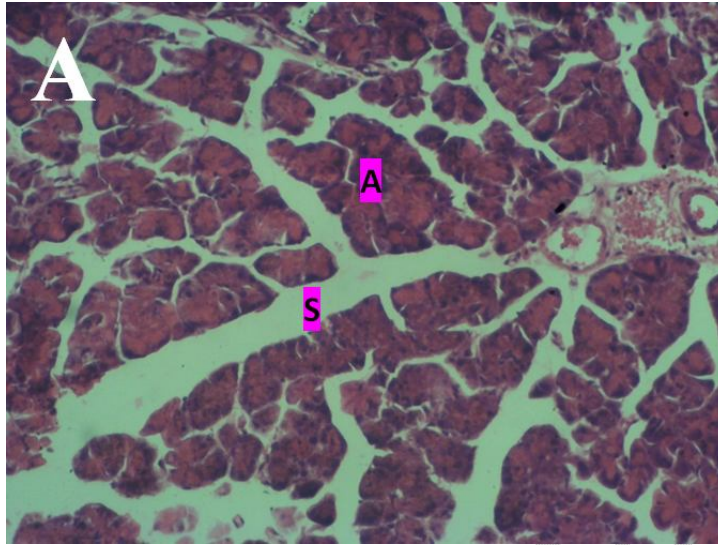
The animals were sacrificed 24 hours after the last administration via a median incision on the abdominal wall, under ketamine (100mg/ml), as anaesthesia. The pancreas was hurriedly isolated by dissection and immediately fixed with 10% formalin in labelled containers for 72 hours before processing. The fixed tissues were processed using the standard protocols for histological tissue processing and stained with hematoxylin and eosin for histological studies. Photomicrographs were taken using Amscope 14MP USB 3.0 digital microscope camera at x200 magnification.

## **RESULTS**

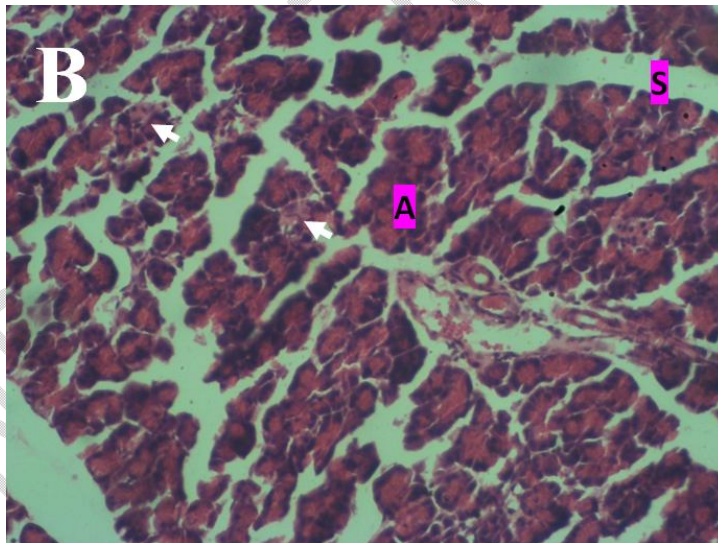
### **Animal mortality**

2 out of 5 animals died from Group B, the untreated positive control group. 1 out of 5 animals each died from Group C and E being treated with 200 mg/kg and 400 mg/kg of the methanolic extract of *Vernonia amygdalina*, respectively. 3 out of 5 animals died from Group F being treated with 100mg/kg of Vitamin E. Therefore, 7 out of 25 rats administered with Alloxan died before the experiment's end, giving rise to a 28% mortality rate.

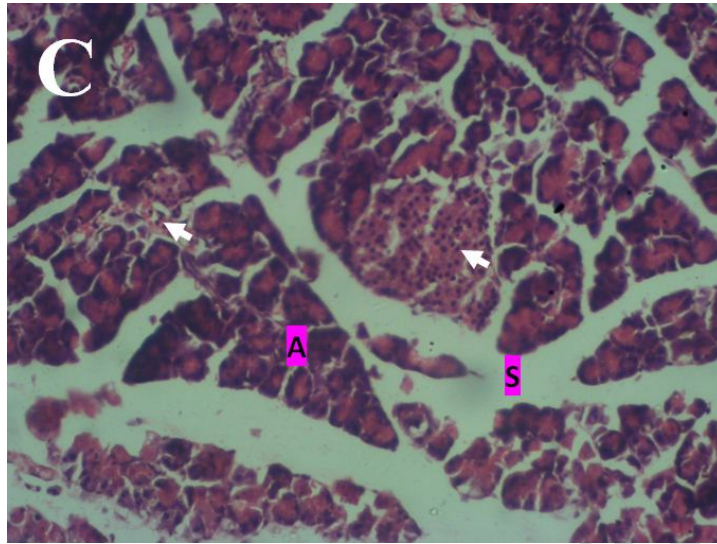
## Histological Analysis



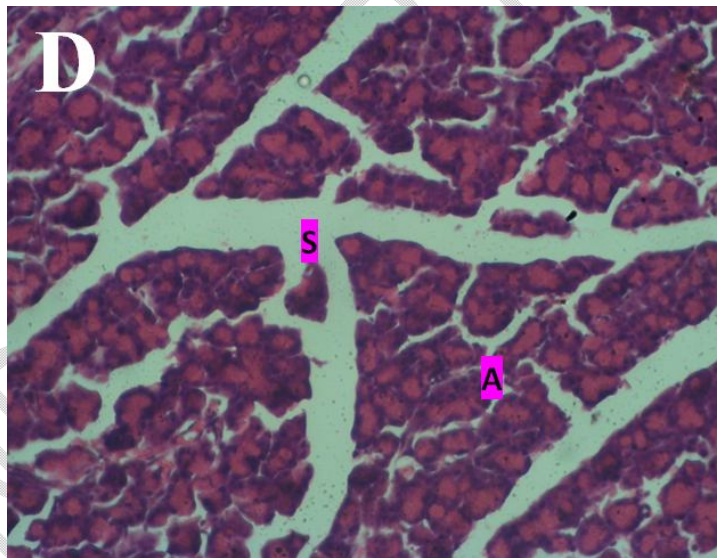
**Fig 1.**(Photomicrograph of a section of the pancreas of the control animal group **fed with only food and water** showing the normal acini tissue (a) with septa (s).General tissue appears normal. H&E.x200)Group A



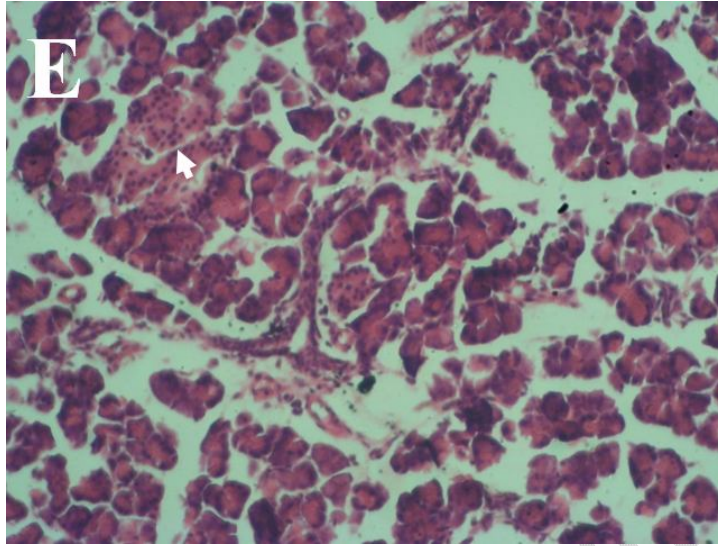
**Fig .2** (Photomicrograph of the pancreas of the **untreated** animal group administered only a single intraperitoneal administration of 150mg/kg/bwt of Alloxan, showing acini metaplasia, dilated blood vessels and marked shrinkage of the pancreatic islets (**arrow**) with leukocyte infiltration. H&E.x200)Group B



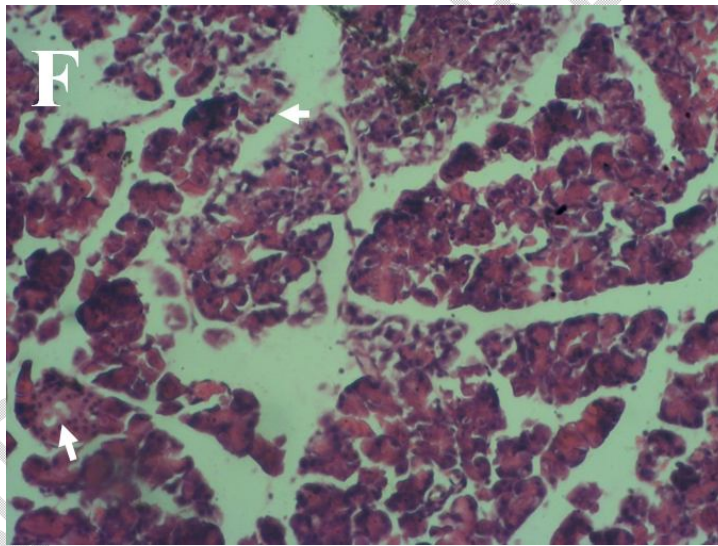
**Fig .3:** (Photomicrograph of the pancreas of the animal group treated with 200mg/kg of the methanolic extract of *Vernonia amygdalina* showing focal areas of mild acini aplasia and mild leukocyte infiltration in the pancreatic islets(arrow).Acini tissue (a), septa (s). H&E.x200)Group C



**Fig .4:** (Photomicrograph of the pancreas of the animal group treated with 300mg/kg of the methanolic extract of *Vernonia amygdalina* showing normal acini tissue (a) with septa (s). General tissue appears normal. H&E.x200)Group D



**Fig .5:**(Photomicrograph of the pancreas of the animal group treated with 400mg/kg of the methanolic extract of *Vernonia amygdalina* showing mild tissue derangement with necrotic and degenerative changes in the pancreatic islets. H&E.x200)Group E



**Fig.6:** (Photomicrograph of the pancreas of the animal group treated with 100mg/kg of vitamin E showing mild acini derangement with fibrosis and atrophy of pancreatic islets. H&E.x200)Group F

## DISCUSSION

Animal mortality has previously been reported as a complication of Alloxan injections. Previous studies have indicated that Alloxan administration leads to characteristic blood glucose responses, including severe, transitional hypoglycemia that may be fatal.<sup>[12]</sup> However, the data from previous studies are inconsistent, as some researchers reported mortality rates of up to 75% with an Alloxan dose of 80 mg/kg<sup>[28]</sup>. In comparison, others reported 100% survival rates with a 150 mg/kg dose.<sup>[29]</sup> Amid these inconsistent results, reported death rates differ substantially depending on the animal species, dose, chemicals used, and protocols employed.<sup>[25]</sup>

This study recorded a 28% mortality rate after Alloxan administration. This low value is suggested to be due to replacing their drinking water with an oral solution of 20% glucose for two days. Bacevic et al. (2020)<sup>[25]</sup> indicated that this practice helps avoid mortalities due to hypoglycemic shock after Alloxan induction.

A single intraperitoneal administration of 150mg/kg/bwt of Alloxan led to degenerative histopathological changes in the pancreas endocrine and exocrine compartments characterized by acini metaplasia and marked shrinkage of the pancreatic islets with leukocyte infiltration. This is per previous studies by Cheekati et al. (2017),<sup>[19]</sup> who reported that a single dose of 150 mg/kg of Alloxan intraperitoneally resulted in degenerative changes, followed by fibrosis and atrophy of islets and other pancreatic tissues. El-Esawy et al. (2016)<sup>[30]</sup> also demonstrated that intra-peritoneal injections of 150 mg/kg Alloxan led to both endocrine and exocrine pancreatic tissue damage characterized by degeneration and vacuolizations in islet cells, congestion and dilation of blood sinusoid, widening of the intercalated duct and the formation of fibres periphery to dilated blood vessels and ducts. The degenerative changes of Alloxan administration are attributed to the inhibition of insulin secretion from the pancreatic beta cells via beta cell toxicity<sup>[12]</sup> and possibly through the mechanism of induction of free radical species<sup>[13]</sup> and oxidative stress within the pancreatic tissue.

Previous studies have reported that vitamin E intake prevented Alloxan-induced pancreatic necrosis by preventing severe oxidative stress, strongly enhancing insulin secretion from the pancreas and improving hyperglycemia incidence.<sup>[31]</sup> However, this

study revealed that treatment with 100mg/kg of vitamin E still demonstrated mild degenerative changes in the endocrine and exocrine compartments of the pancreas characterized by mild acini derangement with fibrosis and atrophy of pancreatic islets. This finding suggests that Vitamin E might be more therapeutic as a preventive remedy as it displayed the therapeutic insufficiency of 100mg/kg of vitamin E in curing/regenerating the pancreatic cells after Alloxan-induced toxicity. Nevertheless, Malek et al. (2010)<sup>[32]</sup> classified vitamin E as a strong antioxidant, but its efficacy depends on the used dosage of vitamin E and the time length of administration.

Treatment with the *Vernonia amygdalina* (MLEVA) 's methanolic leaf extracts showed dose-dependent therapeutic potentials. The findings from this study suggest low-dose insufficiency and high-dose toxicity. 200mg/kg and 400mg/kg of MLEVA still demonstrated mild degenerative changes in the endocrine and exocrine compartments of the pancreas characterized by mild acini aplasia, mild tissue derangement and also necrotic pancreatic islets. However, 300mg/kg of MLEVA demonstrated a marked regenerative effect as the pancreatic tissues displayed normal cyto-architecture on both the endocrine and exocrine compartments of the pancreas. This study attributes this potential to the phytochemical constituents of the plant extract. Adefisayo et al. (2018)<sup>[24]</sup> reported a high amount of flavonoids and phenolic contents found in the methanolic leaf extract of *Vernonia amygdalina* after the quantitative phytochemical screening. These contents are responsible for its antidiabetic<sup>[7][33][34][35][36]</sup> and antioxidant potential<sup>[37][38][39]</sup> formerly described by previous studies.

## **CONCLUSION**

This study investigated the effects of the methanolic extract of bitterleaf (*Vernonia amygdalina*) on the microstructure of the pancreas in Alloxan-induced pancreatic toxicity using rat models. Low doses displayed insufficiency in producing the expected results, while high doses worsened Alloxan-induced toxicity. However, 300mg/kg of MLEVA demonstrated a marked regenerative effect on the cyto-architecture of the pancreas's endocrine and exocrine compartments. The MLEVA is a promising agent for the management of Alloxan-induced pancreatic toxicity. Nevertheless, caution should be applied while consuming this plant.

## **CONSENT**

It is not applicable

## **ETHICAL APPROVAL**

Ethical clearance was obtained from the Research and Ethical Clearance Committee, Faculty of Basic Medical Sciences, College of Medicine, Enugu State University of Science and Technology with ethical clearance code **ESUCOM/FBMS/ETR/2022/027**

## **REFERENCES**

1. Vasudeva, N. & Mishra, S. (2014). InderbirSingh's Textbook of Human Histology (Seventh edition): 298-302.
2. Marron P., Leslie R., Henri-Jean, G., Chaim, J., Manuel, R., Maria, T., Martinez, L., Wei-Ping, T., Yongsoo P., & Zhi-Xing Z. (1997). Insulin-dependent diabetes mellitus (IDDM) is associated with CTLA4 polymorphisms in multiple ethnic groups. *Human Molecular Genetics*; 6(8): 1275–1282.
3. Wiberg, E. (2004). Pancreatic acinar atrophy in German shepherd dogs and rough-coated Collies. Etiopathogenesis, diagnosis and treatment. A review, *Veterinary Quarterly*; 26(2): 61-75.
4. Farombi, O., & Owoeye, O. (2011). Antioxidant and chemoprotective properties of *Vernonia amygdalina* and Garciniabiflavonoid. *Int J Environ Res Public Health*; 8(6): 2533-2555
5. Ezuruike, U., Prieto, J. (2014). The use of plants in the traditional management of Diabetes in Nigeria: Pharmacological and toxicological considerations. *Journal of Ethnopharmacology*; 155: 857–924
6. Biser, A. (1998). Really wild remedies-medicinal plants used by animals. *Zooger*; 27(1): 80-84.

7. Akah, A., & Okafor, L. (1992). Blood sugar lowering effect of *Vernonia amygdalina* Del, in an experimental rabbit model. *Phytotherapy Research*; 6: 171–173.
8. Nimenbo-Uadia, R., (2003). Effect of *Vernonia amygdalina* in alloxan-induced diabetic albino rats. *Journal Med Lab Sci.*, 12(1): 25-31.
9. Gyang, S., Nyam, D., & Sokomba, E. (2005). Hypoglycemic activity of *Vernonia amygdalina* (Chloroform extract) in normoglycaemic and Alloxan-induced hyperglycemic rats. *Journal of Pharmacy and Bioresources*; 1(1): 61-66.
10. Fatmawaty, Y., Nina, H., Muhammad H., Vivitri, P. (2020). Antidiabetic and Antioxidant Potential of *Vernonia amygdalina* Leaf Extract in Alloxan-Induced Sprague-Dawley Rats. *OnLine Journal of Biological Sciences*; 20 (4): 190-200.
11. Sano, T., Kiyokazu, O., Tetsuro, M., & Isao, N. (2010). Giant Mitochondria in Pancreatic Acinar Cells of Alloxan-Induced Diabetic Rats. *Toxicologic Pathology*; 38: 658-665.
12. Lenzen, S. (2008). The mechanisms of Alloxan- and streptozotocin-induced Diabetes, *Diabetologia*; 51(2): 216–226.
13. Szkudelski, T. (2001). The Mechanism of Alloxan and Streptozotocin Action in B Cells of the Rat Pancreas. *Physiol Res*; 50(6): 536-46.
14. Heikkila, E., & Cabbat, S. (1978). Protection against Alloxan-induced Diabetes in mice by the hydroxyl radical scavenger dimethylurea. *Eur J Pharmacol*; 52: 57–60.
15. Fisher, J. (1985). Drugs and chemicals that produce Diabetes. *Trends Pharmacol Sci.*; 6:72-5.
16. Jorns, A., Tiedge, M., Lenzen, S., & Munday, R. (1999). Effect of superoxide dismutase, catalase, chelating agents, and free radical scavengers on the toxicity of Alloxan to isolated pancreatic islets in vitro. *Free Radic Biol Med*; 26, 1300–4.
17. Mir, S., Darzi, M. (2009). Histopathological abnormalities of prolonged Alloxan-induced diabetes mellitus in rabbits. *International Journal of Experimental Pathology*; 90: 66–73.

18. Scarpelli, G. (1989). Toxicology of the pancreas. *ToxicolApplPharmacol*; 101: 543–54.
19. Cheekati, R., Rao, S., & Vijayaraghavan, R. (2017). A histological study of Alloxan-induced Diabetes on experimental male Wistar rats. *Natl J Physiol Pharm Pharmacol*; 7(12):1329-1334.
20. Alvarez, C., & Lopez, A. (1989). Effect of Alloxan diabetes on exocrine pancreatic secretion in the anaesthetized rabbit. *Int J Pancreatol*; 5, 229–38.
21. Tiscornia, M., Janowitz, D., & Dreiling, A. (1968). The effect of Alloxan upon canine exocrine pancreatic secretion. *Am J Gastroenterol*; 49: 328–40.
22. Atangwho, I.E., Ebong, P.E., Egbung, E., & Obi, A.U. (2010). Extract of *Vernonia amygdalina* Del.(African Bitter Leaf) Can Reverse Pancreatic Cellular Lesion after Alloxan Damage in the Rat. *Australian J of Basic and Appl Sci*; 4(5): 711-716.
23. Oyedeji, O., Bolarinwa, F., & Akintola, M. (2013). Effect of methanol extract of *Vernonia amygdalina* on haematological and plasma biochemical parameters in male albino rats. *Int J Dent Med Sci*; 3(5): 64-67.
24. Adefisayo, M., Rufus, O., Akomolafe, S., Akinsomisoye, K., Alabi, L., Ogundipe, G., & Kehinde, P. (2018). Protective Effects of Methanolic Extract of *Vernonia amygdalina* (del.) Leaf on Aspirin-Induced Gastric Ulceration and Oxidative Mucosal Damage in a Rat Model of Gastric Injury. *Dose-Response: An International Journal*; 3: 1-11
25. Bacevic, M., Eric, R., Regis, R., Pierre, D., & France, L. (2020). Practical considerations for reducing mortality rates in Alloxan-induced diabetic rabbits. *Heliyon*; 6(e04103): 1-7.
26. Akhtar, S., Khan, A., & Malik, T. (2002). Hypoglycaemic activity of *Alpinia galangal* rhizome and its extracts in rabbits, *Fitoterapia*; 73(7–8): 623–628.
27. Díez, R., García, J., Díez, J., Sierra, M., Sahagún, M., & Calle, P. (2013). The hypoglycemic and hypolipidemic potential of a high fibrediet in healthy versus diabetic rabbits, *BioMed Res. Int*; 1–8.

28. Alam, S., Khan, H., Sirhindi, G., & Khan, S. (2005). Alloxan-induced Diabetes in rabbits. *Pakistan J. Pharmacol*; 22(2): 41–45.
29. O'Loughlin, A., Kulkarni, M., Vaughan, E., Creane, M., Liew, A., & Dockery, P. (2013). Autologous circulating angiogenic cells treated with osteopontin and delivered via a collagen scaffold enhance wound healing in the Alloxan-induced diabetic rabbit ear ulcer model. *Stem Cell Res. Ther*; 4(6): 158.
30. El-Esawy, H., Alghamdy, N., El-Askary, A., Elsayed, M. (2016). Histopathological Evaluation Of The Pancreas Following Administration Of Paricalcitol In Alloxan- Induced Diabetic Wistar Rats. *World Journal of Pharmacy and Pharmaceutical Sciences*; 5(3): 1-10
31. Takemoto, K., Wakana, D., Noriyoshi, M. (2016). Protective effect of vitamin E against Alloxan-induced mouse hyperglycemia. *Biochimica et BiophysicaActa*; 1862: 647–650.
32. Malek, M., Ali Noorafshan, H., Hamid, R., Mohammad, A., Monireh, M., Morteza, A., & Maryam, H. (2010). Effects of vitamin E on ovarian tissue of rats following treatment with p-nonylphenol: A stereological study. *Iranian Journal of Reproductive Medicine*; 8(1): 1-9.
33. Nwanjo, U. (2005). Efficacy of aqueous leaf extract of *Vernonia amygdalina* on plasma lipoprotein and oxidative status in diabetic rat models. *Niger J PhysiolSci*; 20(1-2):39-42.
34. Abraham, O. (2007). Effects of *Vernonia amygdalina* and chlorpropamide on blood glucose. *Med J Islamic World AcadSci*; 16: 115-119.
35. Ebong, E., Atangwho, J., Eyong, U., & Egbung, E. (2008). The anti-diabetic efficacy of combined extracts from two continental plants: *Vernonia amygdalina* (A. Juss) and *Vernonia amygdalina* (del.) (African bitter leaf). *Am J Biochemist Biotechnol.*; 4(3): 239-244.
36. Uchenna, O., Chinwe, O., John, O., & Ijeoma, E. (2008). Hypoglycemic indices of *Vernonia amygdalina* on postprandial blood glucose concentration of healthy humans. *Afr J Biotechnol*; 7: 4581-4585.

37. Erasto, P., Grierson, D., Afolayan, J. (2007). Antioxidant constituents in *Vernonia amygdalina* leaves. *Pharm Biol.*; 45(3): 195-199.
38. Oboh, G., Raddatz, H., & Helen, T. (2008). Antioxidant properties of polar and non-polar extracts of some tropical green leafy vegetables. *J Sci Food Agric*; 88(14): 2486-2492.
39. Fasakin, F., & Aluko, C. (2011). Antioxidant properties of chlorophyll enriched and chlorophyll depleted polyphenolic fractions from leaves of *Vernonia amygdalina* and *Gongronema latifolium*. *Food Res Int*; 44(8): 2435-2441.

UNDER PEER REVIEW