

Litter's Hernia in a child And review of the literature

Abstract

Litter's hernia is an extremely unusual clinical condition, defined by the presence of Meckel's diverticulum within a hernial sac. It is a true diverticulum containing all three layers of the gut. Herein, we are reporting rare and interesting a case of litter's hernia in a 3 yrs boy. Presented with a slowing growing right inguinal swelling, on clinical evaluation it was found to be an irreducible hernia. The diagnosis was made incidental after opening the hernial sac, tip of the Meckel's diverticulum was adherent to hernial sac. The boy was successfully managed by simple wedge resection of diverticulum and herniotomy.

Keywords

Littre's hernia, Meckel's diverticulum, Herniotomy.

Introduction

“A hernia containing Meckel's diverticulum is called a Litter's Hernia. It is a rare entity and diagnosis is often an incidental findings during routine hernia repair surgery – It's name is after French physician Alexis de Littre (1700)” [3,4].

“It is found at the antimesenteric border of the ileum, usually located 30-90 cm from the ileocecal valve, measuring 3 to 5 cm in length and 2 cm in diameter usual sites of litter's hernia are inguinal (50%), Umbilical (20%) and femoral (20%)” [6].

Review of the literature

1. PubMed & Cochrane bibliographical database were searched from the beginning of time to last search 1st August 2018 for studies reporting on Litter's hernia in adult population.

Results – forty five studies reported collectively on 53 patients. 25 males and 32 females presenting with a litters hernia. The most common site of occurrence in adults were femoral (39.6%) and inguinal 34%. The majority of cases 77.4% concerned incarcerated hernias.

2. The review of English literature of litter's hernia from the beginning of 20th century revealed 70 cases reported. The most common site is accepted as umbilical hernia for children's incidence of 85% even. Though the 50% of the litter's hernia is located in the inguinal region in the adult's litter's. Hernia is more common on **Right Side** inguinal hernias.

The presence of heterotopic mucosa of litter's hernia is a rare finding and 66.7% of the cases with heterotopic or ectopic mucosa the formation of adhesions in the hernia sac is due to inflammatory process related to the ectopic mucosa or congestion & exudation due to close loop obstruction with Meckel's diverticulum.

The literature review containing the presented case divulged 72 cases of litter's hernia from early 1900s to these days and by the help of these cases we aimed to discuss the features of litter's hernia in a child. 51 of these patients present in infancy period with male gender. Even though litters hernia can be seen at any age.

Case Presentation

A 3 years boy was brought to Jatal Hospital and Research Centre, Latur in 1997 with complaints of swelling in right inguinal region since 1 year. On clinical examination, an irreducible painless swelling in right Inguinal region. The abdomen was soft and on Ultrasonography revealed small bowel in the hernial sac. The baby was admitted for hernia surgery. Then surgery was planned and performed through right inguinal incision, inguinal canal was opened and Spermatic cord was identified along with hernial sac(Figure1).

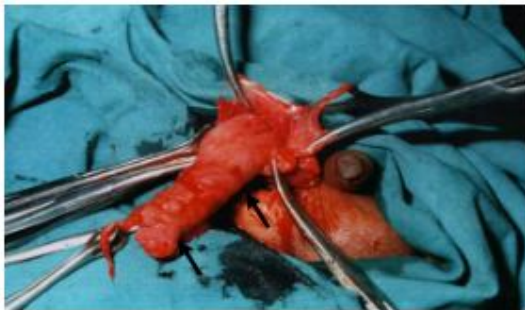

Figure 1 – Meckel's Diverticulam in a Right. Inguinal hernia (Litter's hernia)

Hernial sac was opened and to our surprise there was Meckel's Diverticulum along with loop of small bowel i.e ileum. The tip of the Meckel's Diverticulum was found adherent to the base of the hernial sac. Wedge resection of Meckel's diverticulum was done with Herniotomy (Figure 2,3).

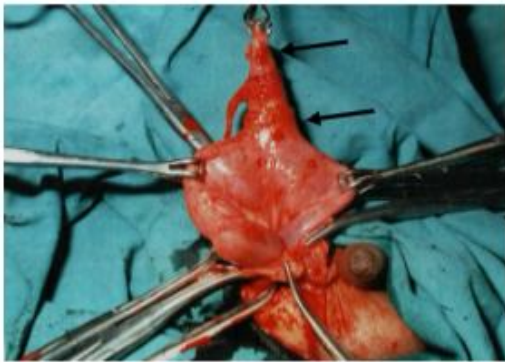


Figure 2 –Meckel's diverticulum attached to Right hernia sac

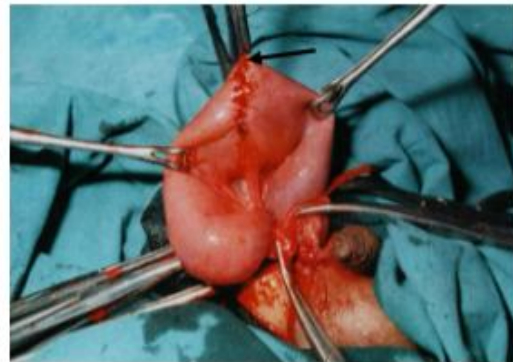

Figure 3 – Wedge resection with Meckel's diverticulectomy

Then the child was kept on intravenous fluids along with antibiotics. The surgically resected specimen was sent for histopathology laboratory & microscopic finding confirmed that it was Meckel's Diverticulum and no heterotopic tissue was found. Oral feeds were started 48 hrs. After the Surgery the child did well without any complications and was discharged home on the seventh post-operative day and on clinical follow up he is doing well since last 25 years.

Discussion

Litter's hernia is an extremely rare condition found in only 1 % of all cases of Meckel's diverticulum. The actual incidence reported to be only 0.09 % the "rule of 2" according to which Meckel's diverticulum . seen in 2 % population 2 inches in length 2 cm diameter. 2 feet proximal to the ileocecal junction, usually diagnosed under 2 yrs. of age. "It is 2 times more in males and symptomatic in 2% in patients. It is more common in right Inguinal hernia. Its mucosa may contains ectopic gastric tissue (in 23-50% cases) Pancreatic in (5-16% cases) and colonic tissue infrequently" [2]. "Most common clinical presentation in bleeding, obstruction, intussusception and inflammation (diverticulitis)" [4]. "Diagnosis confirmed on ultrasonography, CT scan and Technetium 99 m scan" [4]. "The most common

presentation being an incidental findings at laparotomy or hernia surgery. The most common complication of Meckel's diverticulum was intestinal obstruction (36.5%) followed by intussusception (30.7 %), Inflammation (12.7%) and hemorrhage (11.8%) and perforation (7.3 %)" [7].

Conclusion

Symptomatic cases of Meckel's diverticulum including Littre's hernia are treated surgically by open or laparoscopic technique. The simple wedge resection of the diverticulum is usually done with herniotomy or herniorrhaphy. A Littre hernia is a rare complication of Meckel's diverticulum. It required surgical attention and all medical professional should be encouraged to report such cases to expand our experience and optimize the therapeutic approach in such a rare entity so that newer surgical approaches and guidelines can be invented.

Consent

As per international standard or university standard, parental(s) written consent has been collected and preserved by the author(s).

Ethical Approval:

As per international standard or university standard written ethical approval has been collected and preserved by the author(s).

References-

- 1.Schizas D, Katsaros I, Tsapralis D, Moris D, Michalinos A, Tsilimigras DI, Frountzas M, Machairas N, Troupis T. Littre's hernia: a systematic review of the literature. *Hernia*. 2019 Feb; 23(1):125-130. doi: 10.1007/s10029-018-1867-0. Epub 2018 Dec 1. PMID: 30506463.
- 2.Usman A, Rashid MH, Ghaffar U, Farooque U, Shabbir A. Littre's Hernia: A Rare Intraoperative Finding. *Cureus*. 2020 Oct 20;12(10):e11065. doi: 10.7759/cureus.11065. PMID: 33224659; PMCID: PMC7676821.
3. Rattan KN, Bansal S, Arora I, Dhamija A, Tanwar M. Right Inguinal Obstructed Littre's Hernia in a Child. *J Nepal Paediatr Soc* 2016;36(3):300-302.
4. Littre's Hernia: A Unusual Tricky Situation of Meckel's Diverticulum ,Author=Ali Bendjaballah and Moustafa A. El Taieb and S. Ammari and R. Khiali, year=2019

5. Henry G. Mishalany, Robert Pereyra, Jerrold K. Longerbeam, Littre's Hernia in infancy presenting as undescended testicle, *Journal of Paediatric Surgery*, Volume 17, Issue 1, 1982, Pages 67-69, ISSN 0022-3468,
6. Skandalakis PN, Zoras O, Skandalakis JE, Mirilas P. Littre hernia: surgical anatomy, embryology, and technique of repair. *Am Surg*. 2006 Mar;72(3):238-43. PMID: 16553126
7. Arzu Pampal, Elif Demirci Aksakal 1 Littre hernia in childhood: A case report with a brief review of the literature DOI:10.4103/0189-6725.86068 PMID: 22005371
8. Narendra D. Kulkarni 1 Geet Adhikari 2 Gauri S. Jadhav Obstructed Inguinal Littre 's Hernia: A Vague DOI <https://doi.org/10.1055/s-0042-1755179>
9. Skandalakis PN, Zoras O, Skandalakis JE, Mirilas P. Littre hernia: surgical anatomy, embryology, and technique of repair. *Am Surg*. 2006 Mar;72(3):238-43. PMID: 16553126.
10. Citgez B, Yetkin G, Uludag M, Karakoc S, Akgun I, Ozsahin H. Littre's hernia, an incarcerated ventral incisional hernia containing a strangulated meckel diverticulum: report of a case. *Surg Today*. 2011 Apr;41(4):576-8. doi: 10.1007/s00595-010-4308-y. Epub 2011 Mar 23. PMID: 21431498.
11. Malling B, Karlsen AA, Hern J. Littre Hernia: A Rare Case of an Incarcerated Meckel's Diverticulum. *Ultrasound Int Open*. 2017 Apr;3(2):E91-E92. doi: 10.1055/s-0043-102179. Epub 2017 Jun 7. PMID: 28597002; PMCID: PMC5462611.
12. Sinha R. Bowel obstruction due to Littre hernia: CT diagnosis. *Abdom Imaging*. 2005 Nov-Dec;30(6):682-4. doi: 10.1007/s00261-005-0318-4. Epub 2005 Mar 30. PMID: 15803222.
13. Sengul I, Sengul D. Meckel's diverticulum in a strangulated umbilical hernia. *Afr J Paediatr Surg*. 2011 May-Aug;8(2):256-7. doi: 10.4103/0189-6725.86079. PMID: 2200538