

## Case study

# **Hydatid Cyst of the Lesser Sac: a case report and literature review**

Abstract:

**INTRODUCTION:** Hydatid disease is a parasitic disease that is endemic in many parts at the world. It is caused by Echinococcus infection, Hydatid cyst of the lesser sac usually follows infection else where in the abdomen.

**PRESENTATION OF CASE:** A 47 years-old female with a history of hepatic surgery for hydatid cyst, was admitted to our hospital for a chronic abdominal pain. Abdominal examination revealed a firm, epigastric mass. An enhanced computed tomography (CT) scan showed a multiloculated cystic mass within the lesser sac. The enzyme-linked immunoadsorbent assay (ELISA) test for echinococcal antigens was positive. She underwent surgical resection. The patient recovered well and was discharged four days after surgery. Long-term postoperative mebendazole was prescribed.

**DISCUSSION AND CONCLUSION :** Humans get infected by the ingestion of ova from the faeces of dogs and through the portal vein, it reaches the liver which represent the most common site of infection by the parasite followed by the lungs, kidneys, bone and brain. Hydatid cyst of the lesser sac usually follows infection elsewhere in the abdomen, Hydatid cyst of the lesser sac is a very rare presentation. Diagnosis of hydatid cyst can be achieved by clinical findings, serological tests and imaging methods. Treatment options consist of surgical management.

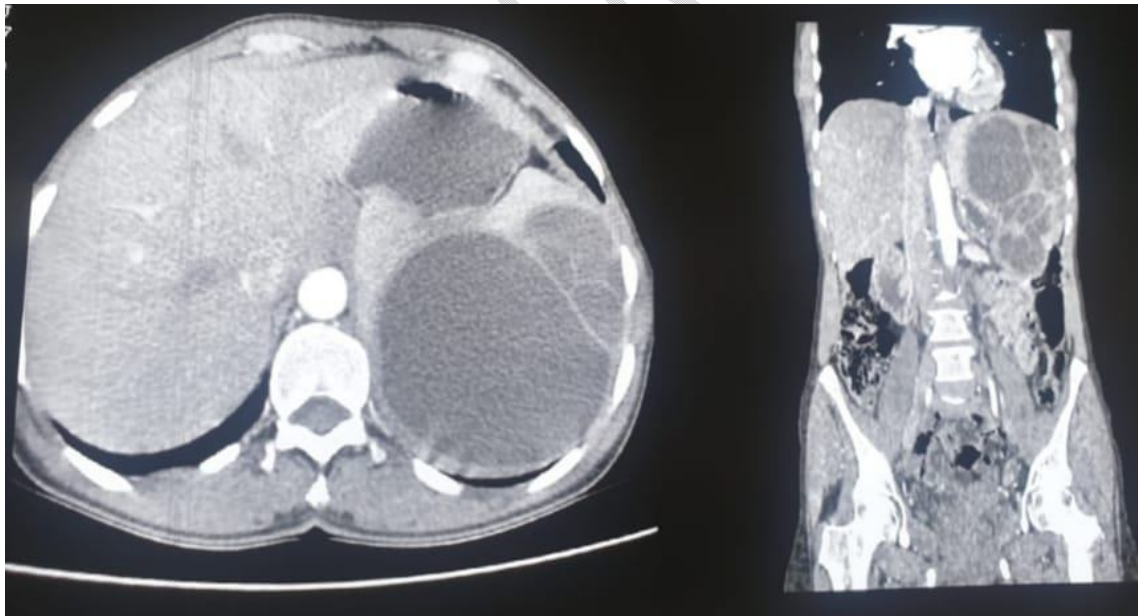
Key words: Hydatid, cyst, lesser sac

Introduction:

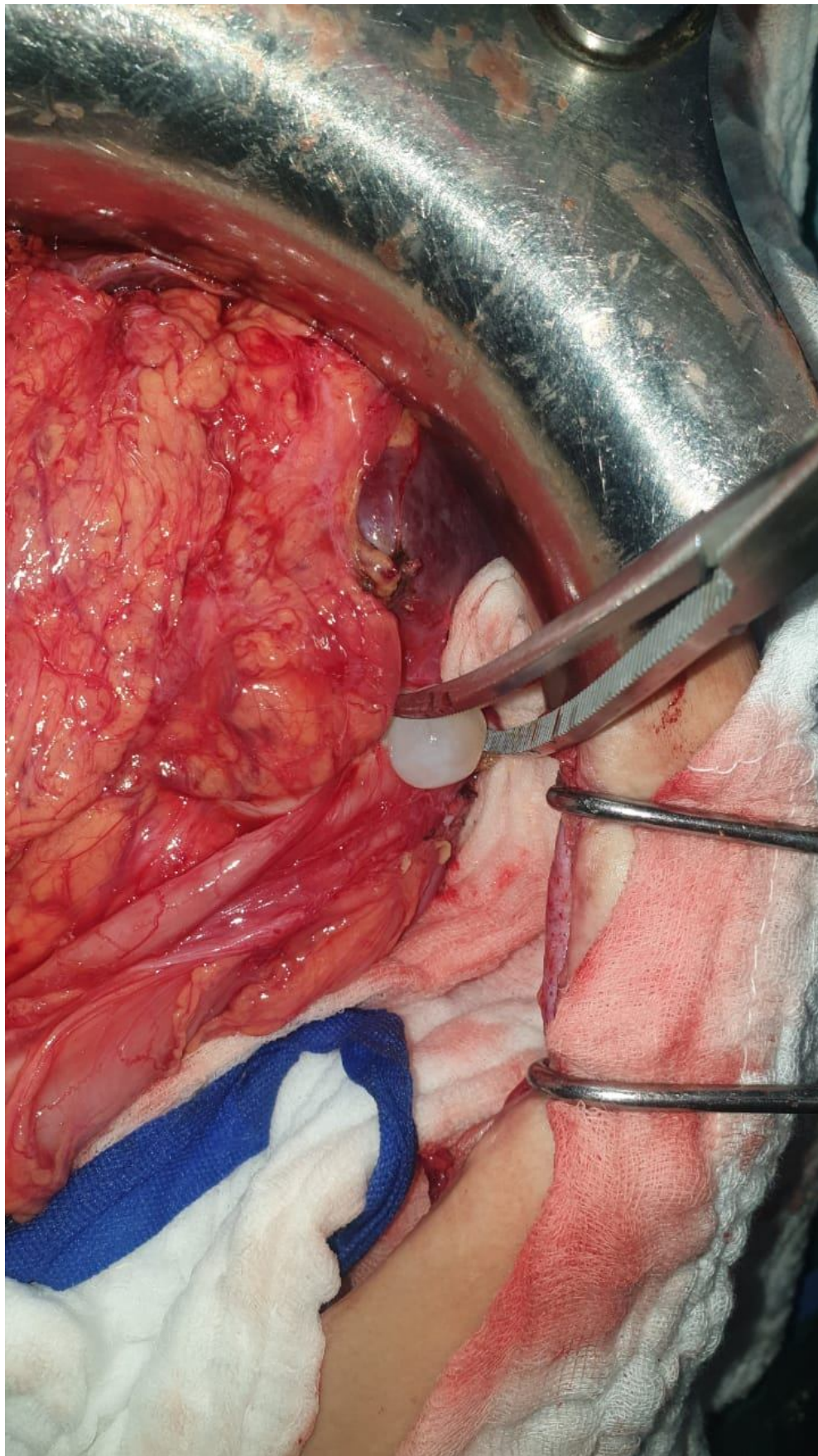
Hydatid disease is a parasitic disease that is endemic in many parts at the world. It is caused by Echinococcus infection. Peritoneal hydatid cysts are almost always secondary to hepatic involvement(1). The primary location at Extrahepatic Intra abdominal sites is a very rare disease, it is usually found concurrently with liver hydatid disease(2) . Hydatid cyst of the lesser sac usually follows infection elsewhere in the abdomen (3). This work has been reported in line with the SCARE criteria (4)

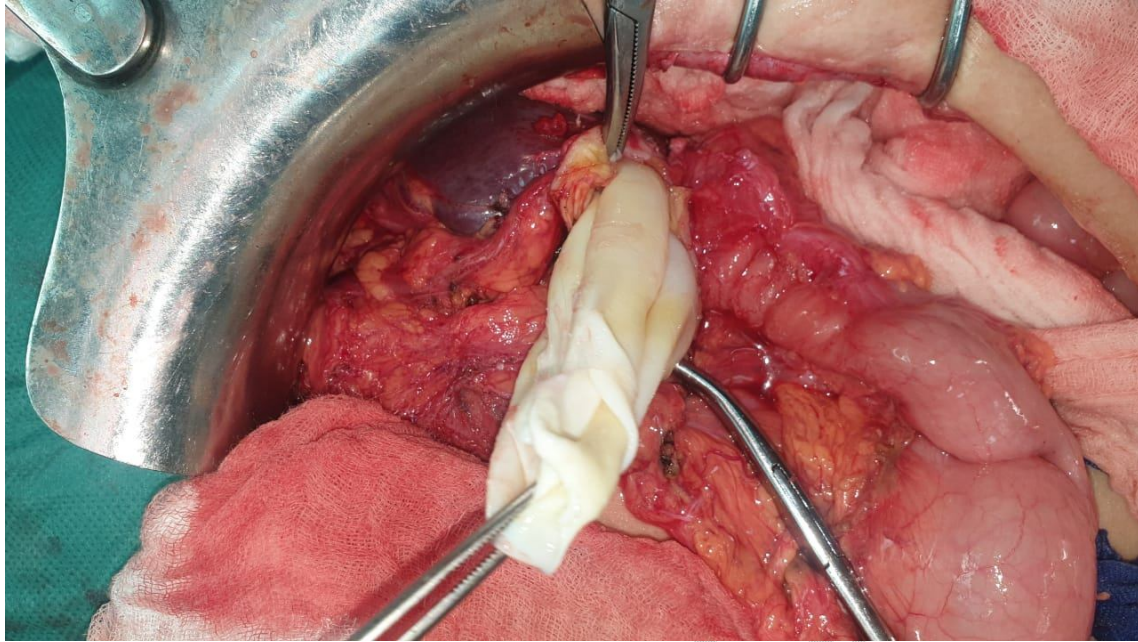
Case Presentation:

A 47-year-old female with a history of hepatic surgery for hydatid cyst 31 years previously, was admitted to our hospital for a chronic abdominal pain for about two years. Abdominal examination revealed a firm, epigastric mass that did not move with respiration. An enhanced computed tomography (CT) scan showed a multiloculated cystic mass within the lesser sac measuring 13 cm rounded well-defined with heterogeneous non-vascularized content, anterior displacement of the stomach was noted (Fig. 1). The enzyme-linked immunosorbent assay (ELISA) test for echinococcal antigens was positive. She underwent surgical resection under general anesthesia using laparotomy, The gastrosplenic ligament was divided which revealed a cystic lesion measuring about 13 cm. Incisions in the lesion allowed visualization of an encapsulated unilocular cystic space containing daughter cysts filled with gel-like fluid. The cavity was washed with saline solution (Fig. 2a) Surgical treatment consisted in a resection of the protruding dome and the cystic components were completely evacuated (Fig. 2b). The patient recovered well and was discharged four days after surgery. Long-term postoperative albendazole was prescribed. The patient was still well without imaging or clinical evidence of recurrent hydatid cysts 12 months after surgery.



**Figure 1.** Enhanced computed tomography (CT) scan of the abdomen revealing hydatid of the lesser sac





**Figure 2. (a, b)** Intraoperative photograph showing the proligere membrane being removed

## Discussion

*Echinococcus granulosus* is a hermaphrodite flat worm with three stages of development. The structure of the cyst is usually made of three components: the pericyst, made of the host's inflammatory tissue, the exocyst and the endocyst, where the scolecs and the proligere membrane are produced(5)

Hydatid cyst is endemic in sheep bearing areas of the world. It is caused by dog tapeworm (*Echinococcus granulosus*), dogs are the definitive hosts and humans are the intermediate hosts, humans get infected by the ingestion of ova from the faeces of dogs and through the portal vein, it reaches the liver which represent the most common site of infection by the parasite followed by the lungs, kidneys, bone and brain. Hydatid cyst of the lesser sac is a very rare presentation which usually follows infection elsewhere in the abdomen. (3)

Uncomplicated hydatid cysts may remain asymptomatic for years, depending on the size and the site of the developing cyst, the symptoms are often non specific, asymptomatic mass, epigastric pain, discomfort, nausea, vomiting and weight loss(2).

Ultrasound is diagnostic in most of the cases as it may reveal a rosette of daughter cysts, double-layer membrane and calcification of the cyst wall, The criteria for classification of liver cysts on ultrasonography, which were first developed by Gharbi in 1981, were improved by the World Health Organization (WHO) in 2001, CT scan and MRI often offer the possibility to better define anatomic relations(3,6).

Surgery is still the most used method worldwide, but it does not have 100% efficacy on hydatid cyst treatment yet. Surgery inactivates infectious materials, prevents contamination, and treats the residual cavities. Numerous traditional surgery methods have been described, such as marsupialization, external tube drainage, partial or total cystectomy, omentopexy, capitonage, and cystojejunostomies(7)

Radiological management offers many options. The basic procedure consists of percutaneous drainage of the cyst followed by instillation of scolicedal agent and/or alcohol. (3)

Medical pharmacotherapy is used in special cases where surgical or percutaneous treatment is not suitable or feasible or as an adjunct to surgical and percutaneous treatment(8)

Despite advances in surgical techniques and the use of chemotherapy, Recurrence remains one of the major problems in the management of Hydatid disease. There is no consensus on the type of follow-up Needed after primary interventions or on the management of diagnosed recurrences. Many factors have been suggested to lead to recurrence, the most important determinants for recurrence of hydatid cysts are spillage of the hydatid cyst, missing the cysts preoperatively or intraoperatively and incomplete pericystectomy.(9,10)

### **Conclusion:**

Diagnosis of hydatid cyst can be achieved by clinical findings, serological tests and imaging methods , Treatment options consist especially of surgical management,(3)

we report a case of a Hydatid Cyst of the Lesser Sac, in whom a resection of the protruding dome was performed.

CONSENT:

Written informed consent was obtained from the patient for publication of this case report and accompanying image

## References

1. Sattar A, Nahar N, Rahman MM, Anwar AT, Hossain A. Unusual presentation of a Hydatid cyst: a case report. *J Dhaka Med Coll.* 9 janv 2015;22(2):216-8.
2. Makni A, Jouini M, Kacem M, Safta ZB. Extra-hepatic intra-abdominal hydatid cyst: which characteristic, compared to the hepatic location? *Updates Surg.* mars 2013;65(1):25-33.
3. Fayyaz A, Ghani UF. Successful Treatment of Hydatid Cyst of Lesser Sac with PAIR Therapy. 2013;23:4.
4. Agha RA. The SCARE 2020 Guideline: Updating Consensus Surgical Case Report (SCARE) Guidelines. :24.
5. Botezatu C, "Colentina" Clinical Hospital, General Surgery Clinic, Bucharest, "Carol Davila" Medical University, Bucharest, Mastalier B, "Colentina" Clinical Hospital, General Surgery Clinic, Bucharest, "Carol Davila" Medical University, Bucharest, et al. Hepatic hydatid cyst – diagnose and treatment algorithm. *JMedLife.* sept 2018;11(3):203-9.
6. Salamone G. Uncommon localizations of hydatid cyst. Review of the literature. *GCHIR* [Internet]. 2016 [cité 1 mai 2021]; Disponible sur: <http://www.giornalechirurgia.it/common/php/portiere.php?ID=f1626958c3720a7294e8b36f02af0017>
7. Ozdil B, Kece C, Unalp OV. An Alternative Method for Percutaneous Treatment Of Hydatid Cysts: PAI Technique. *TurkiyeParazitIDerg.* 2 sept 2016;40(2):77-81.
8. Mihmanli M, Idiz UO, Kaya C, Demir U, Bostanci O, Omeroglu S, et al. Current status of diagnosis and treatment of hepatic echinococcosis. *WJH.* 2016;8(28):1169.
9. Prousalidis J, Kosmidis C, Anthimidis G, Kapoutzis K, Karamanlis E, Fachantidis E. Postoperative recurrence of cystic hydatidosis. *Can J Surg.* 1 févr 2012;55(1):15-20.

10. El Malki HO, Souadka A. POSTOPERATIVE RECURRENCE OF CYSTIC HYDATIDOSIS: WHAT ARE THE PREDICTIVE FACTORS? Can J Surg. 1 juin 2013;56(3):E44-E44.

UNDER PEER REVIEW