

Original Research Article

Quantitative measurements of macular and optic nerve head blood flow parameters following cataract surgery.

ABSTRACT

Objective: To evaluate the effect of uncomplicated cataract surgery on macular and optic nerve head blood flow with Optical Coherence Tomography Angiography (OCT-A). Retinal vascular changes and macular vessel remodeling following cataract surgery is an area of interest, as the effect, cause and duration of such changes remain debatable.

Setting: Eye Department, Red Cross Tertiary General Hospital, Athens, Greece

Methods: In this study, we recruited cataract surgery candidates who had regular post operative visits and underwent longitudinal OCT-A examinations before and after surgery.

Results: Macular vessel density increased in the post operative visits both in the superficial (SCP) and deep capillary network (DCP) ($P < 0.001$) and showed a persistent effect over 3 months follow-up. Macular thickness increased over the first postoperative month, but returned to preoperative values at 3 months. Foveal avascular zone (FAZ) measurements and vessel density at radial peripapillary capillaries (RPC) were unaffected.

Conclusions: OCT-A enables a quantitative analysis of blood flow by regular patient monitoring. In this study, we found that after cataract surgery, macular blood flow increased significantly. The reason for this could be attributed to post operative inflammatory process or vascular remodeling due to swift in retinal metabolic demands.

Keywords: Cataract, OCT angiography, Macula, Retinal vessels, Blood supply, Phacoemulsification, Optical coherence tomography, Vessel density

INTRODUCTION

Cataract is the leading cause of preventable blindness worldwide, with an estimated 20 million people living with bilateral cataract blindness in 2015 [1]. Cataract surgery, one of the most common procedures in medical practice, has over 95% success rate of restoring vision and improving quality of life. While cataract surgeries are generally safe, complications may occur, like increased intraocular pressure, inflammation, corneal endothelial loss and infections [2].

Optical Coherence Tomography Angiography (OCT-A) is a relative novel imaging technique used for the diagnosis and monitoring of retinal diseases. OCT-A is a non-invasive, non-contact imaging modality that uses optical acquisition and computation analysis to generate detailed 3-dimensional maps of the entire retinal vasculature. It enables clinicians to visualize the retinal vasculature from inner to outer retina. OCT-A has been proven to be more sensitive and specific than conventional methods such as fluorescein angiography, helping to improve accuracy of diagnosis and treatment of retinal diseases, avoiding the possible complications of intravenous injection of fluorescein [3,4].

Dynamics of retinal blood flow after a successful cataract surgery are not completely understood. Previous studies on ocular hemodynamics have attempted to evaluate vasculature after uneventful cataract extraction but results remain debatable [5,6]. A beneficial effect of improved blood flow was reported in a previous study, but the results depended on pulsative ocular blood flow which is mainly driven by the choroid [7]. Moreover, previous OCT-A studies have shown changes in retinal vasculature shortly after cataract surgery, but long-term effects have not been studied sufficiently [8,9].

In the presented work, we investigated the impact of uneventful cataract surgery on blood flow quantitative parameters of the macular region and the optic nerve head, as measured by OCT-A. All patients were followed up for 3 months after surgery.

MATERIALS & METHODS

Subjects and Selection Criteria

Forty – five (45) consecutive patients were diagnosed with cataract, were scheduled for phacoemulsification surgery with IOL implantation and were prospectively included in this study. The study followed the tenets of the Declaration of Helsinki and was approved by the local Ethics Committee. Informed consent was obtained from all participants. Patients with other retinal or optic nerve pathologies or dense cataracts preventing high-quality image acquisition were excluded from this study.

Diagnostic procedure and surgery

All patients underwent standard ophthalmological slit lamp examination, including refraction, IOP measurement (Goldmann applanation tonometry), fundoscopy and OCT-A imaging before surgery, after 1 week, after 1 month and after 3 months following surgery. Surgery was performed under topical anesthesia, using standard clear corneal phacoemulsification technique. All cases were completed uneventfully, without any intraoperative complications and the same IOL (...) was used in all cases, OCT-A imaging was obtained using the AngioVue OCTA system (RTVue XR Avanti with AngioVue, Optovue Inc, Fremont, California, USA). The system has an A-scan rate of 70,000 scans per second using a light source centered on 840 nm and a bandwidth of 45 nm. The split-spectrum amplitude-decorrelation angiography (SSADA) algorithm was used to extract the OCT-A information. Blood flow of a certain region is visualized by repeated OCT images which are evaluated for

changes. Blood flow in retinal vessels will result in changes between subsequent OCT images, while static tissues will show no change [10].

OCT-A imaging was performed using 6.0 x 6.0 mm HD scans while images of the optic nerve head were performed with 4.5 x 4.5 mm scans. The software automatically segments and analyzes macular tissue into 2 layers: superficial capillary plexus (SCP) and deep capillary plexus (DCP) and in optic nerve head measuring radial peripapillary capillaries (RPC). Macular thickness, foveal avascular zone (FAZ) area and perimeter were also automatically calculated by the internal machine software. Images were verified for accurate segmentation and borders were adjusted manually when needed by two expert graders. A cut-off point for accepted image quality was images above quality – 7 (Q7) as labeled by the internal OCT-A software. Images with motion artifacts were also excluded for further analysis.

Data Analysis and Statistics

Statistical analysis was performed using SPSS (IBM SPSS Statistics for Windows, Version 22.0; Armonk, NY, USA). Descriptive statistics are presented as mean \pm SD. The Shapiro–Wilk test used to examine normality of all parameters distributions. All p values relate to two-sided tests with a significance level of $p = 0.05$. Repeated measurements ANOVA with post hoc Tukey's test was used to assess statistical significance. Graphical displays were illustrated using GraphPad Prism (Graphpad Software Inc, San Diego, CA). Linear regression analysis with Pearson correlation coefficients (r values) was used to investigate the association between macular thickness and OCT-A parameters.

RESULTS

In total, 21 men with mean age of 81.93 ± 7.03 years and 24 women with age of 79.14 ± 6.35 years were examined and fulfilled the inclusion criteria. Measured OCT-A parameters are summarized in **Table 1**.

Table 1. OCTA vessel parameters of the study group. (SCP= superficial capillary plexus, DCP= deep capillary plexus, RPC= radial peripapillary capillary, FAZ= foveal avascular zone area, PERIM= perimeter of FAZ)

	N (%) or Mean (SD)				
	Pre-operative	1 week after surgery	1 month after surgery	3 months after surgery	p value
SCP (%)	37.43 ± 3.66	40.65 ± 4.21	42.65 ± 4.3	42.8 ± 4.94	<0.01
DCP (%)	45.39 ± 3.65	49.49 ± 3.39	49.86 ± 3.66	46.42 ± 3.85	<0.01
RPC (%)	44.01 ± 6.42	41.66 ± 5.74	45.24 ± 6.8	43.05 ± 6.02	0.07
FAZ (mm ²)	0.31 ± 0.12	0.21 ± 0.11	0.28 ± 0.09	0.3 ± 0.08	0.17
PERIM (mm)	2.31 ± 0.41	2.33 ± 0.29	2.08 ± 0.25	2.19 ± 0.33	0.29
Macular Thickness	302.5 ± 9.3	311.2 ± 8.8	323.7 ± 12.2	309.7 ± 8.2	0.04

*repeated measures ANOVA

Both SCP and DCP flow density displayed increased values by the first post-operative week. The effect remained significantly increased, compared to pre-operative measurements, for the 1 month and 3 months time points ($P < 0.01$). It is noted that both parameters reached top values 1 month after surgery and then appeared reduced but yet remained significantly increased compared to the pre-operative measurements. These results are also shown in **Fig. 1** and an example is shown on **Fig. 2**.

For RPC flow, there was not any significant difference during the 3 months follow-up period ($P = 0.07$). Similarly, no significant impairment was noted in the FAZ area and FAZ perimeter measurements ($P = 0.17$ and $P = 0.29$ respectively).

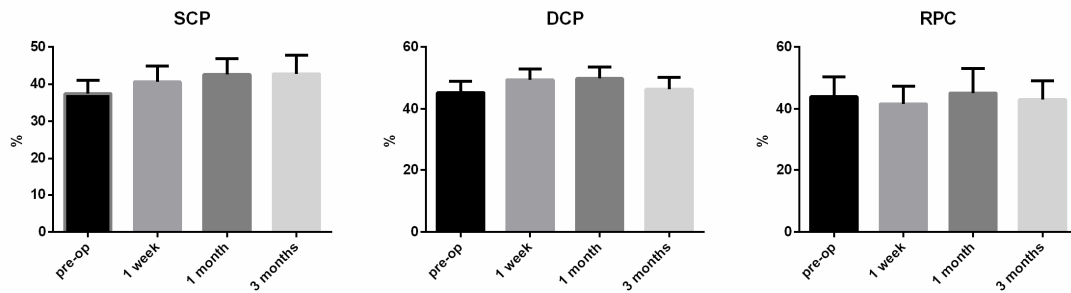


Fig.1 Box-plots showing the increased values of SCP and DCP after surgery which persisted at the 3 month follow-up visit. RPC flow remained rather unaffected.

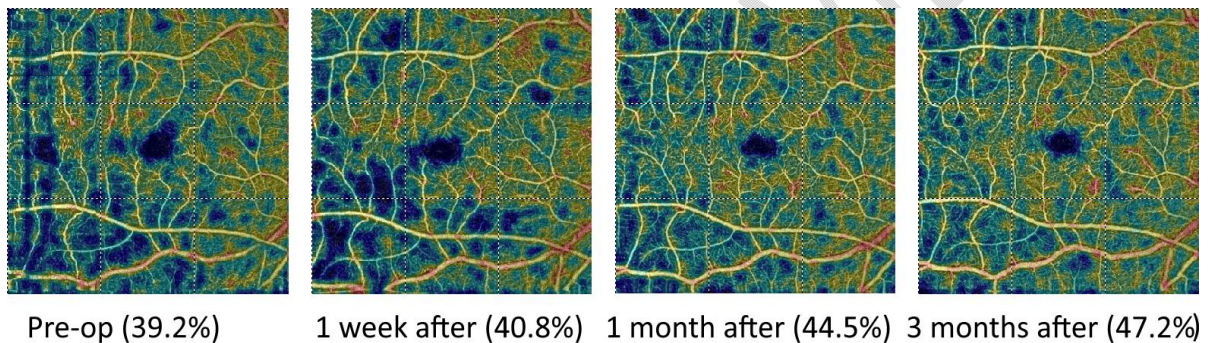


Fig.2 Example of a patient showing upregulation of retinal flow (SCP) during a 3 month period following cataract surgery.

Macular thickness significant increase was noted in the first week and the first month after surgery ($P=0.01$ and $P=0.04$ respectively), but values returned to preoperative measurements at the 3 months time point.

No significant correlation was noted between macular thickness and SCP or DCP flow at any time point. Similarly retinal vasculature parameters correlated with neither patient age, sex or IOP measurements.

DISCUSSION

OCT-A enables the quantitative analysis of retinal and optic nerve head blood flow and it is a proved a reliable tool that allows repeatable results [11,12]. It has important implications in understanding normal retinal vasculature and disease pathology such as diabetic retinopathy [13] and open-angle glaucoma [14]. Nevertheless, alterations in retinal blood flow after cataract surgery have only been studied recently in few studies with relatively short follow up in a limited number of eyes. [8, 9, 16-19, 28].

In this work, we found that vessel density in the superficial and deep capillary layers increased, following cataract surgery. The measurements peaked 1 month after surgery and while the values decreased afterward, remained significantly increased compared to pre-operative measurements, up to 3 months following phacoemulcification. Interestingly, macular thickness although followed a similar trend with raised values up to 1 month after surgery, values returned to normal at 3 months after surgery.

A number of studies, fairly recently have investigated the effects of uncomplicated cataract surgery on retinal and choroidal vasculature and macular tissue thickness. Mean subfoveal choroidal thickness was found to increase after cataract surgery, but these changes return to near the baseline after 3 months [15]. Pilotto *et al.* [16] evaluated by means of OCT and OCT-A, retinal, choroidal and macular perfusion changes induced in uncomplicated cataract surgery in only nine eyes. Inner and intermediate retinal volumes and capillary plexuses increased temporarily, returning to baseline levels by the third postoperative month. In a recent study [18] with 50 eyes and 3 months follow up, it was found that central macular thickness and vessel density of the macula significantly increase and persist after uncomplicated cataract surgery, while the FAZ area reduces. In accordance to this and to our study's findings, Haddad *et al* [19] in a prospective study including 18 eyes

undergoing routine phacoemulsification [19] demonstrated a significant increase in flow index (FI) in the superficial and deep retinal plexus following surgery, with the greatest changes occurring in the latter. No significant changes were noted in the outer retina or the choriocapillaris.

Macular thickness has been noted to reach its maximum 1 month after surgery and gradually returning to baseline [20,21]. Similar results with persistence of increased macular vessel density and thickness one to three months following cataract surgery, were observed in previous studies [8, 9, 25]. The study with the longest 12 months follow up so far, is the one by Gawęcki M *et al* [25] with postoperative evaluation with OCT-A of 17 eyes with uncomplicated cataract surgery. The authors revealed an increase in retinal thickness and volume in the first few months after the surgery, which was followed by a spontaneous decline in these parameters in the subsequent 12 months postop. A long-standing improvement was noted only in the vessel perfusion full (VPF) parameter. Nevertheless, in a recent study it was shown that intraoperative parameters during phacoemulsification do not affect macular hemodynamics [26]. Furthermore, a study on myopic eyes revealed that superficial retinal perfusion in patients with high myopia was significantly lower than that in low myopia patients, which may lead to complications caused by poor perfusion.

Therefore, in agreement with our findings, most of the previous studies have shown that there is a postoperative increase of retinal capillary plexus lasting for at least 3 months [8,9,18,19], with one study [25] demonstrating preservation of the changes for up to 1 year, while another study [16] showed very limited, less than 3 months, effect.

Regarding macular thickness postoperatively, in agreement with our study, previous research [8,9,16,18,20,21] has shown that macular thickness increases only for few weeks after cataract surgery, returning to baseline values by the third postoperative month.

Previous work of Cong et al. [24] summarized the possible mechanisms for increased macular thickness following cataract surgery, including presence of inflammatory mediators, direct and indirect tissue damage by surgical maneuvers and ultrasound energy, IOP fluctuations and increased light exposure. Expression of cytokines, interleukin 1-beta and chemokine ligand-2 from the neurosensory retina can also cause vascular dilation and impairment of blood-retinal barrier [22,23]. This inflammatory reaction induced by cataract surgery [16,18] and cytokine burden might be responsible for the increased blood flow reported after surgery. In our study, the increased vessel density persisted over a period of at least 3 months. A previous OCT-A study has shown perfusion alterations in macula after phacoemulsification due to functional hyperaemia. The effect was presumed to be evoked by increased light intensity stimulation of retina after cataract removal [27]. Other investigators have suggested that increased vascular parameters displayed by OCT-A might be a result of different refractive media following surgery. Lens opacities have a significant influence on retinal blood flow measurements in SS-OCTA and should be considered in quantitative vessel analysis. Inflammation may also impact the assessment of density parameters and FAZ measurements seems to be the most robust parameters in terms of media opacity. [28]. Furthermore, images taken from patient with cataracts, especially dense cataract, are more prone to various artifacts, including image dropouts, incomplete angiograms and image noise [29]. To address this issue we excluded patients with advanced cataracts that could compromise image quality. We ensured all enrolled patients had image quality of at least Q7, as indicated by the OCT-A device.

It is generally accepted, that cataract surgery can have a modest effect on IOP reduction in selected patients, although results are not always significant [30,31]. In this study, we did not find significant association between IOP values and vascular parameters at

any time point. It is also known that, capillary filling is due to autoregulatory mechanisms to maintain a constant blood flow and temporal IOP fluctuations are not expected to cause long term vascular impairments [32].

Cataract blocks up to 40% of incoming light at different wavelengths [33]. Increased stimuli will lead to increase in metabolism and neuronal activity which will lower O₂ and glucose levels and drive the production of vasodilative metabolites [34]. Vasoactive products of neuronal activity along with adenosine, lactate and arachidonic acid are produced due to the increase of ganglion cell activity to restore O₂ and glucose levels [35]. These complex metabolic regulations could also explain, to some extent, the increased flow values, measured in this study, following cataract surgery.

In this study, FAZ area and perimeter measurements remained unaffected after the procedure. Therefore it cannot be implied that severe structural alterations or macular ischemia were induced after surgery that could affect vascular density parameters.

Our study is not without limitations. First, despite the exclusion of advanced cataracts, image quality could be improved after cataract surgery which might artificially influence flow density parameters. We have to note here though, that RPC values remain unaffected after cataract removal. Moreover, although visual acuity improved in all patients after cataract removal, it is not known how vascular flow parameters could have a functional impact on these patients. Further longitudinal studies including functional tests such as contrast sensitivity, color and motion perception are needed to investigate the potential functional outcome of this vascular upregulation.

In conclusion, this study indicated that macular vessel density in SCP and DCP increases following cataract surgery. The effect persists for at least 3 months after surgery, while it is unknown if values remain increased after that time. Given the quality control of

image acquisition, and that RCP values were unaffected, we believe that the reported results reflect meaningful anatomical changes in the macula rather than erroneous values due to artifacts. Post-operative inflammatory process and architectural remodeling due to different metabolic demands are the main points in an attempt to interpret these results. Further investigations over time, are required to verify these findings.

REFERENCES

1. Steinmetz JD, Bourne RRA, Briant PS, Flaxman SR, Taylor HRB, Jonas JB, et al. Causes of blindness and vision impairment in 2020 and trends over 30 years, and prevalence of avoidable blindness in relation to VISION 2020: the Right to Sight: an analysis for the Global Burden of Disease Study. *Lancet Glob Heal*. 2021;9(2):e144–60.
2. Chan E, Mahroo OAR, Spalton DJ. Complications of cataract surgery. *Clin Exp Optom*. 2010;93(6):379–89.
3. Spaide RF, Fujimoto JG, Waheed NK, Sadda SR, Staurengi G. Optical coherence tomography angiography. *Prog Retin Eye Res*. 2018;64:1–55.
4. de Carlo TE, Romano A, Waheed NK, Duker JS. A review of optical coherence tomography angiography (OCTA). *Int J Retin Vitro* [Internet]. 2015 Apr 15 [cited 2019 Aug 10];1(1):5. Available from: <http://www.ncbi.nlm.nih.gov/pubmed/27847598>
5. Spraul CW, Amann J, Lang GE, Lang GK. Effect of cataract extraction with intraocular lens implantation on ocular hemodynamics. *J Cataract Refract Surg*. 1996;22(8):1091–6.
6. Plange N, Rennings C, Herr A, Weber A, Roessler GF, Mazinani BE, et al. Ocular pulse amplitude before and after cataract surgery. *Curr Eye Res*. 2012;37(2):115–9.

7. Hilton EJR, Hosking SL, Gherghel D, Embleton S, Cunliffe IA. Beneficial effects of small-incision cataract surgery in patients demonstrating reduced ocular blood flow characteristics. *Eye*. 2005;19(6):670–5.
8. Zhou Y, Zhou M, Wang Y, Ben S, Gao M, Zhang S, et al. Short-term changes in retinal vasculature and layer thickness after phacoemulsification surgery. *Curr Eye Res*. 2020;45(1):31–7.
9. Zhao Z, Wen W, Jiang C, Lu Y. Changes in macular vasculature after uncomplicated phacoemulsification surgery: optical coherence tomography angiography study. *J Cataract Refract Surg*. 2018;44(4):453–8.
10. Jiaa Y, Bailey ST, Hwanga TS, McClintica SM, Gaoa SS, Pennesia ME, et al. Quantitative optical coherence tomography angiography of vascular abnormalities in the living human eye. *Proc Natl Acad Sci U S A*. 2015 May 5;112(18):E2395–402.
11. Shahlaee A, Samara WA, Hsu J, Say EAT, Khan MA, Sridhar J, et al. In vivo assessment of macular vascular density in healthy human eyes using optical coherence tomography angiography. *Am J Ophthalmol*. 2016;165:39–46.
12. Al-Sheikh M, Tepelus TC, Nazikyan T, Sadda SR. Repeatability of automated vessel density measurements using optical coherence tomography angiography. *Br J Ophthalmol*. 2017;101(4):449–52.
13. Agemy SA, Sripsema NK, Shah CM, Chui T, Garcia PM, Lee JG, et al. Retinal vascular perfusion density mapping using optical coherence tomography angiography in normals and diabetic retinopathy patients. *Retina*. 2015;35(11):2353–63.
14. Wang X, Jiang C, Ko T, Kong X, Yu X, Min W, et al. Correlation between optic disc perfusion and glaucomatous severity in patients with open-angle glaucoma: an

- optical coherence tomography angiography study. *Graefe's Arch Clin Exp Ophthalmol.* 2015;253:1557–64.
15. Ibrahim AM, Elgouhary SM, Nassar MK, El Batanony AH. Changes in Choroidal Thickness after Cataract Surgery. *Semin Ophthalmol.* 2018;33(5):664-670.
 16. Pilotto E, Leonardi F, Stefanon G, et al Early retinal and choroidal OCT and OCT angiography signs of inflammation after uncomplicated cataract surgery *British Journal of Ophthalmology* 2019;103:1001-1007.
 17. Li T, Guadie A, Feng L, Fan J, Jiang Z, Liu F. Influence of cataract surgery on macular vascular density in patients with myopia using optical coherence tomography angiography. *Exp Ther Med.* 2020 Dec;20(6):258.
 18. Nourinia R, Kiani A, Hassanpour K, Nikkhah H, Faramarzi A, Emamverdi M. Optical coherence tomography angiography parameters after cataract surgery. *Int Ophthalmol.* 2023 Mar 3. doi: 10.1007/s10792-023-02667-5. Epub ahead of print. PMID: 36867381.
 19. Haddad F, Mimouni M, Nemet A, Safuri S, Achiron A, Shapira Y, Mtanis K, Duvdevan-Strier N, Ben-Ner D, Zayit-Soudry S. Changes in chorioretinal flow index after cataract surgery: an optical coherence tomography angiography study. *Int Ophthalmol.* 2023 Jan;43(1):35-41. doi: 10.1007/s10792-022-02385-4. Epub 2022 Jul 10. PMID: 35810396.
 20. Gharbiya M, Cruciani F, Cuzzo G, Parisi F, Russo P, Abdolrahimzadeh S. Macular thickness changes evaluated with spectral domain optical coherence tomography after uncomplicated phacoemulsification. *Eye.* 2013;27(5):605–11.
 21. Falcão MS, Gonçalves NM, Freitas-Costa P, Beato JB, Rocha-Sousa A, Carneiro Â, et al.

- Choroidal and macular thickness changes induced by cataract surgery. *Clin Ophthalmol.* 2013;55–60.
22. Xu H, Chen M, Forrester J V, Lois N. Cataract surgery induces retinal pro-inflammatory gene expression and protein secretion. *Invest Ophthalmol Vis Sci.* 2011;52(1):249–55.
 23. Ambati J, Anand A, Fernandez S, Sakurai E, Lynn BC, Kuziel WA, et al. An animal model of age-related macular degeneration in senescent Ccl-2-or Ccr-2-deficient mice. *Nat Med.* 2003;9(11):1390–7.
 24. Cong W-X. Mechanism of the macular fovea thickness change after cataract surgery in diabetic patients. *Int Eye Sci.* 2017;888–90.
 25. Gawęcki M, Prączyńska N, Karska-Basta I. Long-Term Variations in Retinal Parameters after Uncomplicated Cataract Surgery. *J Clin Med.* 2022 Jun 15;11(12):3426.
 26. Jia X, Wei Y, Song H. Optical coherence tomography angiography evaluation of the effects of phacoemulsification cataract surgery on macular hemodynamics in Chinese normal eyes. *Int Ophthalmol.* 2021;41:4175–85.
 27. Križanović A, Bjeloš M, Bušić M, Elabjer BK, Rak B, Vukojević N. Macular perfusion analysed by optical coherence tomography angiography after uncomplicated phacoemulsification: benefits beyond restoring vision. *BMC Ophthalmol.* 2021 Feb 5;21(1):71.
 28. Yu S, Frueh BE, Steinmair D, Ebnetter A, Wolf S, Zinkernagel MS, et al. Cataract significantly influences quantitative measurements on swept-source optical coherence tomography angiography imaging. *PLoS One.* 2018;13(10):e0204501.
 29. Spaide RF, Fujimoto JG, Waheed NK. IMAGE ARTIFACTS IN OPTICAL COHERENCE

TOMOGRAPHY ANGIOGRAPHY. Retina [Internet]. 2015 Nov [cited 2019 Aug 10];35(11):2163–80. Available from:

<http://www.ncbi.nlm.nih.gov/pubmed/26428607>

30. Shrivastava A, Singh K. The effect of cataract extraction on intraocular pressure. *Curr Opin Ophthalmol*. 2010;21(2):118–22.
31. Melancia D, Pinto LA, Marques-Neves C. Cataract surgery and intraocular pressure. *Ophthalmic Res*. 2015;53(3):141–8.
32. Jiang X, Johnson E, Cepurna W, Lozano D, Men S, Wang RK, et al. The effect of age on the response of retinal capillary filling to changes in intraocular pressure measured by optical coherence tomography angiography. *Microvasc Res*. 2018;115:12–9.
33. Artigas JM, Felipe A, Navea A, Fandino A, Artigas C. Spectral transmission of the human crystalline lens in adult and elderly persons: color and total transmission of visible light. *Invest Ophthalmol Vis Sci*. 2012;53(7):4076–84.
34. Roy CS, Sherrington CS. On the regulation of the blood-supply of the brain. *J Physiol*. 1890;11(1–2):85.
35. Attwell D, Buchan AM, Charpak S, Lauritzen M, MacVicar BA, Newman EA. Glial and neuronal control of brain blood flow. *Nature*. 2010;468(7321):232–43.