

## **Case report**

# **Ectopic Third Molar in Maxillary Sinus: A Rare Case Report.**

---

### **ABSTRACT**

Ectopic tooth in the maxillary sinus is an uncommon occurrence. There are multiple etiologies of this condition, including developmental disruption, pathological process, iatrogenic, and in rare cases no recognized reason.

Ectopic teeth in the maxillary sinus are noticed by accident during routine radiological examinations.

A 38-year-old married female reported to the department of oral medicine and oral surgery at the University Dental Clinic of Monastir-Tunisia. She has been experiencing left-sided face pain and a chronic headache for two months.

Orthopantomography and computed tomography are used to identify the existence of an ectopic tooth within the left maxillary sinus.

The Modified Caldwell-Luc Technique was performed to remove the tooth.

The patient was remained free of the presenting symptoms three months later.

Although the existence of an ectopic tooth in the maxillary sinus is rarely, it should be evaluated and detected as soon as possible. An ectopic tooth in the maxillary sinus should be extracted since it might lead to cyst development if left untreated. The modified Caldwell-Luc method, which offers a direct view into the maxillary sinus, is the standard approach.

*Keywords: third tooth; intrasinusal; Modified Caldwell-Luc; ectopic; maxilla.*

### **1. INTRODUCTION**

Ectopic tooth eruption inside the dentate area of the jaws is common in clinical practice and extensively described in the literature. Nevertheless, ectopic eruptions into the nondentate area are uncommon and infrequently reported [1].

Although a panoramic radiograph is the standard diagnostic radiographic examination for this type of eruption, cone beam computed tomography (CBCT) is strongly recommended for further localization of the ectopic tooth and evaluation of the characteristics of any associated lesion prior to surgical procedure [2].

Developmental abnormalities such as cleft palate, trauma, rhinogenic or odontogenic infection, hereditary variables, and crowding or dentigerous cysts surrounding impacted teeth are suggested etiologies [3].

### **2. CASE REPORT**

A 38-year-old married female reported to the department of oral medicine and oral surgery at the University Dental Clinic of Monastir-Tunisia. She has been experiencing left-sided face pain for the two last months. She had a history of two courses of antibiotics recommended by her doctor, but she had no long-term relief. As a result, she was referred to our center for a better management.

On clinical examination, there was no intraoral or extraoral swelling, and there was a partial terminal edentulousness with the absence of the first, second and third left maxillary molars.

All teeth were firm, vital and free of decay in the left maxillary region.  
A panoramic radiograph showed that the left maxillary third tooth was erupting in the maxillary sinus (Fig1).

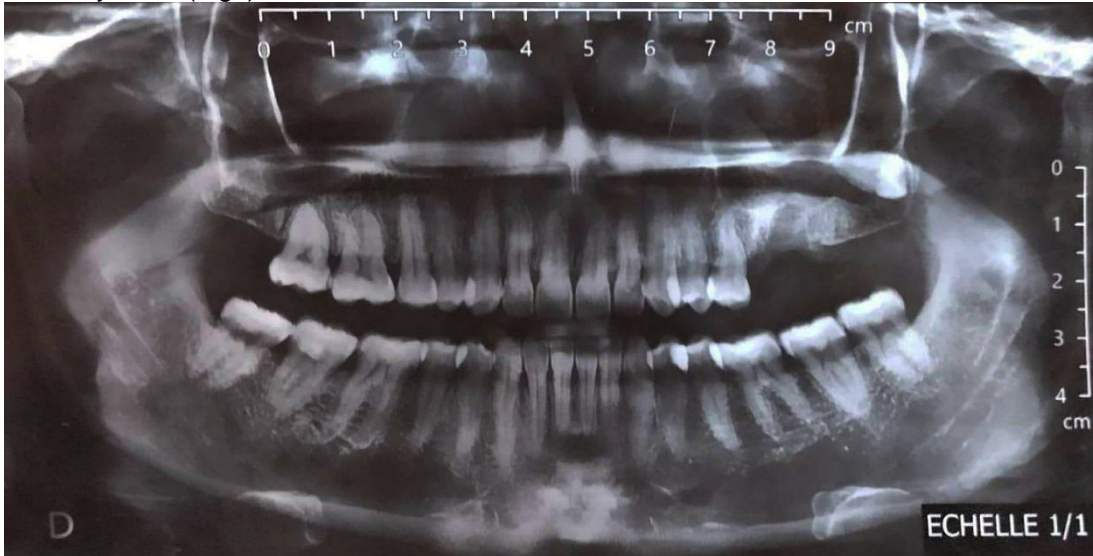

Fig1:Preoperative panoramic radiograph of an ectopic eruption of the left maxillary third molar into the left maxillary sinus.

A second radiographic scan, this time using cone beam computed tomography (CBCT), revealed the precise location of the third maxillary molar. CBCT showed the ectopic third molar located in the posteroinferior aspect of the sinus deported on the palatal side and in a horizontal position with a close approximation to the lateral wall of the sinus (Fig2a, fig2b).

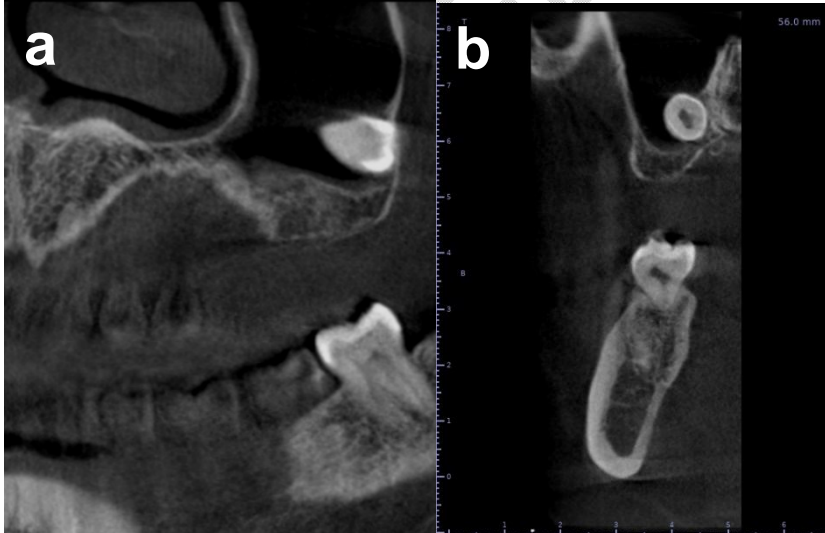


Fig2 :Multiplanar cone beam computed tomography (CBCT) sections: (a) coronal slices; (b) sagittal : showing the posteroinferior position of the ectopic left third maxillary molar inside the maxillary sinus.

The ectopic tooth morphology indicated a typical shape and size, as well as full root development. There were no radiological or clinical pathologies associated with the tooth. There were no signs of chronic sinusitis like mucosal thickening owing to the impacted tooth.

Based on the clinical and radiographic evaluation, the tooth was removed through the Modified Caldwell-Luc procedure.

A second-year resident in Oral surgery, oral medicine under the supervision of a university hospital professor at the Faculty of dental medicine of Monastir, Tunisia, utilizing a modified Caldwell-Luc approach, with a bony window created in the posterolateral wall of the maxillary sinus (Fig3a, Fig3b).

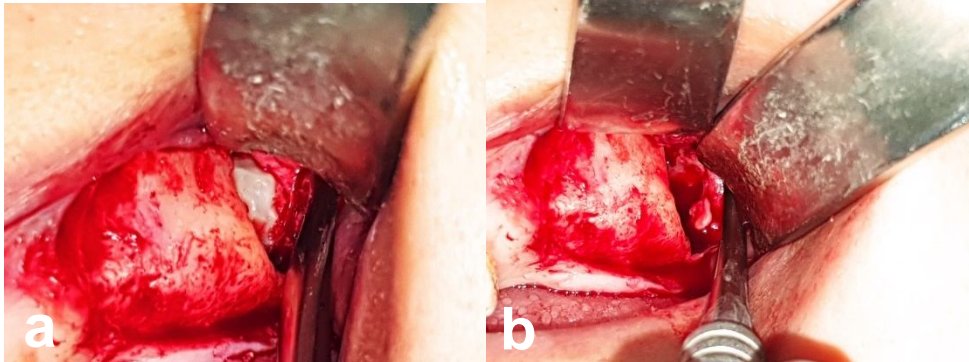


Fig3: Perioperative view of the bony window created in the sinus's anterior wall.

The surgery began with administration of local anesthesia including posterior superior alveolar dental nerve, infraorbital nerve, and greater palatine nerve block. Crestal incision was performed from the distal side of the second premolar to the tuberosity region followed by a mesial discharge incision and a mucoperiosteal flap was elevated

.Bone window was created by around bur with copious irrigation.

The ectopic tooth was found and extracted after a light milling around the tooth (Fig4).

The left maxillary sinus was extensively irrigated with normal saline. The mucoperiosteal flap was repositioned and sutured using 3-0 silk suture.

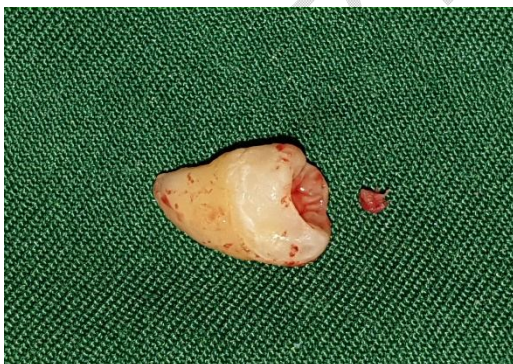

Fig4: Tooth after the operation..

The operation time was about 1 hour.

The patient was given postoperative antibiotics in the form of 1000 mg of amoxicillin 2 times daily for a minimum of seven days with an analgesic (500 mg of paracetamol every four hours per day), Nasonex spray 4 times daily, chlorhexidine mouthwash, as well as two doses of Dexamethasone 8 mg to prevent postoperative edema of the cheek, and she was instructed not to blow her nose for ten days. Also, the patient informed to have a soft diet and to sleep with a head in an elevated position.

Sutures removed 10 days after surgery, and the surgical site was completely healed without any complications.

Three months following the procedure, a panoramic radiograph and CBCT were taken. The patient was remained free of the presenting symptoms.

### 3. DISCUSSION

Tooth formation is the consequence of an interaction between the oral epithelium and the underlying mesenchymal tissue. The development of maxillary and mandibular dental lamina in the area of the future alveolar process begins in the sixth week of pregnancy. During the 5th and 10th months, the ectodermal derivative mostly undergoes proliferation to produce the permanent dentition, with each adult tooth comprised of a crown and a root. Ectopic tooth growth and eruption can originate from any aberrant tissue contact during odontogenesis [4].

Ectopic tooth eruption into dentate locations is very common, although such a situation in non-dentate sites such as the mandibular condyle, sigmoid notch, or nasal cavity is uncommon, and the exact etiology of this phenomena is unknown [5]. In our case, the cause remains unknown.

According to the most recent analysis of the literature, 51 patients were observed to have ectopic teeth in the maxillary sinus, with third molars having the highest frequency of ectopic teeth (21 cases) [4].

The ectopic eruption in the maxillary sinus can induce sinonasal symptoms, most commonly due to recurrent or chronic sinusitis, or it can cause ocular problems. A headache, face discomfort, edema, nasal blockage, nasal discharge, epiphora, rhinorrhea, hyposmia, and orbital proptosis are among the symptoms. On the other hand, some asymptomatic instances may be identified by chance without any symptoms [6].

The CBCT designed for implant dentistry, has proven to be useful in evaluation of jaw abnormality and pathology.

It allows you to see the maxilla and mandible in three planes: panoramic, axial, and cross-sectional.

Additionally, the closeness of the tooth to the sinus wall or its ankylosis may be identified and precisely estimated. If there is already a damaged cortical bone in the sinus wall, it should be taken into surgical consideration to minimize needless bone loss [6].

With a lower patient dosage than a CT scan, CBCT allows a three-dimensional examination of the maxillary sinus. As a result, it can be an effective replacement for detecting and treating ectopic tooth eruption in the maxillary sinus.

If an ectopic tooth in the maxillary sinus is not removed surgically, it will most likely develop into a cyst or tumor if left untreated [7].

There are presently two effective surgical treatments for EMTM: the Caldwell-Luc method and nasal endoscopy. Patients who are symptomatic or asymptomatic with an accompanying cyst are candidates for EMTM avulsion.

But, the standard Caldwell-Luc method was established for removing a foreign body from the maxillary sinus; the most common problems related with this procedure include facial edema, infraorbital paraesthesia, and loss of tooth vitality [8].

An inferior meatal antrostomy is done in the usual Caldwell-Luc technique to improve sinus drainage. Nevertheless, inferior meatal antrostomy has significant disadvantages, including increased operating time, the danger of nasolacrimal duct injury, and early closure of the orifice [9].

That's why, the modified Caldwell-Luc procedure without inferior meatal antrostomy was favored over the usual technique in this patient.

The modified Caldwell-Luc approach is used successfully in the retrieval of a displaced tooth from the maxillary sinus. It is associated with a minimum postoperative discomfort and less complications.

Alternative surgical techniques, including as endoscopic surgery, enucleation, and marsupialization, are employed less frequently for this problem. Regular follow-ups have been suggested in certain asymptomatic instances [10].

#### 4. CONCLUSION

A third molar eruption in the maxillary sinus is highly uncommon. CBCT is quite useful for visualizing and managing teeth in the maxillary sinus.

The etiology of ectopic eruption is still unclear and many theories have been suggested including trauma, infection, crowding, and developmental abnormalities.

The most common treatment for ectopic teeth in the maxillary sinus is surgical extraction. Close radiological follow-up is recommended if the tooth is not extracted.

#### CONSENT (WHEREEVER APPLICABLE)

As per international standard or university standard, patient written consent has been collected and preserved by the authors.

#### ETHICAL APPROVAL

As per international standard or university standard written ethical approval has been collected and preserved by the authors.

#### ABBREVIATIONS

**CBCT**: Cone beam computed tomography.

**EMTM** : Ectopic maxillary third molars.

#### REFERENCES

1. Ramanojam S, Halli R, Hebbale M, Bhardwaj S. Ectopic tooth sinus: in maxillary case series. *Ann. Maxillofac. Surg.* 2013;3(1):89–92.
2. Elmorsy K, Elsayed LK and El Khateeb SM. Case Report: Ectopic third molar in the maxillary sinus with infected dentigerous cyst assessed by cone beam CT. 2020; 9:209. Accessed 25 March 2020.  
Available : <https://f1000research.com/articles/9-209-v2>
3. Lombroni LG, Farronato G, Santamaria G, Lombroni DM, Gatti P, Capelli M. Ectopic teeth in the maxillary sinus: case report and literature review. *Indian Journal of Dental Research.* 2018;29(5):667.
4. Avery JK. *Oral Development and Histology.* 2nd ed. New York: Thieme Medical Publisher Inc. 1994:70-92.
5. Findik Y, Baykul T: Ectopic third molar in the mandibular sigmoid notch: Report of a case and literature review. *J Clin Exp Dent.* 2015;7(1):133–137.
6. Mitra K, Mahnaz S. Ectopic third molar in maxillary sinus: an asymptomatic accidental finding. *The Egyptian Journal of Otolaryngology* 2019, 35:219–221.
7. Sheikhi M, Samandari M, Karbasi Kheir M, Moaddabi A. Multiple dentigerous cysts with a complex odontoma: an unusual case report. *Avicenna J Dent Res.* 2016; 8(2):e26050.

8. Low WK. Complications of Caldwell-Luc and how to avoid them. *Aus NZJ Surg.* 1995;65:582–584.
9. Huang YC, Chen WH. Caldwell-Luc operation without inferior meatal antrostomy: a retrospective study of 50 cases. *J Oral Maxillofac Surg.* 2012;70:2080–2084.
10. Kaan Beriat G, Çelebi Beriat C, Yalçinkaya E. Ectopic molar tooth in the maxillary sinus: a case report. *Clin Dent Res.* 2011; 35:35–40.

UNDER PEER REVIEW